

First Trimester Prenatal Diagnosis of Beta-thalassaemia following Chorionic Villus Sampling

R. Chandran, MRCOG*

O. Ainoon, DCP**

I. Anson, DipMLT*

J. Anne, DipMLT**

S.K. Cheong, FRCPA**

* Department of Obstetrics and Gynaecology, Universiti Kebangsaan Malaysia, Jalan Raja Muda Abdul Aziz, 50300 Kuala Lumpur

** Department of Pathology, Universiti Kebangsaan Malaysia, Jalan Raja Muda Abdul Aziz, 50300 Kuala Lumpur

Summary

DNA analysis for the diagnosis of beta-thalassaemia is a relatively new technique in Malaysia. This, combined with chorionic villus sampling, has enabled us to offer prenatal diagnosis in the first trimester for this common condition. To the best of our knowledge, this has not hitherto been reported in Malaysia.

Key words: Prenatal diagnosis, beta-thalassaemia, chorionic villus sampling.

Introduction

Beta-thalassaemia is a common condition in this country, afflicting mainly the Chinese and Malays. Until recently, prenatal diagnosis of this condition was not available locally. We report here our preliminary experience of prenatal diagnosis of this condition in the first trimester following chorionic villus sampling (CVS).

Case Reports

Case 1

NYK was a 32 year old Chinese secundigravida who was referred at 10 weeks' gestation for prenatal diagnosis. Her first-born had beta-thalassaemia major and was transfusion dependent. Subsequent DNA analysis showed that both parents were heterozygous for the beta-thalassaemia mutation frameshift 41/42 (-TCTT).

An ultrasound scan using a Toshiba SSA-100A with a 3.75 mHz curvilinear transducer confirmed a viable intrauterine pregnancy corresponding to 10 weeks' gestation. The placental site was situated antero-laterally. After counselling, the parents consented to CVS. This was performed by one of us (RC) transabdominally under ultrasound guidance with a 20 gauge spinal needle using a free-hand technique. The needle tip was guided parallel to the chorionic plate and into the chorion frondosum. Villi were aspirated into heparinised buffered culture medium using a 10 ml syringe with a gentle to and fro movement of the sampling needle. An adequate sample was obtained at the first attempt. Anti-D immunoglobulin was not required as the patient was Rhesus positive. The parents were reassured and

CASE REPORT

shown the fetal heart activity after the procedure. The patient was advised to avoid strenuous activity for a week and she did not have any procedure-related complications such as pain, fever or vaginal bleeding.

DNA was obtained from the chorionic villus sample by the phenol-chloroform extraction method. DNA analysis was then carried out by the polymerase chain reaction (PCR) technique using allele-specific primers to detect both the normal and mutant alleles for the beta-thalassaemia mutation frameshift 41/42 (-TCTT)¹. The fetus was heterozygous for the beta-thalassaemia mutation frameshift 41/42 (Fig 1). The parents were informed of the result and elected to continue with the pregnancy.

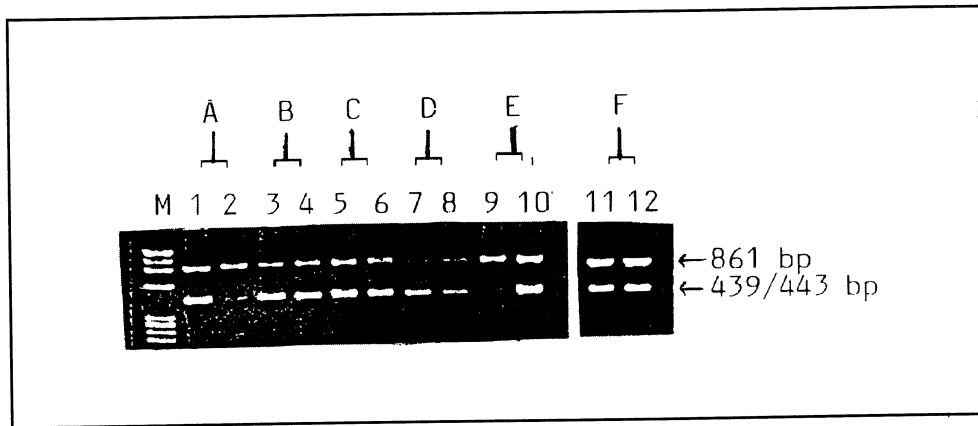


Fig 1: DNA analysis of chorionic villus sample (CVS) to detect beta-thalassaemia mutation frameshift 41/42.

Lane M: contains the X174 DNA size marker.

Lanes 1, 3, 5, 7, 9, 11: using primers to detect normal allele (439 bp DNA fragment).

Lanes 2, 4, 6, 8, 10, 12: using primers to detect mutant allele (443 bp DNA fragment).

The upper bands are the 861 bp DNA fragment of another part of the beta-globin gene used as internal control.

A: Normal DNA showing amplification only with normal primers.

B, C, D: DNA from father, mother and CVS, showing respectively amplification with both normal and mutant primers. Therefore they are heterozygous for the mutation.

E: DNA of known homozygous showing amplification only with mutant primers.

F: DNA from cord blood showing identical findings with that of the CVS, confirming baby's heterozygous state for the mutation.

The subsequent antenatal course was uneventful and, at 38 weeks' gestation, the patient went into spontaneous labour and delivered a 3.2 kg baby girl vaginally with a good Apgar score. There was no structural anomaly and DNA analysis of the baby's blood confirmed a heterozygous beta-thalassaemia mutation frameshift 41/42 (Fig 1).

Case 2

LYM was a 30 year old secundigravida at 11 weeks' gestation whose first child, as in the previous case, had beta-thalassaemia major. DNA analysis revealed that the patient was heterozygous for the beta-thalassaemia mutation frameshift 41/42 while her husband was heterozygous for the beta-thalassaemia mutation IVS II nt 654.

An ultrasound scan confirmed a viable intrauterine pregnancy of 11 weeks' gestation with a posterior placental site. After appropriate counselling and consent, a transabdominal CVS was carried out successfully as described previously. This patient too was Rhesus positive and did not require anti-D immunoglobulin.

DNA analysis of the chorionic villus sample showed the fetus to be heterozygous for the beta-thalassaemia mutation frameshift 41/42. As in the previous case, the parents elected to continue with the pregnancy. This pregnancy is ongoing and there has been no procedure-related complication to date at 20 weeks' gestation.

Discussion

Prenatal detection of beta-thalassaemia is a complex task because many different mutations can give rise to defective beta-globin chain synthesis. The use of synthetic oligonucleotides to detect directly a point mutation in the DNA that produces beta-thalassaemia was first described in 1983², but has hitherto not been available in this country. This direct technique of using radiolabelled oligonucleotide probes has been further refined and it is now possible to use non-radioactive direct gene amplification techniques which are simpler and quicker.

Although it is possible to obtain fetal DNA from an amniotic fluid sample, the chorionic villus gives a better yield. It has been estimated that a single chorionic villus gives the same yield of DNA as the cells in 10 ml of amniotic fluid³. The additional advantage of CVS is that it affords diagnosis in the first trimester. If an abnormal result is obtained, parents can then be given the option of a termination in the first trimester which is not only a simpler and safer procedure, but also psychologically advantageous compared to a second trimester termination of pregnancy.

The main drawback of CVS is the fetal loss rate of 2% to 4%⁴. This is due in part to the higher natural loss rate in the first trimester but is also related to the experience of the operator and the number of sampling attempts. We have shown that it is possible to obtain an adequate sample for DNA analysis with the transabdominal technique even with a posteriorly situated placental site without early fetal loss. The first case carried uneventfully to term, while the second case is ongoing at 20 weeks' gestation. Both these patients did not have any vaginal bleeding after the procedure and this is a known advantage of the transabdominal technique.

Given the frequency of beta-thalassaemia in this country, we believe that our results represent a significant development in the prenatal diagnosis of this condition in Malaysia. In order for couples to gain maximally from this type of first trimester diagnosis, medical practitioners and health workers should be aware that early referral is crucial so that appropriate and careful counselling can be carried out, ideally, even before a subsequent pregnancy is embarked upon.

Acknowledgement

We would like to thank our Dean, Professor Dato' Dr Khalid Abdul Kadir, who has been a constant source of support and encouragement. The techniques of DNA analysis were made possible by an IRPA project grant (03-07-03-03).

References

1. Old JM, Varawalla NY, Weatherall DJ. Rapid detection and prenatal diagnosis of beta-thalassaemia: studies in Indian and Cypriot populations in the UK. *Lancet* 1990;553 : 834-7.
2. Piratsu M, Kar YW, Cao A *et al*. Prenatal diagnosis of beta-thalassaemia: detection of a single nucleotide mutation in DNA. *New Engl J Med* 1983;309 : 284-7.
3. Williamson R, Eskdale J, Coleman DV *et al*. Direct gene analysis of chorionic villi: a possible technique for first trimester antenatal diagnosis of haemoglobinopathies. *Lancet* 1981;ii : 1125-7.
4. Jackson LG, Wapner RJ. Risks of chorionic villus sampling. *Clin Obstet Gynaecol* 1987;1 : 513-31.