

Fracture of the Penis

N. Kamil, FRCS*

A.N. Hisham, MD**

M. Abdullah, FRCS*

A. Khairullah, FRCS**

* Department of Surgery, Faculty of Medicine, Universiti Kebangsaan Malaysia, Jalan Raja Muda Abdul Aziz, 50300 Kuala Lumpur

** Institute of Urology, General Hospital, Jalan Pahang, 50586 Kuala Lumpur

Summary

Fracture of the penis is not an uncommon urological emergency. Six patients with this injury, treated at the Institute of Urology, General Hospital, Kuala Lumpur, since 1988, were reviewed. Their ages ranged from 21 to 30 years old (mean 25). Four cases were self-inflicted by abnormal bending and 2 cases occurred during sexual intercourse.

A sudden "cracking sound", violent pain, rapid flaccidity and deformity of the penis were documented. Duration of injury at presentation ranged from 12 to 90 hours (mean 35 hours). Primary repair of the tunica albuginea with absorbable suture was performed in all cases. The result of surgery was excellent, with restoration of normal function in 4 patients (2 patients defaulted follow-up). We advocate immediate surgical repair for this injury.

Key words: Penile injury, fractured penis.

Introduction

Rupture of tunica albuginea of corpus cavernosum, better known as fracture of the penis, is not an uncommon urological emergency. For the injury to occur, the penis is usually in the erect state. The injury rarely extends to involve the corpus spongiosum or urethra.

Published reports of this injury are few. Most of them stress the controversy of its management, either immediate surgical exploration or non-operative management. Owing to the data supporting early surgical intervention, we have advocated this policy. We compare our results with others.

Case Report

During the period between 1988 to 1992, 6 patients were admitted to the Kuala Lumpur General Hospital with the diagnosis of fracture of the penis. The patients ranged in age from 21 to 30 years old (mean 25). Three of them were Chinese and the rest were a Malay, an Indonesian and a Vietnamese. Five patients were single and only 1 was married.

In 4 cases, the fracture was due to abnormal bending of the penis, and in 2 cases it happened during sexual intercourse. In the cases that were due to abnormal bending of the penis, the excuses given for doing so were: "to soften the erect penis" and "to clean the penis". One of the patients who sustained the injury at coitus claimed that his erect penis hit the pubic bone of the partner. Three cases heard a snapping sound followed immediately by detumescence. All patients presented with pain, swelling and skin discolouration.

CASE REPORT

None of the patients had problems with voiding or haematuria. Hence, retrograde urethrogram was not necessary.

Mean duration of injury to treatment was 35 hours. These patients presented late for admission, due to embarrassment or sense of guilt. All patients were treated by surgical exploration, evacuation of the haematoma and repair of the ruptured tunica albuginea using absorbable sutures. In 3 cases, the incision was made subcoronal and circumferential with degloving of the penis. In 2 cases, the incision was transverse and in 1, longitudinal over the site of maximal swelling. The site of the fractures was in the tunica albuginea of right corpus cavernosum in 5 cases and in the left side in 1. None of the patients had associated urethral injury or injury extending to the opposite corpus cavernosum.

Most cases were put on indwelling catheter and all received antibiotics. No patient developed any infection. Apart from pain, for which non-steroidal anti-inflammatory drugs (NSAID) were given, no postoperative complication was seen. Two patients were also given stilboestrol to suppress erection in the postoperative period.

The average hospital stay was 3 days. Four patients returned for regular follow-up of up to 2 months. The remaining 2 patients were lost to follow-up. The 4 who were followed-up had good erection with no angular deformity or plaque formation.

Discussion

Fracture of the penis is not an uncommon injury. The penis must be erect for the injury to occur, as the tunica albuginea is thinned out by tension and a direct blow will cause the rupture. The usual description given by the patients is that of a snapping or cracking sound followed by immediate flaccidity, deformity, swelling with haematoma formation and violent pain. The blood extravasate from the corpora through the torn tunica albuginea into the shaft of the penis, and at the late stage the haematoma could involve the perineum, pubic and inguinal areas and the scrotum.

Though the injury is said to occur in the erect penis, there are cases reported of the injury occurring in a flaccid penis. In a Japanese review of 208 patients, it was found that 3% (6 cases) sustained the fracture while the penis was flaccid¹.

A majority of our patients were single and sustained the fracture probably through masturbation, but were too embarrassed to admit it. The injury occurred as a result of forcible manipulation of the erect penis during masturbation. Our observation is similar to that of the larger Japanese study where 48% of their patients sustained the fracture due to abnormal bending or from masturbation¹.

We favour the subcoronal circumferential incision followed by degloving of the penile skin (Fig 1). This wide exposure enables easy localisation of the site of fracture after evacuation of the haematoma (Fig 2). The tear in the tunica albuginea is sutured with interrupted 3/0 synthetic absorbable suture. The skin sleeve is then restored to its former position.

A urinary catheter is left indwelling and the patient given antibiotics. However, the use of the urinary catheter and the role of antibiotics is controversial and not all authors use them routinely². Two cases were given stilboestrol to suppress erection in the early postoperative period.

None of our cases had urethral injury. Frequency of urethral injury ranged from 20% to 38% of cases (USA and Europe) and 0% to 3% (Gulf and Japan)². Retrograde urethrogram should be done to exclude urethral injuries in patients with difficulty in voiding bleeding from the external meatus, or having significant microscopic haematuria.

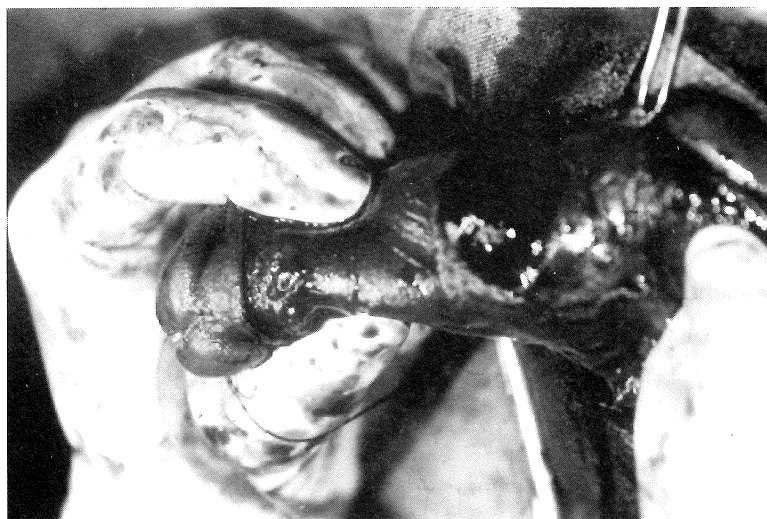

Fig 1: Shows the haematoma over the site of fracture after degloving the penile skin.

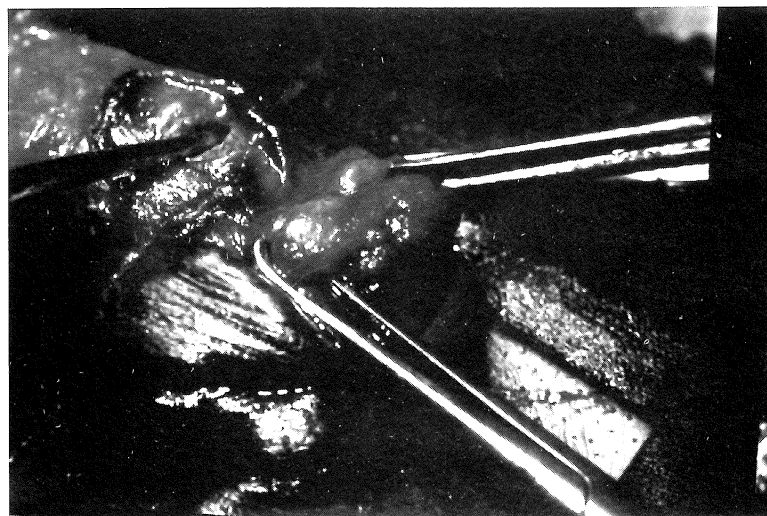


Fig 2: Shows the tear in the tunica albuginea after evacuation of the haematoma.

FRACTURE OF THE PENIS

In the literature, many different modes of conservative treatment have been mentioned; compression bandages, ice-packs, anti-inflammatory agents, and diazepam and stilboestrol to suppress penile erections. However, these treatments are often associated with the formation of penile plaque, penile fibrosis, weak and deformed erections and penile abscess³.

Conclusion

Fracture of the penis is not uncommon and can occur in the erect penis at the time of forcible manipulation, masturbation and sexual intercourse or in the flaccid penis due to direct physical trauma. It is seen in both single and married individuals. Diagnosis is usually easy. Our experience in dealing with this problem further supports the view that early surgical repair is the treatment of choice.

Acknowledgement

We would like to thank the Director-General of Health, Malaysia, for permission to publish this report.

References

1. Fujisue H, Yabumoto H, Shimada K *et al.* A case of fracture of the penis. *Acta Urol Jpn* 1984;30 : 797-801.
2. El-Sherif AE, Daulen M, Allowneh N, Vijayan P. Management of fracture of the penis in Qatar. *Br J Urol* 1991;68 : 622-5.
3. Nicolaisen GS, Melamud A, Williams RD *et al.* Rupture of the corpus cavernosum: surgical management. *J Urol* 1983;130 : 917-9.