

Acute Mesentero-axial Volvulus of the Stomach in a Child

D. Lopez, MS

General Hospital, Kota Bharu, Kelantan Darul Naim

Summary

A case of acute gastric volvulus associated with eventration of the diaphragm in a previously well 6 year old child is reported. The child presented with acute abdominal pain, abdominal distension and vomiting. At operation, mesentero-axial type gastric volvulus was found, associated with laxity of the gastro-splenic, gastrohepatic and gastrocolic ligaments and eventration of the left hemidiaphragm. Rapid recovery followed surgery that included release of distension and fixation of the stomach to the anterior abdominal wall. There has been no evidence of recurrence on a 2 year follow-up.

Key words: Gastric volvulus.

Introduction

Gastric volvulus is an uncommon acute abdominal condition rarely seen in children. It results from an abnormal rotation of the stomach of more than 180 degrees with closed loop obstruction. Berti¹, in 1866, first described gastric volvulus in an autopsy of a 60 year old woman. A review of world literature in 1971 by Cole² found only 44 cases reported in infants and children. Until 1980, 300 cases of gastric volvulus had been reported in literature and of these only 50 had presented in children³. Commonly, the patient presents with sudden epigastric pain, rapid development of epigastric distension followed by vomiting or retching. Borchardt⁴ described a triad of symptoms:

1. Non-productive vomiting.
2. Acute localised distension of the upper abdomen.
3. Inability to pass a nasogastric tube beyond the cardioesophageal junction.

Case Report

A 6 year old Malay boy was admitted to the General Hospital with a history of sudden abdominal pain and distension following dinner. He had a single episode of vomiting consisting of clear fluids and some food particles. On examination, the child was in pain. He was well-hydrated and vital signs were stable. There was a fullness over the epigastrium which appeared moderately tender to palpation. Bowel sounds were active. It was not possible to pass a nasogastric tube beyond the cardioesophageal junction. Plain X-ray of the abdomen showed a dilated stomach with an elevated left hemidiaphragm (Fig 1). Barium meal showed an inferiorly displaced fundus with the obstructed pyloroantral region lying superiorly (Fig 2).

At laparotomy, the stomach was grossly distended and overlying this was a distended transverse colon. All other organs appeared normal.

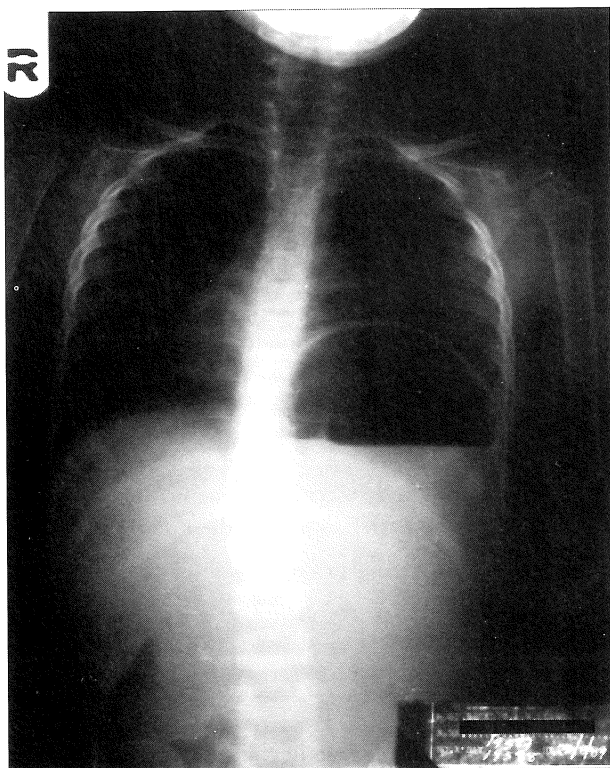


Fig 1: Plain X-ray of the abdomen. An inverted stomach with an air fluid level beneath an elevated left hemidiaphragm.

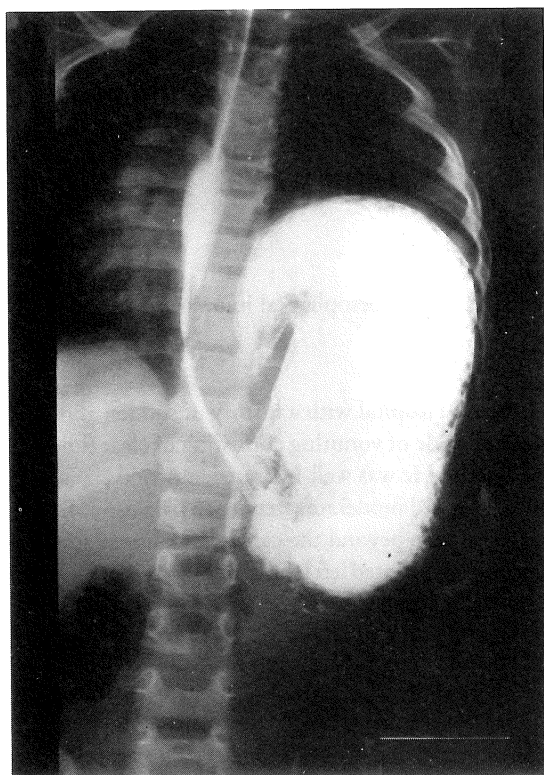


Fig 2: Barium meal.

ACUTE MESENTERO-AXIAL VOLVULUS OF THE STOMACH

The transverse colon was mobilised and separated from the stomach by dividing the gastrocolic ligaments. Mobilisation of the stomach was effected only after releasing the air and fluid within the distended stomach via a gastrostomy. As a result of the rotation the gastrostomy site became posteriorly located as the stomach untwisted following the release of the distension. This opening was closed in 2 layers. The stomach appeared healthy with no gross ischaemic effect.

The stomach was fixed to the anterior abdominal wall around a gastrostomy drainage tube that was removed on the second postoperative day. Recovery was uneventful. The patient was taking orally the third postoperative day and was discharged 2 days later. He has been well since, without any recurrence over a 2 year follow-up period.

Discussion

Typically, 2 types of gastric volvulus are encountered:

1. Organo-axial

In this situation there is rotation of the stomach around the coronal plane (cardiopyloric plane) (Fig 3).

2. Mesentero-axial

Here the rotation is along the long axis of the gastrohepatic omentum with the pylorus passing in front of the stomach (Fig 4).

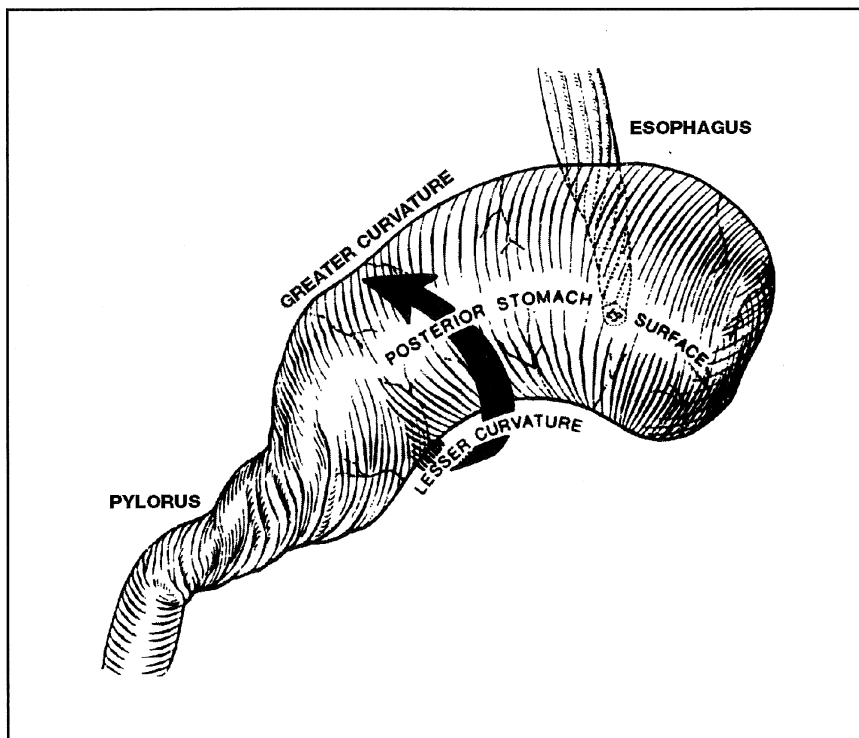


Fig 3: Organo-axial.

ACUTE MESENTERO-AXIAL VOLVULUS OF THE STOMACH

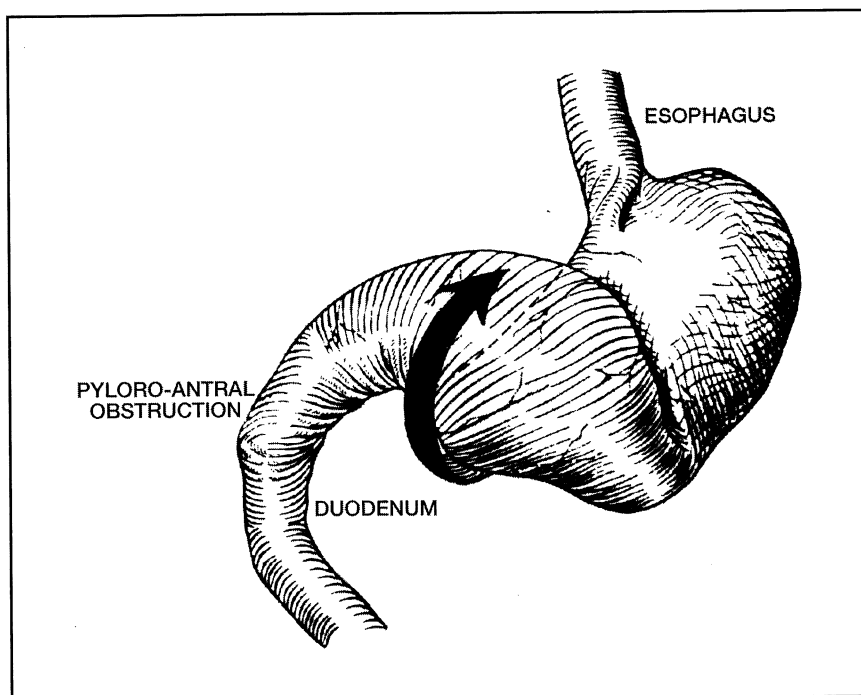


Fig 4: Mesentero-axial.

The various predisposing factors known to be associated with gastric volvulus include lax ligaments, paraoesophageal hernias, eventration of the diaphragm, over-filling of the stomach, aerocoly (distended colon) and absence or displacement of neighbouring viscera. There is a high incidence of diaphragmatic defects, including eventration of the diaphragm, associated with acute gastric volvulus, especially in the very young⁵. In the case presented, eventration of the left hemidiaphragm was observed. However, the child was asymptomatic and therefore did not require any treatment for this condition. It is sometimes possible to achieve reduction of the volvulus, commonly the mesentero-axial type, if a nasogastric tube can be successfully passed and the stomach emptied⁶. In the case reported, this was not possible as the nasogastric tube could not be negotiated beyond the cardiooesophageal junction. Surgical correction is directed to early release of the distension and prevention of ischaemic effects to the stomach. Gastric decompression rapidly restores anatomy in partial obstruction, as was noted in this case. Recurrence can be avoided by fixing the stomach to the anterior abdominal wall via a gastrostomy tube. Additionally, the gastrocolic ligament is divided to prevent a gas-filled colon from initiating a recurrence of the volvulus^{7,5}. This was done with good effect in this case.

References

1. Berti (1866). In: Carter R, Brewer LA, Hinshaw DB (eds). Acute gastric volvulus: A study of 25 cases. *Am J Surg*, 1980; 99-106.
2. Cole BC, Dickenson SJ. Acute volvulus of the stomach in infants and children. *Surgery* 1971;70 : 707.
3. Youssef SA, Di Lorenzo M, Yazbeck S, Ducharme JC. Gastric Volvulus in children. *Chir Pediatr* 1987;28 : 39-42.
4. Borchardt M (1904). In: Pillay SP *et al* (eds). *S.A. Medical Journal*, 1977; 19 : 880-5.
5. Carter R, Brewer LA, Hinshaw DB. Acute gastric volvulus: A study of 25 cases. *Am J Surg* 1980: 99-106.
6. Mitchell EA, Wojciechowski AH, Younghusband JD. Acute Gastric Volvulus in Childhood. *Br J Clin Pract* 1977;31 : 5, 61.
7. Tanner NC. Gastric Volvulus. *Am J Surg* 1958: 115, 505.