

# Gas-containing Liver Abscesses: Assessment by Ultrasound (US) and Computed Tomography (CT)

S.A. Samad, FRCR

M.A. Zulfiqar, MMed (Radiology)

A. Maimunah, MMed (Radiology)

*Department of Radiology, Faculty of Medicine, Universiti Kebangsaan Malaysia, Kuala Lumpur*

## Summary

Single gas-containing pyogenic liver abscesses in 11 patients were studied by ultrasound and computed tomography (CT). On ultrasound, all abscesses were predominantly echogenic compared to the normal liver parenchyma. The gas collections appeared as hyperreflective areas arranged in clusters associated with acoustic shadowing and ring-down artifacts. Ten abscesses (90%) had ill-defined margins on ultrasound, causing underestimation of their sizes in these patients. All abscesses were shown to be multiloculated and had clearly defined borders on CT, not appreciated or mistaken for multiplicity of abscesses on ultrasound. Ultrasound may be inadequate in the evaluation of gas-containing liver abscesses, as they have complex echotexture in addition to ring-down artifacts, acoustic shadows and poorly-defined margins; leading to underestimation of abscess size, difficulty in identifying loculations and erroneous interpretation of multiplicity of abscess cavities.

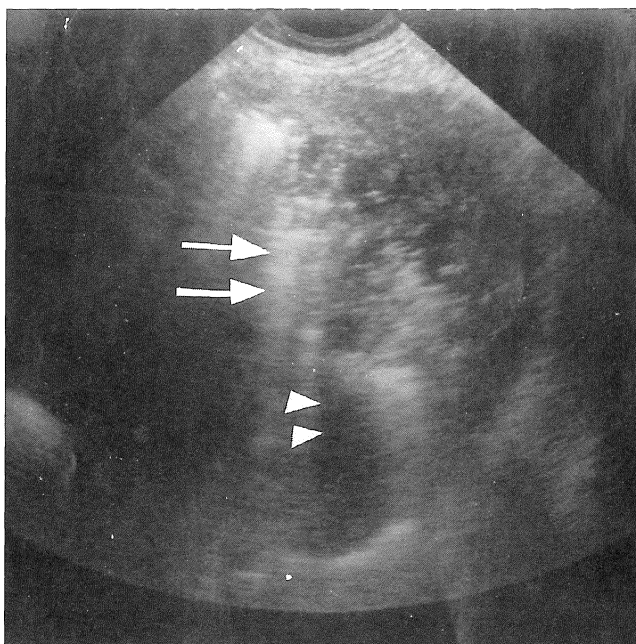
**Key words:** Ultrasound, gas-containing liver abscess, computed tomography.

## Introduction

The role of ultrasound in the diagnosis of liver abscess is well-established. Typically, it presents as a round, well-defined hypoechoic mass in the liver<sup>1-5</sup>. Less often, it manifests itself as an echogenic lesion<sup>6</sup>. This atypical feature could be due to many factors, which include unliquefied necrotic tissue, pus-containing debris and presence of gas pockets within the abscess cavity. Gas-containing liver abscess is very unusual and seems to be a feature of pyogenic abscess<sup>3,7</sup>. The presence of air in the abscess modifies the abscess morphology on ultrasound, due to the intense hyperreflectivity of gas and the presence of acoustic shadows and ring-down artifacts<sup>8-10</sup>. An acoustic shadow appears as a dark, anechoic band, whereas a ring-down artifact appears as a bright band consisting of a series of small, closely-spaced echoes deep to the gas. Further assessment by CT would be appropriate, as CT images are not degraded by the presence of gas and its associated artifacts. The aim of this study is to assess the ultrasound pattern of gas-containing liver abscess and compare the ultrasound findings with those on CT.

## Patients and Methods

From 1986 to May 1991, 11 single liver abscesses containing gas were identified when examined on ultrasound. Computed tomography was done to verify the ultrasound findings. Patients were made up of 6 males and 5 females with ages ranging from 27 to 63 years. Five patients had diabetes mellitus and 2 had cholecystectomies. Ultrasound examinations were done using Phillips SDR 1500 using 3.5 MHz sector transducer and Toshiba



**Fig 1: Ultrasound of gas-containing liver abscess. The gas collections are seen as hyperechoic foci associated with acoustic shadow (arrowheads) and ring-down artifact (arrows).**

100A using 3.75 MHz sector and convex transducers. Computed tomographic examinations were carried out using Phillips Tomoscan 350 and Toshiba 900S.

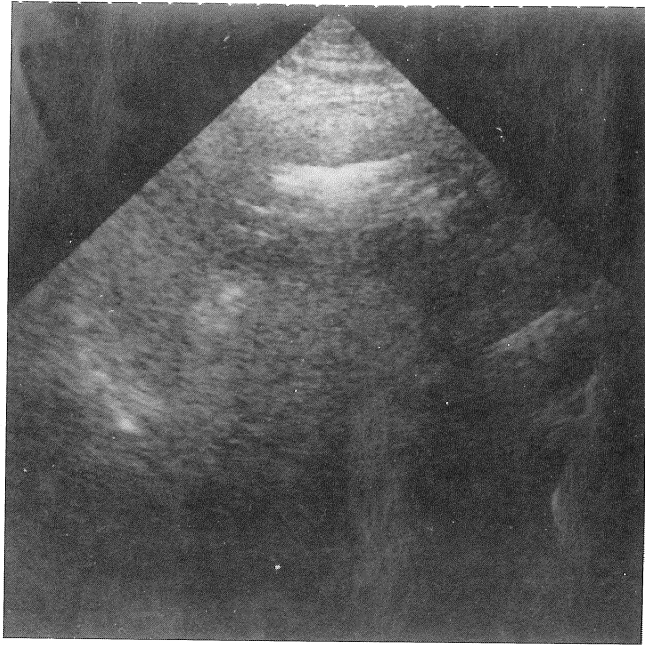
## **Results**

### **1. Ultrasound appearances:**

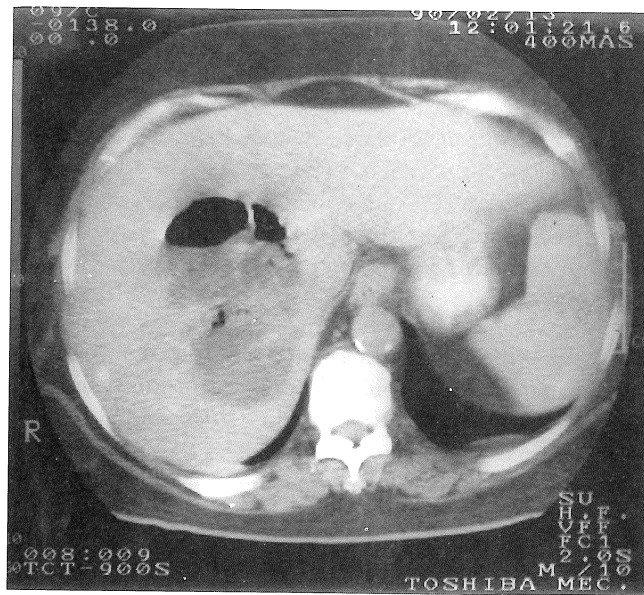
All abscesses were predominantly echogenic and inhomogenous. Gas collections appeared as hyperreflective foci appearing in clusters of varying sizes associated with acoustic shadowing and ring-down artifacts (Fig 1). The margins were poorly defined in 10 abscesses and clearly defined in 1. Ten abscesses were reported in the right lobe. Six abscesses were reported to be single and the remaining 5 were multiple.

### **2. Comparison of ultrasound CT appearances:**

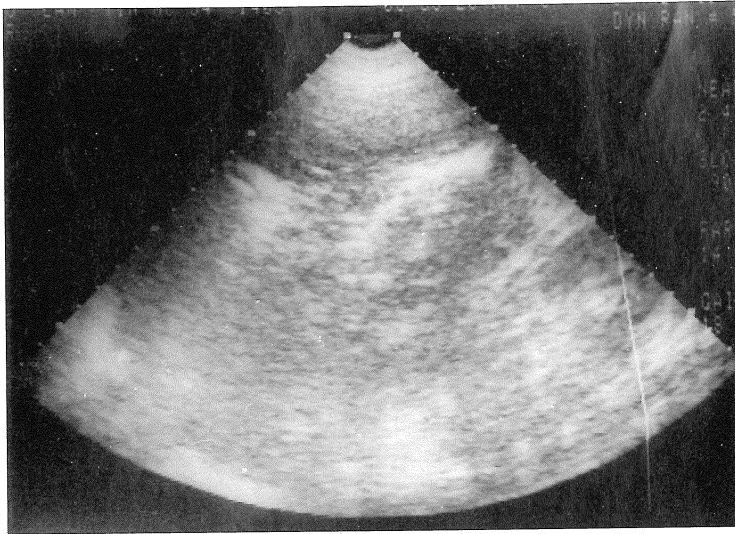
All abscesses had clearly-defined margins on CT (Fig 2). They were also all single and multiloculated on CT, despite the suggestion of multiplicity of abscess cavities on ultrasound in 5 patients (Fig 3). Of the 10 abscesses reported to be in the right lobe of the liver on ultrasound, 2 were actually in the right and left lobes and 1 was in the medial segment of the left lobe (Fig 4). One abscess was consistently identified to be in the left lobe on both ultrasound and CT.



**Fig 2a :** The abscess margin is not well-defined on ultrasound.



**Fig 2b :** CT showed a well-defined abscess cavity which is multiloculated and containing air fluid levels.



**Fig 3a : Ultrasound showed multiple abscess pockets interpreted as multiple abscesses.**

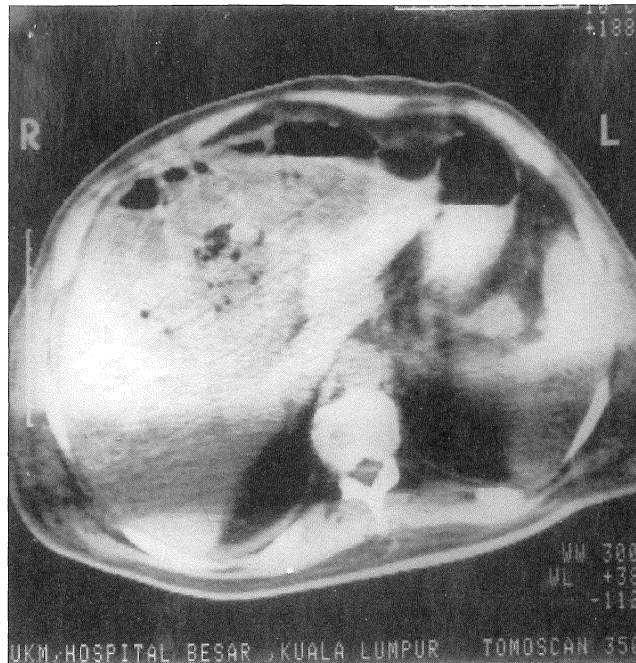
Pus was obtained either by percutaneous aspiration or surgical evacuation of the abscess. The pus obtained was purulent and typical of pyogenic liver abscesses. In 4 patients, the pus did not grow any microorganism. *Klebsiella* species and *E. coli* were isolated in 5 and 4 patients respectively.

### **Discussion**

Gas within the hepatic parenchyma with or without air-fluid level is a diagnostic sign of an intrahepatic abscess on plain radiographs<sup>3</sup>. However, this is an uncommon finding of liver abscess and appears to be a feature shown by pyogenic liver abscess and was seen in 14% to 25% of such cases<sup>3,6</sup>. Since most liver abscesses are amoebic, the overall percentage of gas-containing liver abscesses would be much lower. All the gas-containing liver abscesses in this series were pyogenic. The negative culture of the pus obtained from some patients is likely to be due to prior antibiotic treatment<sup>11</sup>.

Ultrasound is an excellent imaging modality for detecting fluid and for assessment of parenchymatous organs. Thus, abscess collections containing fluid pus would not be difficult to detect and characterise. Gas-collections within abscesses degrade the ultrasound image from acoustic shadowing and ring-down artifacts. Besides, acoustic shadowing in the liver is also seen in aerobilia and intrahepatic stones. Not only will the appearances of these conditions mimic gas-containing liver abscesses, but small abscesses associated with them may not be detected.

Underestimation of size on ultrasound is due to the fact that most gas-containing abscesses have poorly-defined margins. In addition, acoustic shadowing obscures part of the abscess cavity. This prevents precise characterisation of the abscess echopattern, leading to lack of appreciation of loculations. Fluid pus in between clusters of gas collections may cause misinterpretation of a single abscess as multiple.



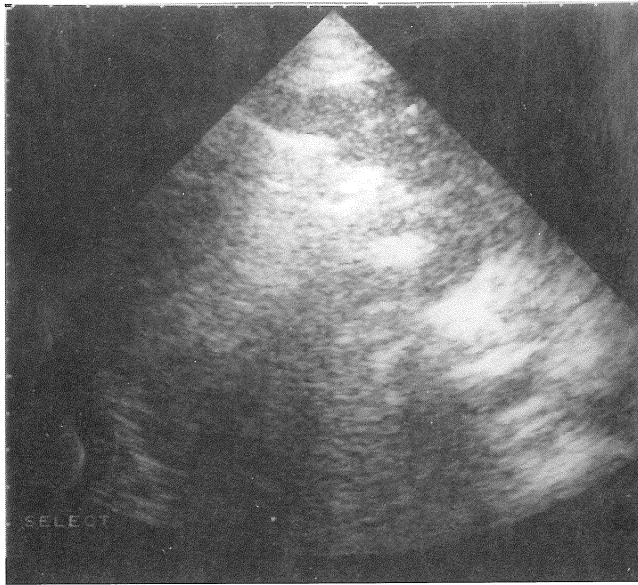
**Fig 3b : CT showed a large, single abscess in the right and left lobes of the liver with multiloculations.**

Computed tomography is the most reliable imaging modality for detecting abscesses in the liver<sup>11</sup>. Furthermore, it may add more information than demonstrated by the ultrasound in the majority of cases<sup>3</sup>. However, CT is not used routinely in the evaluation of liver abscesses mainly because it is expensive and time-consuming. Because of the problem of ultrasound imaging in the presence of gas, CT would be valuable in the assessment of gas-containing liver abscesses. It enables precise morphologic information of the abscess — exact location, size, number and presence of loculations to be obtained — which would be important in determining the treatment strategy.

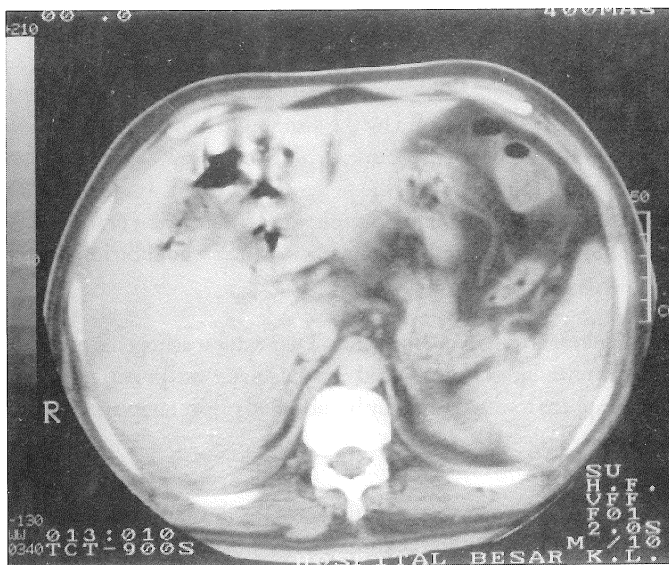
In summary, gas-containing liver abscesses are pyogenic. They exhibit echogenic inhomogenous patterns and poorly-defined margins on ultrasound. Ultrasound is inadequate for providing information on size and presence of loculations. Computed tomography may be indicated to give an accurate picture of its morphology.

### **Acknowledgement**

The authors would like to thank En Kamaruzaman Othman of the Illustration Unit of the Faculty of Medicine, Universiti Kebangsaan Malaysia, for the photographs.



**Fig 4a :** Ultrasound showed a gas containing abscess which appears to be in the right lobe.



**Fig 4b :** CT demonstrated the abscess to be located in the quadrate segment of the left lobe.

**Reference**

1. Ralls PW, Meyers HI, Lapin SA, Rogers W, Boswell WD, Halls J. Gray-scale ultrasonography of hepatic amoebic liver abscess. *Radiology* 1979;132 : 125-9.
2. Boulton JE, Simjee AE, Rooknooden F, Engelbrecht HE. Experiences with gray-scale ultrasonography in hepatic amoebiasis. *Clinical Radiology* 1979;30 : 683-9.
3. Rubinson HA, Isikoff MB, Hill MC. Diagnostic imaging of hepatic abscesses: A retrospective analysis. *Am J Roentgenol* 1980;135 : 735-40.
4. Newlin N, Solven TM, Stuck KJ, Sandler MA. Ultrasonic features of pyogenic liver abscesses. *Radiology* 1981;139 : 155-9.
5. Ralls PW, Colleti PM, Quinn MF, Halls J. Sonographic findings in hepatic amoebic abscess. *Radiology* 1982;145 : 123-6.
6. Dalrymple B, Fataar S, Goodman A, Morton PCG, Roman TE, Schulman A. Hyperechoic amoebic liver abscess. Unusual ultrasonic appearances. *Clinical Radiology* 1982;33 : 541-3.
7. Kuligowska E, Connors SK, Shapiro JH. Liver abscess: Sonography in the diagnosis and treatment. *Am J Roentgenol* 1980;138 : 253-7.
8. Kressel HY, Filly RA. Ultrasonographic appearances of gas-containing abscess in the abdomen. *Am J Roentgenol* 1978;130 : 71-3.
9. Conrad MR, Bregman R, Kilman WJ. Ultrasonic recognition of parenchymal gas. *Am J Roentgenol* 1979;132 : 395-9.
10. Avruch L, Cooperberg PL. The ring-down artifact. *J Ultra Med* 1985;4 : 21-8.
11. McDonald MI, Corey GR, Gallis HA, Durack DT. Single and multiple pyogenic liver abscesses: Natural history, diagnosis and treatment with emphasis on percutaneous drainage. *Medicine* 1984;63 : 291-305.