

# Modified subtotal cholecystectomy: A procedure for the difficult gall bladder

T. F. T. Khan

*Department of Surgery, Hospital Universiti Sains Malaysia, Kubang Kerian, Kelantan*

## Summary

Modified subtotal cholecystectomy involves removal of the gall bladder after circumferential division of the neck. Either the impacted stone or the surgeons finger was used as a guide to identify the neck. The stump cavity in the neck is obliterated with interrupted sutures to prevent recurrent stone formation. Indications for this procedure are obscure anatomy, due either to the severe inflammation in acute cholecystitis or dense adhesions in the small fibrosed gall bladder. The decision to perform modified subtotal cholecystectomy is taken during the operation. Forty three patients (14%) underwent this procedure during the period between August 85 and April 90. Out of 289 cholecystectomies performed seven were emergency and thirty-six were early cholecystectomies. With the increasing trend towards urgent and early cholecystectomy in acute cholecystitis the author has found this to be a safe and definitive procedure.

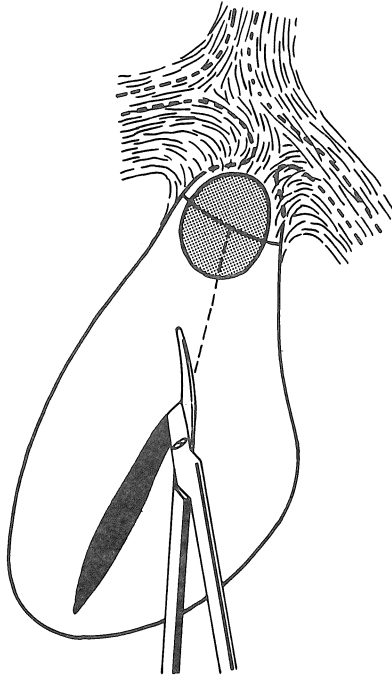
*Key words:* Difficult gall bladder, modified cholecystectomy, stump cavity obliteration

## Introduction

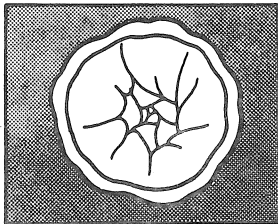
A modification of the standard cholecystectomy, which was found to be useful both in the acute inflammatory stage as well as in the small fibrosed gall bladder is described. In such situations access to the junction of the cystic with the common hepatic duct is both difficult and dangerous. Attempting a standard cholecystectomy puts the anatomy at a significant risk of being damaged and cystic duct cannulation is usually not possible.

## Method

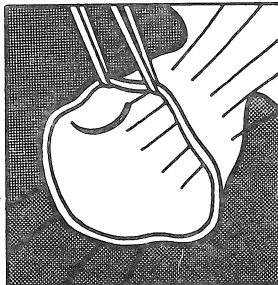
The contents of the gall bladder are aspirated through the fundus and sent for culture and sensitivity. If a stone is impacted in the neck, it is not dislodged. The gall bladder is opened with a scissors at the fundus. The incision is extended up to the neck which contains the impacted stone. The neck is then divided circumferentially on the stone exposing almost half the stone (Fig. 1). In the presence of smaller stones, the neck is divided 1 cm from the distal edge of the stone. The presence of the stone beyond the division safeguards the extra hepatic bile ducts. The posterior wall of the neck is divided under vision from within. In this process the cystic artery is also divided as at this point it has entered the wall of the gall bladder and is suture ligated. After the division, the remaining part of the gall bladder is dissected off the liver as in a standard operation. The remnant neck resembles a cup (Fig. 2a), the orifice of the cystic duct is rarely identifiable, thus preoperative cholangiography was not attempted. The cavity in the neck is obliterated with interrupted sutures, taken at a suitable distance from the cut edge (Fig. 2b). These sutures also help in controlling bleeding from the cut edge. The result, after the sutures are tied is illustrated in Fig. 2c.



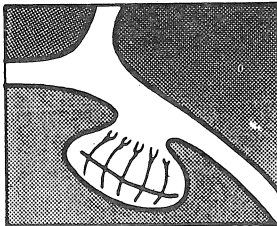
**Fig. 1:**  
**The gall bladder is slit upto**  
**the impacted stone prior to**  
**circumferential division of**  
**the neck**



**Fig. 2(a) :**  
**Appearance of the neck following modified**  
**sub total cholecystectomy**

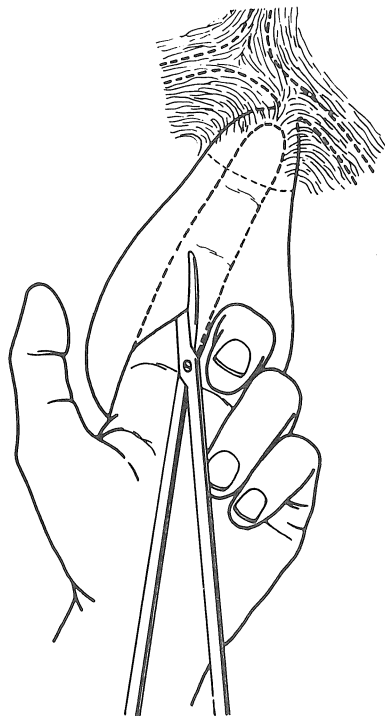


**Fig. 2(b) :**  
**Interrupted sutures of 2/0 chromic catgut**  
**in place**



**Fig. 2(c) :**  
**Appearance of the neck after sutures**  
**have been tied**

In the event of stone dislodgement or acalculous cholecystitis, the left index finger is introduced through the opening in the fundus. The finger is advanced towards the neck until it meets with resistance, indicating that the tip of the finger is in the neck and that the junction of the cystic duct and common hepatic duct lies beyond it (Fig. 3). The incision is extended in the direction of the neck and stops about 2 cm from the tip of the finger. The circumferential incision is now made to separate the neck from the rest of the gall bladder and the operation completed as described before.



**Fig. 3:**  
**Open gall bladder with finger**  
**in position at the neck**

## **Discussion**

Subtotal cholecystectomy was first described by Thorek<sup>1</sup> where the cystic duct transection is followed by cautery of the remaining posterior gall bladder wall which is left attached to the liver. Bornman and Terblanche<sup>2</sup> describe a procedure of piecemeal excision of the Hartmanns pouch to expose the cystic duct, which is either closed with a purse string suture or a suture is placed around it but also leave the posterior gall bladder in situ, securing haemostasis with a running catgut suture around the cut edge. This would seem ideal in patients with portal hypertension but the rationale of leaving the posterior wall in situ in acute cholecystitis after isolating the cystic duct is not clear. They do not have a very high success rate of cystic duct cannulation, since this is always found to be occluded at operation. Patients requiring an operative cholangiogram would have preoperative indications suggesting common duct pathology, which would be better served with an ERCP rather than a tedious procedure in a difficult situation.

If a common bile duct exploration is done then a subtotal cholecystectomy can be converted to a standard cholecystectomy since the duct is open. Douglas and Ham similarly retain the posterior gall bladder wall.<sup>3</sup> The stump is closed under vision to obliterate the cavity and to prevent continuity with the biliary tree and stone recurrence, once the oedema has settled. The post cholecystectomy syndrome

is questionable<sup>4,5</sup> as it is caused either by a stone remaining in the stump or by stone recurrence. In the present procedure no attempt was made to identify the cystic duct orifice, since in suspected cases preoperative ERCP gives all the information. If the Mirizzi syndrome is suspected, a preoperative ERCP would identify the cystobiliary fistula, which could be repaired using the remnant gall bladder.<sup>6,7</sup>

The procedure has been used by the author since August 85 and a four year follow up on 43 patients (14%) revealed no adverse complications related to the procedure. During follow up these patients were first seen two weeks after discharge and then after two months, standard liver function tests were done at each visit. It gives the surgeon the confidence during difficult cholecystectomies knowing that this procedure is both safe and definitive.

## References

1. Maingot R. Abdominal operations. East Norwalk Appleton Century-Croft 1940; 762 - 7.
2. Bornman PC and Terblanche, J. Subtotal cholecystectomy, *Surgery* 1985; 98: 1, 1-6.
3. Douglas, PR. Ham, J.M. Partial cholecystectomy *Aust. N.Z.J. Surg* 1990; 60 : 595-7.
4. Bodvall B. Post cholecystectomy syndrome. *Clin Gastroenterol.* 1973; 2 : 103-26.
5. Hopkins S F, Bivins B A, Griffin W O. Problem of cystic duct remnant *Surg Gyn Obstet* 1979; 148 : 531 - 3.
6. Venkatesh RPS, Tandon RK, Kapur BML. Bilio-biliary fistula-review of 9 cases *Am. J. Gastroenterol.* 198; Vol. 83 : 6, 652-7.
7. Csendes A, Diaz J C, Burdiles P, Maluenda F, Nava O. Mirizzi Syndrome and cystobiliary fistula: a unifying classification *Br. J. Surg.* 1989; 76 : 1139 - 43.