

Ulcerative keratomycosis – case reports on three different species of fungi

K. Sukumaran, RCPS, MCOphth

Associate Professor

Department of Ophthalmology, Faculty of Medicine, University Malaya.

Summary

Three clinical cases of fungal corneal ulcers are described to highlight the course, ocular morbidity and principles of treatment. A brief discussion of the diagnosis and management of ulcerative keratomycosis is presented.

Key words: Fungal corneal ulcers, ulcerative keratomycosis.

Introduction

Ulcerative keratomycosis is a serious condition which requires early diagnosis and prompt treatment. They have been reported to cause exogenous and endogenous endophthalmitis, orbital cellulitis and infection of the lacrimal passages. These ulcers, once seen only in agricultural workers, have become relatively common in the urban population since the introduction of corticosteroids for use in ophthalmology in 1952. Some corneal ulcers heal very well with treatment while others take a prolonged course sometimes requiring corneal grafts.

Case Report

Patient 1: A 25 year old clerk was accidentally pricked in his right eye by a leaf while gardening. He had redness and irritation of the eye for which he was treated with topical chloromycetin and subsequently with topical Betnesol. However, symptoms persisted and he presented three weeks later with blurred vision. On examination, vision in the right eye was 6/18. There was an oval ulcer in the temporal part of right cornea measuring 4mm x 3mm (Fig. 1). Fine feathery stromal infiltration extended from the ulcer and signs of iritis was evident. Corneal scrapings from the lesion showed fungal hyphae and cultures grew *Aspergillus oryzae*. Hourly Amphotericin B eye drops and daily subconjunctival injection of Amphotericin B 0.125 mg was immediately started. There was a good response - infiltration ceased, anterior chamber inflammation resolved and there was progressive re-epithelialisation. About two months later there was a stromal scar without any activity and the refracted vision was 6/9.

Patient 2: Three weeks before presentation, a 31 year old factory worker felt a foreign body in his left eye, while riding a motorcycle. The next day, a corneal foreign body was removed with a needle in a district hospital where he sought treatment. He was prescribed chloromycetin and hydrocortisone eye drops. However, he remained symptomatic and vision progressively deteriorated. On admission, vision in the left eye was 6/36 and there was a corneal ulcer measuring 4mm x 4mm involving the upper temporal quadrant. The margin of the ulcer was ill-defined, the surrounding cornea was oedematous with folds in the Descemet's membrane. Flare and cells were present in the anterior chamber indicating intraocular inflammation. Corneal scrapings for fungus grew *Malbranchea* species.

Although antifungal treatment with topical and subconjunctival Amphotericin B resolved the infiltration in two weeks, a non healing ulcer persisted. Repeat scrapings did not show any fungal or bacterial growth. Amphotericin toxicity was suspected and on withdrawing the drug, the ulcer resolved in three weeks leaving a faintly vascularised corneal scar. Vision was correctable to 6/18.

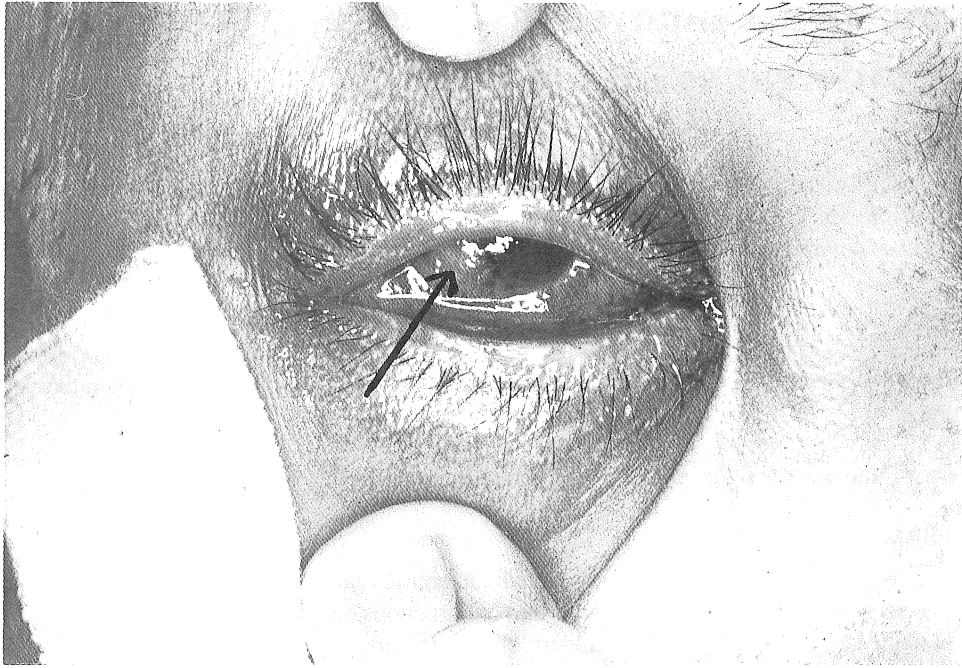


Fig. 1 : Arrow shows fungal ulcer in temporal part of right cornea

Patient 3: A 40 year old oil palm estate worker was pricked in the rihgt eye by a leaf from the oil palm tree. He was referred alter three weeks treatment in an Estate Hospital, manned by by medical assistants, because of increase in pain and further loss of vision. On examination there was right periorbital cellulitis with oedema (Fig.2). The vision in the right eye was hand movements. There was an oval central ulcer measuring 5mm 4mm, with moderately dense infiltration. Corneal scrapings grew *Aspergillus fumigatus*. Teratment with Amphotericin B was commenced - however there was further progression in the infiltration, abscess formation and a 3mm hypopyon. Topical miconazole necrosis and about four weeks after admission a corneal graft was done in view of impending corneal perforation. He had a prolonged post-operative course. The corneal graft turned opaque but there was no further dissolution of corneal tissue. Vision was counting fingers only. Patient however defaulted treatment and was never seen again even though he was listed for a re-graft.

Discussion

A case of hypopyon ulcer caused by *Aspergillus* species was described in 1897. In 1953 Thygeson highlighted the relationship between use of corticosteroid drops and increased susceptibility. However, in Jone's series, 16% of cases did not have any prior topical corticosteroid treatment at all. Hence, for the development of fungal keratitis, prior topical corticosteroid therapy is not a prerequisite.

About 180 species of fungi can cause human infection. The filaments of a fungus are usually introduced by injury, frequently by a foreign body contaminated with vegetable matter such as a branch, leaf or shrub. A fungus infection should be considered in every persistent corneal ulceration. Some gain entry into the eye by estension from infected eighbouring structures like the sinuses or through perforating wounds. Of the filamentous fungi, *Aspergillus*, *Fusarium* and *Cepharosporium* are the most common, whereas *Candida* is the principal culprit amongst the yeast especially in eyes with pre-existing epithelial or stromal ulceration. Clinically, fungal keratitis is commonest in men

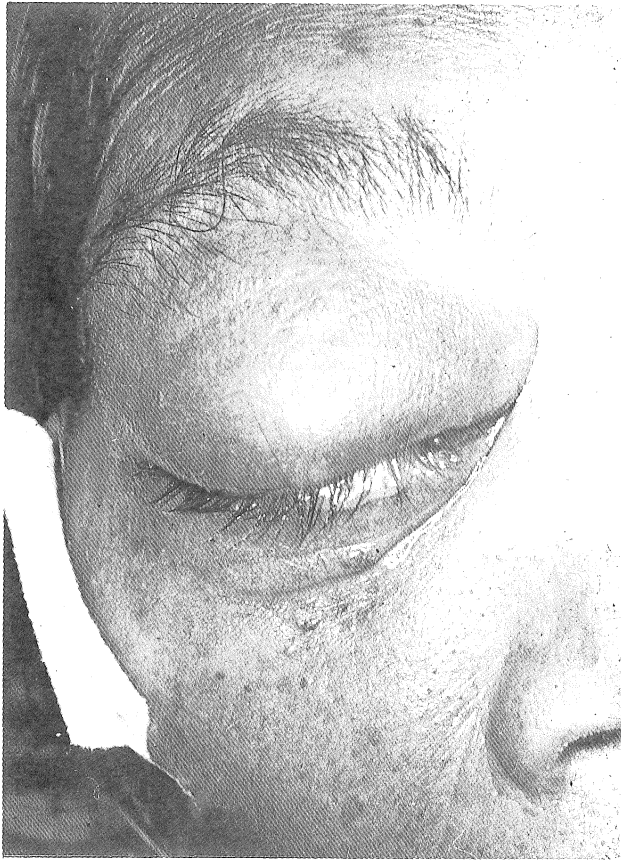

Fig. 2 :
Shows right periorbital
cellulitis

involved in outdoor activities especially if there has been trauma to the cornea by vegetable or animal matter. Typically, the disease has a subacute or indolent course presenting with ill-defined shallow ulcers with corneal stromal infiltration. Severe ocular inflammation with hypopyon and folds in the Descemet's membrane occur. With corticosteroid drops stromal necrosis and ulceration is accelerated leading to perforation and endophthalmitis. Early diagnosis is of importance and corneal scrapings for fungal hyphae elements must be examined with Gram, Giemsa or KOH preparation. In addition to Sabouraud's medium, most of the ocular pathogenic fungi show good growth in blood agar within three days. Treatment has significantly improved with new drugs like Gutt Natamycin, Gutt Miconazole, oral Ketoconazole and Flucytosine. However, problem of slow response, chronic non-healing ulcers from drug toxicity and non-infectious stromal inflammation complicate therapy. Some eyes do not heal until a conjunctival flap is drawn over the cornea surgically. In some, like patient 3, medical treatment fails necessitating a corneal graft and further morbidity. At surgery, removal of all corneal suppurative areas may have a beneficial effect but frequently a large corneal graft is necessary. It needs to be emphasised again that keratitis, corneal abrasions, corneal foreign bodies or corneal ulcers should not be indiscriminately treated with corticosteroid drops and awareness and early referrals of all corneal ulcers are of utmost importance.

Conclusion

Corneal ulcers of any etiology should be referred to the nearest Eye Centre for treatment. In general practice, topical steroids can be prescribed after consulting an ophthalmologist.

Acknowledgement

The author wishes to thank Dr Mahendraraj, Consultant Ophthalmologist, Malacca, for allowing me to follow up one of his patients and Ms T C Yap for the secretarial services.

References

1. Thygeson, Hogan, Kimura, Corticosteroid eye drops and keratitis, *Trans Amer Acad Ophthal* 57, 64(1953).
2. Jones D B., Strategy for the initial management of suspected microbial keratitis. Pg 86. In: *Symposium on Medical and Surgical Diseases of the Cornea*, C V Mosby St Louis, 1980.
3. Glyn E, Ebant V and James C Gentles. *Essentials of Medical Mycology*. Churchill Livingstone. U.K. 1985.
4. Jones BR Principles in the management of Oculomycosis, *American Journal of Ophthal* 79, 719, 1975.