

# Non-ionizing radiation exposure causing ill-health and alopecia areata

Ab. Rahman Isa MBBS, MPH&TM, MHPEd.  
*Assoc. Prof.*  
*Dept. of Community Medicine*

Mokhtar Noor MD. MSc (Dermatology)  
*Lecturer*  
*Dept. of Medicine, School of Medical Sciences*  
*Universiti Sains Malaysia, 16150 Kubang Kerian, Kelantan.*

## Summary

Three cases of occupational exposure to radio-frequency and microwave radiation were seen at the out-patient clinic, Hospital Universiti Sains Malaysia. They presented with run-down symptoms of neck strain associated with throbbing headache, irritability, loss of appetite, fatigue, memory difficulties, and numbness of extremities. They also presented with alopecia areata which is felt to be causally linked to the radiation exposure.

**Keywords:** Radiation, non-ionizing, radio-frequency, microwave, occupational exposure, alopecia areata.

## Introduction

Health hazards from non-ionizing radiation are a growing concern because of its ubiquitous presence in our environment from power lines to computer monitors and domestic electrical appliances. Although the dangers due to ionizing radiation (gamma-rays, X-rays) are well documented, the adverse effects of non-ionizing radiation are mostly inconclusive and contradictory. This study presents case reports of occupational exposure to radio-frequency and microwave radiation seen at the out-patient clinic of the Hospital Universiti Sains Malaysia.

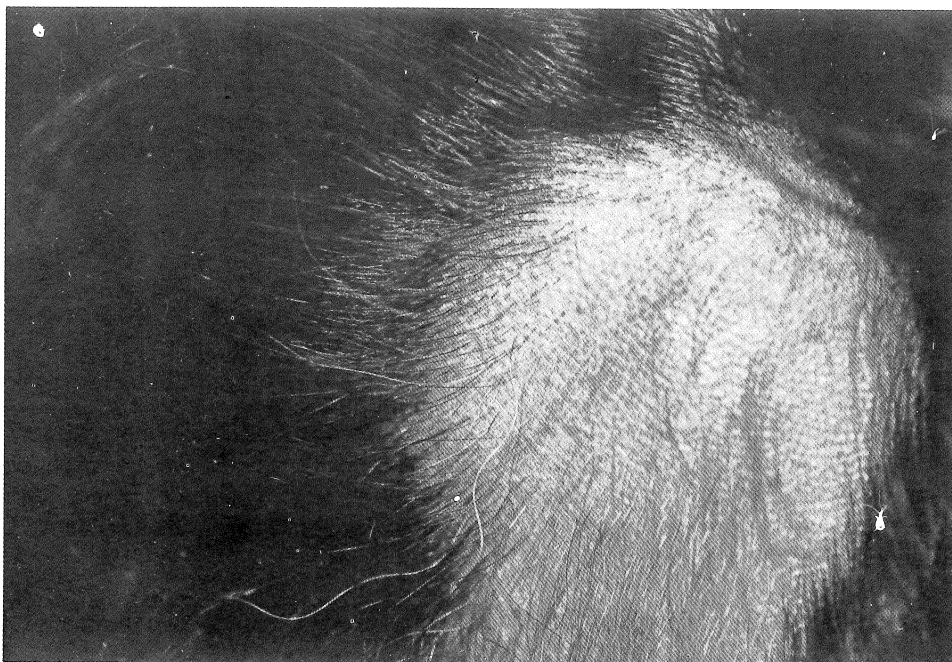
## Case reports

**Case no. 1:** ARA, a 38-year old Malay man, presented in December 1990, with a multiple complaints of neck strain associated with throbbing headache, fatigue, diminishing appetite, and marked weight loss. He also admitted of having short temper, a fleeting memory, and numbness in the lower limbs. These symptoms appeared over a period of 2 months. During this time he noticed a balding patch on the left side of the back of his head.

He works as a technician, maintaining television transmitters of 1000 watt electrical strength each. After each session of working 2 hours in the transmitter room, he often felt weak and exhausted. Although he has been working at the job for 12 years, he was directed to perform maintenance work while the alternative transmission was on during the past 1 year.

On examination, he was of slim built with an alopecia patch of about 4 cm. diameter on the left occipital region of the scalp. A few exclamation-mark hairs were seen at the margin of the patch. His eyes developed arcus senilis but no cataract. No other remarkable sign was seen in other systems and the

fingernails were normal. On re-examination 3 month later, new white hair growth was seen at the alopecia site (Fig.1).



**Fig. 1 : Case no 1 with scalp alopecia characterised by exclamation-mark hairs and new white hairs**

**Case no. 2:** ARS, a 38-year old Malay man, presented at the same time with a history of fatigue associated with a floating feeling and loss of appetite of 3 months duration. His temper was short with a moodless outlook towards life. He also noticed a balding patch on the right side of the back of his head and a reduced strength with numbness of the left arm.

He works as an aerial rigger, installing and maintaining antenna on the transmitting tower of 400 feet high. His employment began 11 years ago. In the earlier years he was able to perform his tasks during periods when the transmission was off. However during the last year or so, his tasks were performed mostly during active transmission. the tower climbing frequency was about 10 to 50 times a month. On examination, his left arm was discernibly weaker than the right in grip, elbow flexion and extension, and shoulder abduction. No sensory deficit was detected. There was an alopecia patch of 4 cm. diameter on the right occipital region of the scalp, with a few exclamation-mark hairs seen around the margin. All other systems were non-remarkable. On re-examination 3 months later and after receiving a course of intralesional injections of steroid, the alopecia site has undergone complete hair regrowth. **Case no. 3:** WFM, a 33-year old Malay man, presented at the same time with a history of neck strain associated with throbbing headache, fatigue, floating sensation and loss of appetite of 2 months duration. His barber discovered a balding patch on the left side of the back of his head.

He works for 11 years as an aerial rigger. Since 4 months ago, he has to perform maintenance tasks on the tower while the transmission was on.

On examination, he has an alopecia patch of 3 cm. diameter on the left occipital region of the scalp with a few exclamation-mark hairs around the margin. No abnormality was detected in other systems. A follow-up visit 3 months later and after receiving a course of intralesional injections of steroid, the alopecia site showed complete hair regrowth.

Laboratory investigations: Full blood picture, erythrocyte sedimentation rate, thyroid function tests, and antinuclear antibody assay were done on all the 3 patients and found to be within the normal range. Scalp punch biopsy done on ARA confirmed alopecia areata.

### Discussion

Electro-magnetic radiation which range from the powerful gammarays to the seemingly benign radio-frequency and microwave is in most situations not detectable by human senses. Therefore exposures readily occur at least in small doses over a long cumulative durations.

The adverse effects of this chronic exposure are seen in these patients as neck strain associated with throbbing headache, fatigue, irritability, floating sensation, loss of appetite, memory difficulties, and numbness of extremities - the run-down symptoms. The prognosis of these subjective symptoms are considered to be reversible. Although the evident is circumstantial, the authours feel that there is a causal link between chronic exposure to radio-frequency and microwave radiation to alopecia areate. Ionizing radiation exposure resulting in scalp alopecia (cicatricial type) is well established<sup>2</sup>. However no report is found linking alopecia areata with non-ionizing radiation.

The reversibility of the symptoms does not guarantee that the patients are free possible cellular damage. Small animals exposed to microwave showed neuronal degeneration in the brain, tissue damages in the kidneys and muocardium<sup>1</sup>.

Broadcast transmitters constitute a radiation hazard to the maintainance crew servicing towers and transmitting equipments.

The working environment is flooded with radio-frequency and microwave radiation whenever the transmitters are in full operation in addition to constant high noise level which may lead to partial deafness (Fig.2). The numbness to extremities is particularly hazardous to tower climbers.




Fig. 2 : Television transmitters with electro-magnetic radiation environment

To protect the maintainance crew against this type of occupational disease id difficult because current knowledge in this field is far from complete. The exposure threshold, safety standards, and biological effects of the non-ionizing radiation need to be further studied<sup>3</sup>. In the workplace, the telecommunication engineer should determine emission and eposure levels and provisionally adopt some standards from developed countries to protect the workers<sup>4</sup>. The occupation safety factor should not be ignored in designing the workplace and equitment installation.

### Acknowledgement

The authours would like to thank Dr. Ahmad Zakaria, lecturer in nuclear medicine, USM for advices in preparing this paper.

### References

1. Michealson S.M. Microwave and radio-frequency radiation. In: Non-ionizing radiation protection. WHO regional publications. European series no.10. Copenhagen, 1982.
2. Moscona R; Ullman Y; Bergman R; Friedman-Birnbaum R. Postirradiation extensive cicatricial scalp alopecia treated by tissue ecpansion. Jour. Dermatol. Surg. Oncol.(US) 1989; 15: 337-41.
3. Monson R.R Editorial commentary: Epidemiology and exposure to electro-magnetic fields. American jour. of Epidemiology 1990; 131:774-5.
4. Wilkening G.M.; Suttom C.H. Health effects of non- ionizing radiation. Med. Clinic of North Amer. (US), 1990; 74: 489-507.