

Facial nerve palsy by nasal tumour – a case report

Vijay K. Khanijow, MBBS, FRCSED

Lecturer

Dept of Otorhinolaryngology, Faculty of Medicine, University of Malaya, Kuala Lumpur.

Summary

A case of an adenoid cystic carcinoma of the minor salivary glands of the nasal cavity is reported. The tumour had spread locally, and by perineural spread to the internal auditory meatus, causing facial nerve palsy.

Key words: Adenoid cystic carcinoma, perineural spread, facial nerve palsy.

Introduction

Adenoid cystic carcinoma represents 14.5% of all salivary gland tumours. The minor salivary gland is the most common site of origin of this tumour¹. The nasal cavity and the maxillary sinus are commonly involved². A characteristic feature of this tumour is its perineural and bone spread. Facial nerve palsy occurs in 16% of patients when this tumour occurs in the parotid gland and when this tumour arises from the nasal cavity, the trigeminal nerve is frequently involved^{ref}. However, facial nerve palsy caused by direct tumour extension from the nasal cavity has not been reported.

Case Report.

LSH, a 33 year old Chinese male, presented with a one year history of progressive right sided nasal block with blood stained discharge. He had associated right sided hearing loss and tinnitus with headache. One month prior to admission, he developed an incomplete right sided facial nerve palsy. Examination revealed a right sided lower motor neuron facial nerve palsy. The right nasal cavity was packed with fleshy, friable tumour with contact bleeding. There was tumour extension into the post nasal space. There was also a right middle ear effusion resulting in conductive deafness. There were no cervical lymph nodes palpable the twelfth cranial nerve was also paralysed. The rest of the cranial nerves were intact. The other systems were normal on examination. Schirmer's test done showed decreased lacrimation on the right side there was absent stapedial reflex on the affected side.

A computerised axial tomogram with 5 mm cuts on the axial section up to the level of the oropharynx was done. A huge tumour mass was seen filling up the right nasal cavity and extending into the ethmoid sinus. (Figure 1) There was extension into the sphenoid sinus with erosion at the petrous apex to involve the middle and posterior cranial fossae. There was tumour infiltration at the internal auditory meatus causing expansion of the meatus. A nasal biopsy taken of the tumour proved it to be an adenoid cystic carcinoma. In view of the extensive tumour, the patient was referred for radiotherapy treatment.

Discussion

Adenoid cystic carcinoma is known characteristically for its perineural and bone spread. It is also known to be a radioresponsive but not a radiocurable tumour. For these reasons, the main mode of therapy is wide surgical excision with particular attention to the neural and vascular structures.

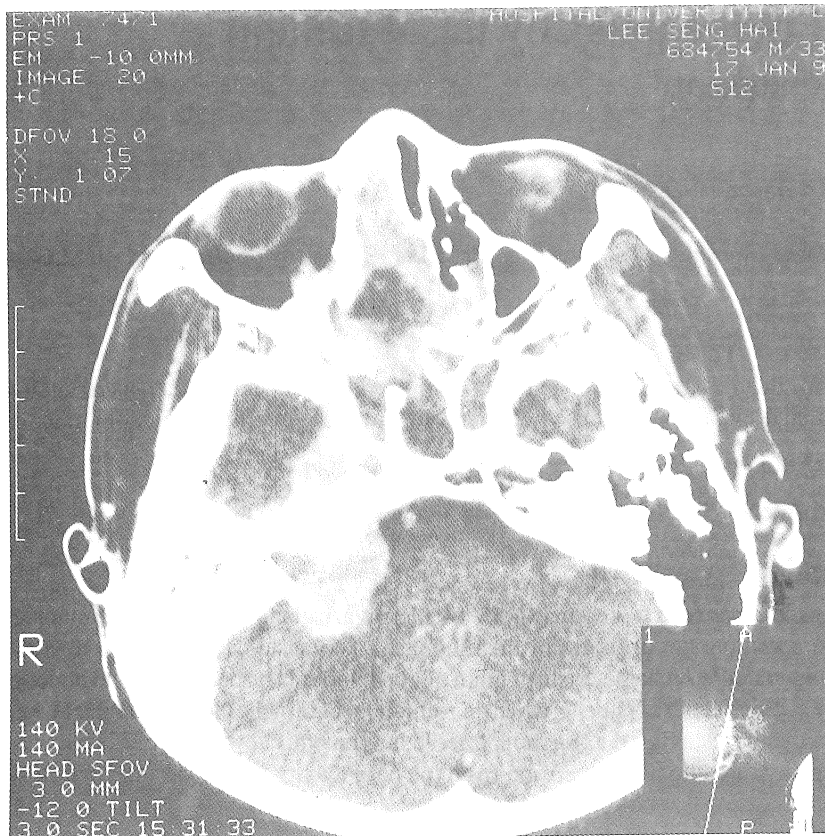


Fig. 1 :: CT Scan shows tumour filling nasal cavity extending into middle and posterior cranial fossa, right side.

Tumours of the nasal cavity and sinue usually have extensive neural involved by extension along the maxillary and mandibular division via the foramen ovale and foramen rotundum up to Grasser's ganglion⁵.

The facial nerve is commonly involved if this tumour arises in the parotid gland. Other nerve palsies have been described when the tumour arises in the oral cavity, pharynx and larynx. However, facial nerve palsy due to direct extension of tumour from the nasal cavity has not yet been reported. In this patient, the tumour arose in the nasal cavity and extended backwards into the post nasal space. It infiltrated into the ethmoid and sphenoid sinus, and then by perineural spread eroded into the petrous bone to involve the middle and posterior middle cranial. The facial nerve was infiltrated by the tumour at the internal auditory meatus. Surprisingly, the trigeminal nerve function is intact in the patient.

The prognosis of patients with adenoid cystic carcinoma has been evaluated in various studies. Prognosis is dependent on the size, site and evidence of perineural involvement. The histologic grading is not of prognostic significance⁶. The nasal cavity, larynx and antrum recorded the lowest survival figures (7% 10 year survival). The prognosis of this patient is obviously poor in view of the site and size of the tumour.

References

1. Nascimento, AG. "Adenoid cystic carcinoma of salivary glands" *Cancer* 1986 57, 312-319.
2. Friedmann, Systemic pathology, vol 1: Nose, Throat and Ear. 1986; 80-81, Churchill Livingstone.
3. Spiro RH: "Adenoid cystic carcinoma of salivary origin". *Am J. surgery.* 1974, 128:512-250.
4. Eby LS, Johnson DS, Baker HW: Adenoid cystic carcinoma of the head and neck. *Cancer* 1972; 29:1160.
5. Thawley SE, Panje WK. *Comprehensive management of Head & Neck tumours.* 1987 vol 1, pg. 333.
6. Spiro RH, "Adenoid cystic carcinoma: Factors Influencing survival". *Am. J Surgery,* 1979 138: 579-583.