

Ascaris in the common bile duct: Diagnosis by Ultrasound and Endoscopic Retrograde Cholangiopancreatography (ERCP) and Extraction by Balloon Catheter

Mahadevan Murugiah. MBBS, FRCS

Consultant Surgeon,

Department of General Surgery, General Hospital Kuala Lumpur,

Abdul Samad Sakijan AM, MBBS, DMRD, FRCR

Associate Professor and Head,

Department of Radiology, Faculty of Medicine, Universiti Kebangsaan Malaysia.

Summary

This is a case report of ascaris worm in the common bile duct in a 61 year old lady. Ultrasound diagnosis was initially made based on the presence of linear hyperreflective foci within the common bile duct. ERCP confirmed a single worm within the duct. Balloon extraction was then successfully carried out following papillotomy. This case illustrates the value of ultrasound in the definitive diagnosis of biliary ascariasis and the therapeutic role of ERCP.

Key words: Ascaris, bile ducts, ultrasound, endoscopic retrograde cholangiopancreatography, balloon extraction.

Introduction

Ultrasound is now the initial imaging modality of choice in the evaluation of patients with clinically suspected hepatobiliary disease. A variety of specific hepatobiliary diagnosis can be made. Encounters with calculi and tumours of the common bile duct are fairly common but biliary ascariasis is relatively uncommon. There are already several reports illustrating the value of ultrasound in the definitive diagnosis of biliary ascariasis.¹⁻³ It is important to appreciate the sonographic appearances of this condition so as not to miss the diagnosis. We report a case of ascaris in the common bile duct initially diagnosed by ultrasound, confirmed by ERCP and endoscopically extracted by balloon catheter.

Case report

AK is a 61 year old Orang Asli lady who was admitted for pain in the right hypochondrium and the epigastric region for one week. She had had similar attacks for several years for which she was hospitalised twice. There was also history of intolerance to fatty foods.

On admission her general condition was satisfactory. She was afebrile and not jaundiced. Her blood pressure was 140/90 mm Hg and pulse 84 per minute. Abnormal clinical findings were confined to the abdomen where there was tenderness and mild guarding of the right hypochondrium and the epigastrium. The liver edge was palpable 2 cm below the costal margin. The clinical diagnosis on admission was acute cholecystitis due to gallstone. The results of the laboratory investigations were;

Hb 13.8 gm%, TWBC 6800/cmm with a differential count of 74% polymorphs, 16% lymphocytes and 10% eosinophils; platelet 220,000/cmm, blood urea nitrogen 4.5 mmol/L; serum creatinine 80 umol/L; sodium 132 mmol/L; potassium 3.8 mmol/L; total protein 6.1 Gm/L; albumin 3.2 Gm/L total bilirubin 14 umol/L, alkaline phosphatase 81; SGPT 19; serum amylase 34 u/L and negative HbsAg. Ultrasonography of the hepatobiliary system showed normal liver parenchyma, intrahepatic ducts and gallbladder but dilated common bile duct with a calibre of 11 mm. Within the common bile duct, short linear hyperechoic areas are seen in the upper and middle parts (Figure 1). Worms were suggested

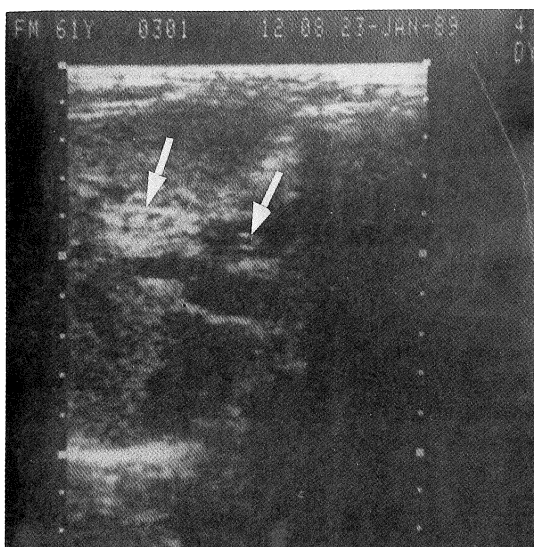


Fig. 1 :
Ultrasound showed parallel linear echogenic strips in a dilated common bile duct (white arrows)

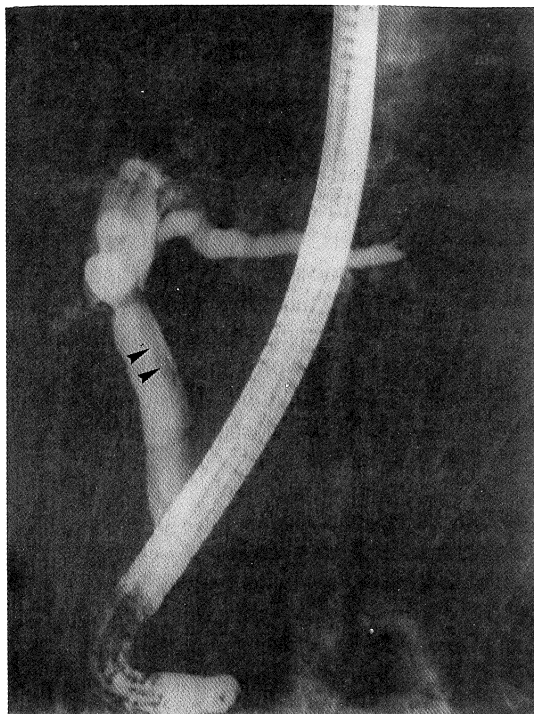


Fig. 2 :
ERCP confirmed the presence of a single ascaris within the dilated common bile duct, seen as a long linear filling defect (black arrowheads)

based on these findings. ERCP done subsequently revealed a single long linear filling defect within the entire length of the common bile duct consistent with ascariasis (Figure 2). Following papillotomy the worm was successfully extracted (Figure 3) using a 200 cm long, Fr 4.8 Wilson Cook balloon stone extractor. No significant complication occurred following the procedure and the patient was discharged well 3 days later.

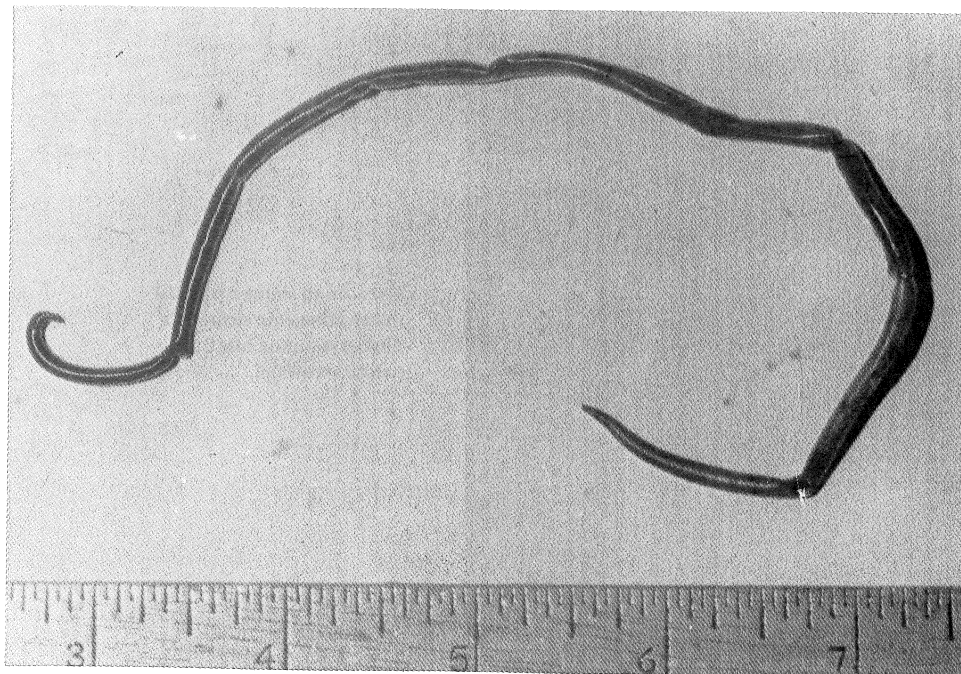


Fig. 3 : A 10 cm long, bile-stained ascariasis worm.

Discussion

Ultrasound and ERCP are well established imaging methods to diagnose biliary ascariasis.¹⁻³ Ultrasound offers a rapid, safe and noninvasive approach to diagnosis. The sonographic appearances of worms in the biliary system have been described as long echogenic strips, either linear or curved, single or multiple, with or without a central longitudinal anechoic tube, mostly without acoustic shadowing.¹⁻³ Multiple worms along the length of the common bile duct give rise to a 'spaghetti-like' appearance with alternating echogenic and echolucent strips, whereas worm in the dilated common bile duct in transverse section may give rise to 'bull's-eye' echopattern.² Realtime ultrasonography may demonstrate the characteristic sinuous motility of the worms in the bile ducts, thus confirming the diagnosis unequivocally.²

Sonographic diagnosis of biliary ascariasis is not without problems. False echoes may arise from a number of circumstances. Vague echoes may be seen in the common bile duct due to reverberations from more anterior tissue interfaces. These echoes are, however, not so well defined or so longitudinally continuous as the strips of ascariasis.¹ Angulated common bile duct together with the proper hepatic artery and adjacent tissue interfaces going and out of scanning plane view may simulate the longitudinal strips or 'spaghetti' sign.¹ False negative diagnosis occurs when the echogenic strips

are not recognised within a common bile duct which is not dilated or the common bile duct lumen is invisible due to its replacement by the 'spaghetti' appearance. To minimise false diagnosis, meticulous scanning to identify the course and branching of the relevant tubular structures should always be carried out. Where the ultrasound diagnosis is unequivocal no further radiological examination is necessary. ERCP is warranted, however, when the ultrasound is technically inadequate, diagnostically equivocal or apparently normal in the presence of clinical features pointing to a colicky origin.² Sonography, as well as confirming the diagnosis can also be used as a noninvasive and quicker means to follow up cases to determine success of medical treatment.²

Ascaris invasion into the bile duct may cause biliary colic, pyogenic cholangitis, pancreatitis and septicemia.² The majority of patients with biliary ascariasis are amenable to conservative treatment.⁴ This includes treatment of cholangitis and effect paralysis of worms in the intestines by oral administration of antihelminthic agents from whence they will be expelled by effective peristaltic activity of the intestines.⁴ Spontaneous exit of worms from the bile ducts can be monitored by ultrasonography. Surgery is indicated in three situations, namely; a) worms continue to persist inside the biliary tree for more than 1 month, as by that time they are likely to die and thus be unable to migrate out of the biliary tree, b) the biliary tree contains dead worms, or c) worms inside the biliary tract coexist with stones.

Therapeutic manouevres during ERCP can also be carried out, as in this case, where the ascaris was successfully extracted with the use of balloon catheter. This endoscopic approach will spare the patient from the risks of surgery and general anaesthesia and shortening the duration of hospital stay. The other therapeutic potential of ERCP is direct instillation of piperazine citrate through a nasobiliary drainage catheter and when nasobiliary drainage is required.²

Acknowledgement

We wish to express our appreciation to the Microbiology Department, General Hospital Kuala Lumpur, and Illustration Unit, Faculty of Medicine, Universiti Kebangsaan Malaysia.

References

1. Schulman A, Coxton AJ, Heydenrych JJ and abdurahman KE. Sonographic diagnosis of biliary ascariasis. *Am J Roentgenol* 1982; 139: 485 - 489.
2. Kamath PS, Joseph DC, Chandran R, Rao SR, Prakash S and D' Cruz AJ. Biliary ascariasis: Ultrasonography, endoscopic retrograde cholangiopancreatography and biliary drainage. *Gastroenterology* 1986; 91:730-732.
3. Khuroo MS, Zargar SA, Mahajan R, Bhat RL, and Javid G. Sonographic appearances in biliary ascariasis. *Gastroenterology* 1987; 93:267-272.
4. Zargar SA, Khuroo MS. Treatment of biliary ascariasis and its rationale (letter to editor). *Gastroenterology* 1987;93:668.