

# Delayed complication of a foreign body causing retropharyngeal granuloma — a case report

Lee Teck Soong, Stephen, MBBS, FRCS

*Lecturer*

*Department of Otorhinolaryngology, Faculty of Medicine,  
University of Malaya, 59100 Kuala Lumpur.*

## Summary

A 37 year old female who presented with a history of foreign body ingestion ten months previously was found on examination to have a retropharyngeal swelling. An initial differential of foreign body granuloma or retropharyngeal tuberculous abscess was considered. The usefulness of the lateral neck radiograph in demonstrating retropharyngeal pathology and the supplementary role of the computed tomography scan in confirming and elucidating the identity of the radio-opacity is highlighted. This presentation is a timely reminder of the need for a simple inexpensive lateral neck radiograph in situations of doubt as to persisting foreign body impaction.

*Key words:* Foreign bodies, pharynx, radiography

## Introduction

A satisfactory outcome is the norm with early presentation of swallowed foreign bodies. However difficulties arise when there is delay in seeking medical attention or if the foreign body remains undiagnosed. This presentation highlights an unusual delayed complication in the latter situation.

## Case Report

A 37 year old female presented with a complaint of having swallowed a fish bone ten months previously. She saw a general practitioner then and was told that no bone was present. Her throat pain lasted two weeks before gradually subsiding. Since then, she complained intermittently of a throat discomfort for which she was regularly prescribed gargles and lozenges. She remained as such till the last month when she experienced severe pain and a foreign body sensation over the throat. There was no fever, dysphagia, stridor, voice change or any history of contact with tuberculosis.

As her symptoms worsened despite three course of antibiotics prescribed by several general practitioners, she consulted a private surgeon. Following radiological investigations, she was referred to the University Hospital Kuala Lumpur. At examination, a smooth diffuse bulge of the right posterior oro- and hypo-pharyngeal wall was seen. No foreign body was visualised, the cervical spine was normal with full range of movement and the remainder of the examination was normal. The white blood count was 13,000 with a differential of neutrophils 80%, eosinophils 3%, lymphocytes 10% and monocytes 7%. Lateral radiograph of the cervical spine confirmed a grossly widened retropharyngeal space with a barely visible opacity overlying

the second and third cervical vertebra (Figure 1). A transverse computed tomography scan of the neck confirmed this opacity to be due to a retropharyngeal foreign body with no evidence of abscess formation (Figure 2). Following endotracheal intubation under general anaesthesia, a Boyle Davis mouth gag was inserted and a linear vertical incision was centred on the right posterior oropharyngeal wall. No pus was encountered. Following elevation of mucosal flaps, granulation tissue was found overlying a deep seated two centimetre long fish bone bordering

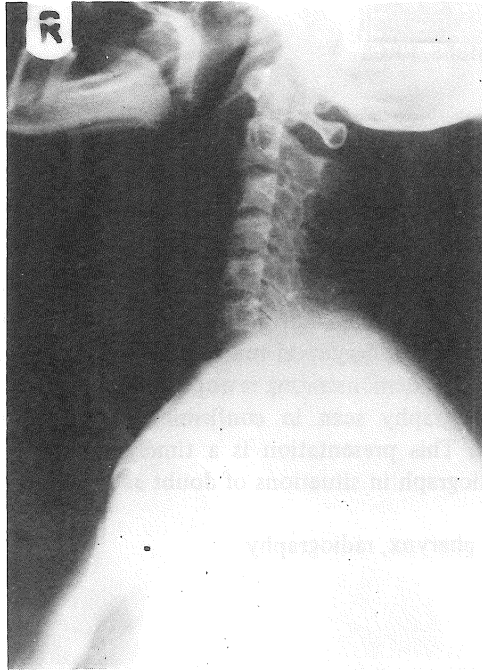


Figure 1. Lateral cervical radiograph illustrating grossly thickened retropharyngeal space opposite second to sixth cervical bodies with a barely visible opacity overlying the third cervical vertebra.

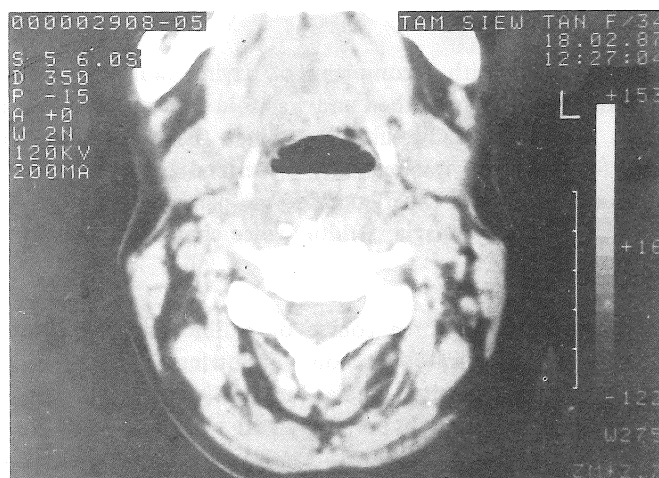


Figure 2. Transverse section of computed tomography scan at level of third cervical vertebra illustrating foreign body opacity in the right retropharyngeal space.

the body of the third cervical vertebra. The bone was removed and mucosal flaps closed. Perioperatively intravenous metronidazole 500 mg and gentamycin 80 mg eight hourly was started and continued for five days. Nasogastric feeding was instituted and the nasogastric tube was removed at the sixth postoperative day. Histopathological examination of the granulation tissue was consistent with non-specific chronic inflammatory changes and was negative for acid fast bacilli. At three months follow-up, she was completely asymptomatic with absence of any oropharyngeal swelling.

## Discussion

Retained foreign bodies in the pharynx and esophagus are known to cause serious complications as varied as retropharyngeal cellulitis or abscess, retropharyngeal haematoma, foreign body obstruction, esophageal perforation, mediastinitis, lung abscess, oesophago-aortic fistula and even upper airway obstruction particularly in children. However these complications inevitably present within the first week of foreign body ingestion. In a large series of 2,394 patients with upper gastrointestinal foreign bodies, there were 46 complications and none of these presented later than six days after impaction.<sup>1</sup>

Our patient is unusual in that the fish bone impacted in the retropharyngeal space but did not result in the usual complication of a retropharyngeal abscess. Instead the findings at operation were consistent with that of a foreign body granuloma with surrounding retropharyngeal cellulitis. This may be a result of modification of the inflammatory response due to masking by the multiple courses of antibiotics.

It is worth noting that in adults, retropharyngeal space abscess is uncommon and nearly always due to tuberculous disease of the cervical spine which has spread through the anterior longitudinal ligament of the spine to reach the retropharyngeal space.<sup>2</sup> However the clinical picture, presence of a foreign body and absence of cervical vertebra destruction radiologically excludes this diagnosis.

In the evaluation for potential foreign bodies or retropharyngeal space pathology, the lateral neck radiograph is a most useful diagnostic aid. Radiopaque foreign bodies can be visualised though care must be taken not to confuse with calcified laryngeal cartilages, calcified stylohyoid ligament or calcified anterior longitudinal ligament. An assessment that the retropharyngeal space thickness is abnormal depends on knowledge of normal dimensions. Wholey et al<sup>3</sup> reviewed six hundred normal lateral neck radiographs and concluded that the average sagittal measurement of the adult retropharyngeal space, as measured from the anteroinferior aspect of the second cervical vertebra to the posterior wall of the pharynx was 3.4 mm (range 1 to 7 mm). At the lower cervical level, the average retrotracheal space, measured from the anteroinferior aspect of the sixth cervical vertebra to the posterior aspect of the trachea was 14mm (range 9 to 22 mm). In general, a retropharyngeal soft-tissue shadow greater than the width of the cervical spine points to a pathologic process in the retropharyngeal space.

Computed tomography is of course not needed in most diagnostic situations of possible foreign body ingestion. However if doubt exists, it is certainly true that notwithstanding the recently available magnetic resonance imagers, the computed tomography scan is an excellent and probably the best radiological modality available in the evaluation of ingested foreign bodies. Precise preoperative confirmation and localisation of the foreign body as demonstrated in a report by Muhanna et al<sup>4</sup> was similarly achieved in this case.

This presentation serves a dual reminder that although throat symptoms persisting beyond one or two weeks are not generally ascribed to persistent foreign body impaction, it is wise to consider the possibility; and that performance of the simple lateral neck radiograph in such situations could have easily suggested the true diagnosis and prevented an unnecessary complication with its attendant morbidity.

## References

1. Nandi P, Ong GB. Foreign body in the oesophagus; review of 2394 cases. *Br J Surg* 1978; 65: 5-9.
2. Hibbert J. Acute infection of the pharynx and tonsils. In: Kerr AG, Stell PM (eds). *Scott-Brown's Otolaryngology. Laryngology Fifth Edition*. London: Butterworths, 1987: 76-98.
3. Wholey MH, Bruwer AJ, Baker HL, Jr. The lateral roentgenogram of the neck. *Radiology* 1958; 71: 350 - 356.
4. Muhanna AA, Abuchra KA, Dashti H, Behbehani A, Naqeeb A. Thyroid lobectomy for removal of a fish bone. *J Laryngol Otol* 1990; 104: 511- 512.