

Xanthogranulomatous pyelonephritis a report of two cases

Jasmi Ali Yaakub, MBChB (Cairo)

Trainee Lecturer

Md. Mahir Abdullah, MBBS (Qld), FRCSE

Lecturer

*Division of Urology, Department of Surgery,
Faculty of Medicine, Universiti Kebangsaan Malaysia, Kuala Lumpur.*

Summary

Xanthogranulomatous pyelonephritis is a rare form of chronic pyelonephritis affecting adults and children. Two patients with the disease are reported.

Key words: Xanthogranulomatous pyelonephritis, chronic pyelonephritis.

Introduction

Xanthogranulomatous pyelonephritis (XGP) is an atypical form of chronic renal infection which is characterised by destruction of the renal parenchyma and replacement by granulomatous tissue containing lipid laden macrophages.

Since its original description by Schlagenhauser in 1916,¹ there has been an increased awareness of this clinical entity and more than 400 cases have been reported in the literature. It is common in women in the 40–60 years age group and is a rare disease in children. An accurate preoperative diagnosis of XGP is difficult because of its clinical and radiological similarities to various other renal diseases. Definitive diagnosis is usually made only on histological examination.

We report a child and an adult with XGP in which the diagnoses were made histologically following nephrectomies.

Case Reports

Case No. 1: A two and a half year old Malay female child was referred from the General Hospital of Ipoh for recurrent fever with urinary tract infection of one year duration. An intravenous pyelogram formed there reported a non functioning left kidney with compensatory hypertrophy of the right kidney.

On admission to our unit, the child was found to be essentially normal, afebrile with no masses felt per abdomen. Her initial urine examination was normal and culture was negative. Renal profile studies were normal. A micturition cystogram revealed a grade 1 left vesico-ureteric reflux without left ureteric dilatation. The left pelvicalyceal system was not demonstrated. A DPTA scan showed a non functioning left kidney with a glomerular filtration rate of only 1.6 ml/min.

(Normal: 125 ml/min). Ultrasonography showed a large uniformly transonic cystic lesion in the left kidney. A diagnosis of a left congenital hydronephrosis was made and a left nephrectomy was planned. However, pre-operatively she developed fever and left loin pain. There were pus cells in her urine and culture showed a heavy mixed bacterial growth. Her white blood cell count was raised. She was started on Cephalexin and Netilmicin. The fever subsided and a left nephrectomy was carried out. The left kidney was found to be adherent to surrounding structures, firm and full of pus from which *E. coli* were isolated. The lymph nodes were found to be enlarged. Post-operatively the patient recovered.

Histopathologically, the kidney showed aggregates of foamy macrophages with scattered foreign body giant cells. Cholesterol clefts were noted. (Fig. 1). The findings were consistent with xanthogranulomatous pyelonephritis.

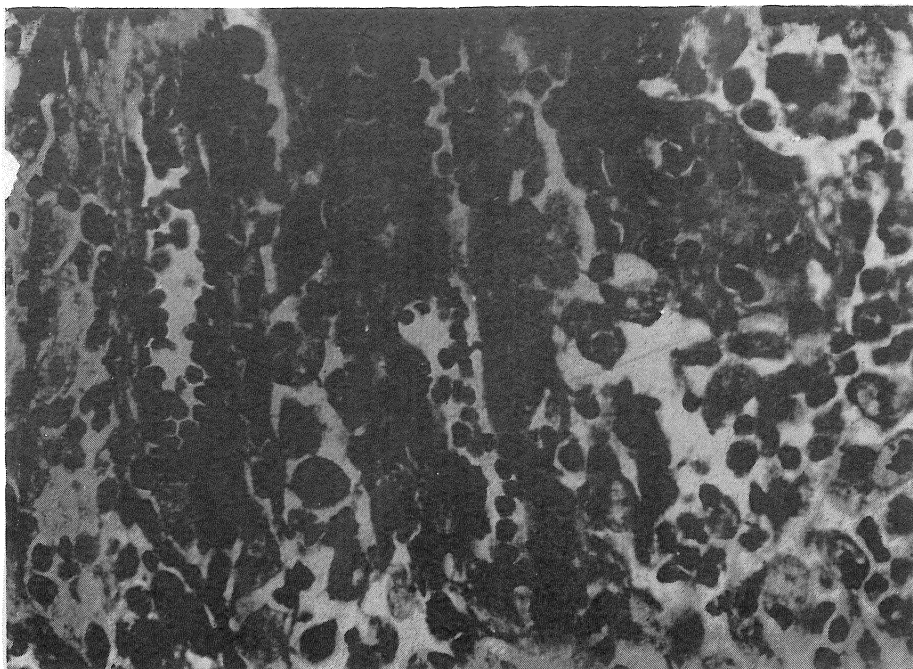


Figure 1: Histopathological examination showing foamy macrophages and foreign body giant cells (magnification x400).

Case No. 2: A 53 year old Chinese lady, a known diabetic for ten years, was admitted to the Seremban General Hospital in November 1988 because of one week duration of fever and chills accompanied by right lumbar pain. There was no haematuria. Examination revealed a tender ballotable mass in the right lumbar region measuring 7x8 cm. An intravenous pyelogram showed a large mass occupying the lower pole of the right kidney with distorted pelvicalyceal system. Her blood urea was 12.1 mmol/L (Normal: 3.6–9.3 mmol/L) and serum creatinine was 178 μ mol/L (Normal: 62–124 μ mol/L). Urine culture grew *Klebsiella* which was sensitive to Cefoperazone. The antibiotic was started and she was referred to our unit.

An ultrasonography performed showed a large echogenic mass measuring 7x7.5 cm at the posteromedial aspect of the lower pole of the right kidney containing areas of calcification.

A CT scan showed a predominantly cystic mass with possible infiltration into the psoas muscle and Gerota's fascia. No paraaortic lymph nodes were seen and the inferior vena cava was patent. A diagnosis of a right renal cell carcinoma was made and radical nephrectomy planned.

The right kidney was approach through a supra 12th rib incision and was found to be enlarged and adherent to the diaphragm and peritoneum. Pockets of pus were noted in the upper pole. The tumour was in the lower pole encroaching onto the capsule with distortion of the pelvicalyceal system. There were no enlarged lymph nodes. A radical nephrectomy was performed. She recovered after the operation.

Histological examination showed similar features of Xanthogranulomatous pyelonephritis (Fig. 2) as in case 1.

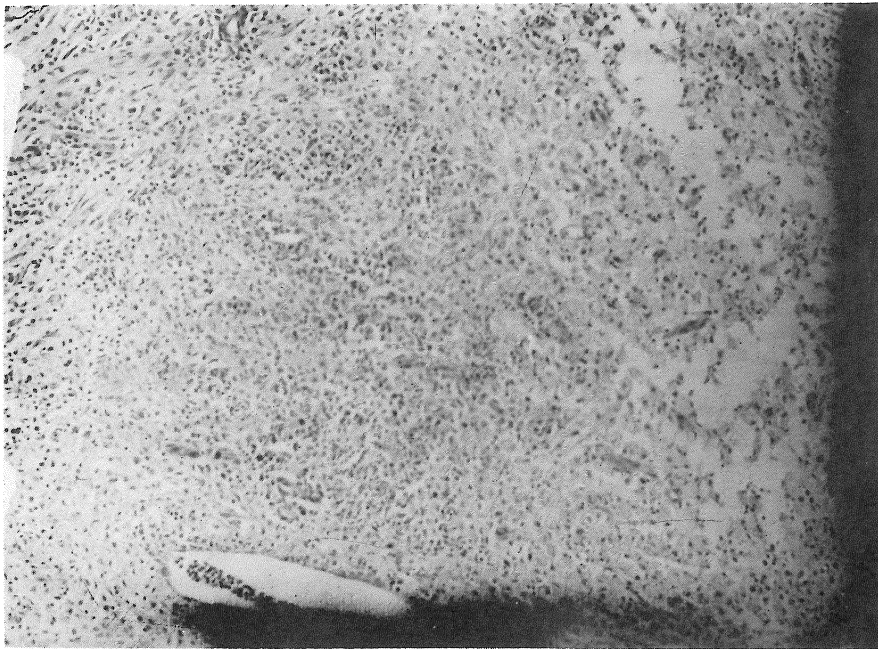


Figure 2: Histopathological examination showing XGP (x100)

Discussion

XGP has been described from all parts of the world, either as isolated case reports or small series of cases. Although the aetiology is unknown, it is almost always associated with both infection and obstruction of the urinary tract which appear to predispose the development of the disease.

In the case of the child presented here, she could have had a left congenital hydronephrosis complicated by pyelonephritis which then led to the development of XGP. In the second case however, apart from being a diabetic, no local factor was detected in the right kidney to explain its predisposition to the disease.

Clinically, XGP presents as a combination of flank pain, flank mass, urinary tract infection, malnutrition, general malaise, weight loss and fever or chills or both. As such, it was called a 'great

imitator' by Malek² and often misdiagnosed as a renal tumour. Positive urine cultures are seen in 70% of cases of which the most frequently encountered organism is *E. coli* followed by *Proteus mirabilis*.³ The presence of urinary tract infection may help to distinguish XGP from renal cell carcinoma which rarely gives positive urine cultures.

The appearance of foam cells in the urine has been suggested as a means of identifying patients with XGP by Ballesteros et al.⁴ He reported an accurate preoperative diagnosis of XGP by serial urine cytology in 80% of his cases.⁴ In Rifat's series⁴ of seven children with XGP, all had erythrocyte sedimentation rates (ESR) of 100 mm/hr or above and this has been suggested as a significant diagnostic parameter.

Radiological studies may show a poorly functioning or non functioning kidney with or without renal calculi. The intravenous pyelogram may help to differentiate between diffuse lesions, where the involved kidney is functionless, from segmental (focal) lesions, where renal function is preserved with the existence of a space occupying lesion. Ultrasonography and computerised scanning may contribute to the suggestion of XGP but are in general non specific.⁶

Management of diffuse XGP is surgical removal of the involved kidney in most cases. When focal or segmental disease is apparent, partial nephrectomy may be considered particularly in patients with a solitary kidney. In both instances the difficulty in rendering medical treatment lies in the inherent difficulty in establishing the correct preoperative diagnosis. An association between renal cell carcinoma and XGP has been reported but not between Wilm's tumour and XGP. At operation, complete removal of the inflammatory tissue is important to prevent complications related to continued infection and granulomatous destruction.

A few patients with focal XGP can be treated with long term antibiotics after excluding inflammatory and neoplastic diseases that XGP mimics.

Conclusion

XGP is an increasingly recognised entity in both children and adults. Studies showed little difference between XGP in adults and in children. The symptoms, findings and clinical course of the disease were similar in both. XGP should be included in the differential diagnosis of renal enlargement or non functioning kidneys associated with renal calculi and chronic urinary tract infection. Preoperative diagnosis is difficult and it would appear that surgery remains the mainstay of therapy, with antibiotic therapy serving a supportive role in most cases.

References

1. Abbate D, Meyers J. Xanthogranulomatous pyelonephritis in childhood. *J Urology* 1976; 116: 231-233.
2. Malek RS. Xanthogranulomatous pyelonephritis: a great imitator. *Urol Digest* 1978, 17:17.
3. Elder JS & Vaughan ED. Xanthogranulomatous pyelonephritis: The great imitator. *Infect Surgery* 1984; 3: 145-158.
4. Ballesteros JJ, Faus R & Gironella J. Preoperative diagnosis of renal xanthogranulomatous pyelonephritis by serial urine cytology: A preliminary report. *J Urology* 1980; 124: 9-10.
5. Rifat UN & Al-Kadi SA. Xanthogranulomatous pyelonephritis in childhood. *JR Coll Surg Edinburgh*, 1988; 33: 253-254.
6. Hartman DS. Radiologic pathologic correlation of the infectious granulomatous diseases of the kidney. *Urology* 1985. 6: 3-43.