

## LETTER TO THE EDITOR

### FATAL STEVEN JOHNSON SYNDROME IN A CHILD

Sir,

I wish to report a rare and potentially fatal complication related to antibiotic therapy.

A nine year old Chinese girl was taken to a general practitioner for pustules. Five types of medication including Ampicillin and Cloxacillin were prescribed. Nine days after she consulted the same doctor for sore throat and ulcer in the mouth. She was given the same antibiotics. She subsequently developed fever and a generalised rash.

On examination she was ill, febrile with a hoarse voice and a stridor. There was a generalised papular erythematous rash with bullae and target lesions. The conjunctiva was injected and skin over the lips was cracking.

A clinical diagnosis of Steven Johnson syndrome was made. She was admitted to an isolation room and given a high calorie and protein diet. She was nursed in sterile draps (as for burns). Methyl cellulose drops and chloramphenicol ointment were applied to the eyes. Intravenous hydrocortisone was given and this was later replaced by oral prednisolone.

The skin loss progressed to involve about 60% of the body surface area including perineum (Figure 1). She was given intravenous fluids, blood transfusions and fed by nasogastric tube. On the 17th hospital she died of streptococcus viridans septicaemia.

#### Comment

Steven Johnson syndrome is a rare complication related to drug therapy and may be fatal as in this case. Doctors should use drugs cautiously and only if definitely indicated. In the event of any drug reaction, the Adverse Drug Reaction Monitoring Centre, Ministry of Health, Petaling Jaya should be notified using specific forms. All information provided is strictly confidential. Notification is essential to study the epidemiology of adverse drug reactions.

Dr R. Krishnan, Lecturer, Department of Paediatrics, Faculty of Medicine, University of Malaya, 59100 Kuala Lumpur.

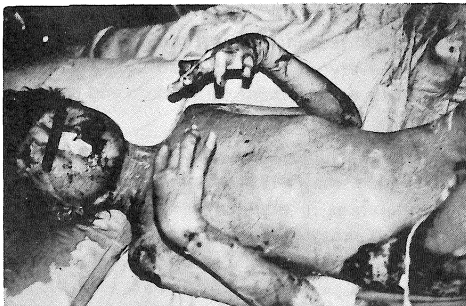


Fig. 1 Extensive skin loss in Steven Johnson syndrome