

# Dilated ureter presenting as a cystic abdominal mass — a case report

Vimala Rathakrishnan, MBBS, FRCR  
*Lecturer*

*Department of Radiology, Faculty of Medicine,  
University of Malaya, Kuala Lumpur.*

## Summary

A seven-month-old female child presenting with a large abdominal mass was found on investigation to have a duplex right kidney with a non-functioning obstructed upper moiety and a right ureterocele. The grossly dilated and tortuous upper moiety ureter presented as a large cystic mass on ultrasound and computed tomographic scans.

*Key words:* Abdominal mass, cystic duplex kidney.

## Case Report

A seven-month-old female child was admitted to the hospital with a two-day history of fever and abdominal mass. Antenatal ultrasound of the patient's mother at 36 weeks of pregnancy had revealed mild hydronephrosis of the right foetal kidney. This was confirmed by ultrasonic examination during the neonatal period. A DTPA scan which followed showed functional obstruction on the right side with good washout following intravenous lasix. The child was apparently well until admission.

Physical examination revealed a large well defined, mainly right-sided abdominal mass extending into the pelvis and across the abdomen. It was separate from the right kidney which was ballotable. An intravenous urogram (Fig. 1) showed the well recognised features of an obstructed, non-functioning upper moiety in a duplex right kidney. The left kidney also showed complete duplication. Ultrasonic examination of the abdomen showed a large septated cystic abdominal mass extending into the pelvis. It also demonstrated asymmetrical upper pole hydronephrosis in the right kidney and a dilated proximal ureter. A CT scan (Fig. 2) demonstrated a large cystic abdominal mass extending down to the pelvis and displacing the bladder anteriorly. There was a cystic mass in the upper pole of the right kidney which was thought to be a non-functioning obstructed upper moiety and the cystic septated structure medial to the right kidney was considered to be the dilated proximal upper moiety ureter. The lower pole calyces were dilated. At preoperative cystoscopy, two normally sited ureteral orifices on each side and a right ureterocele were noted.

A preoperative diagnosis of a right duplex kidney with an obstructed non-functioning upper moiety and a massively dilated and tortuous upper moiety ureter with a simple right ureterocele was made.

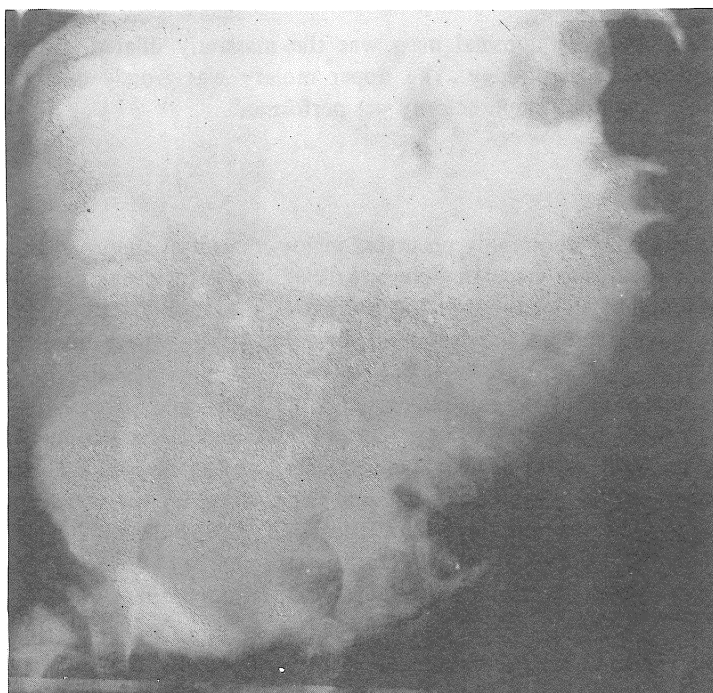


Fig. 1: Intravenous urogram showing a non-functioning upper moiety in a hydronephrotic duplex right kidney.

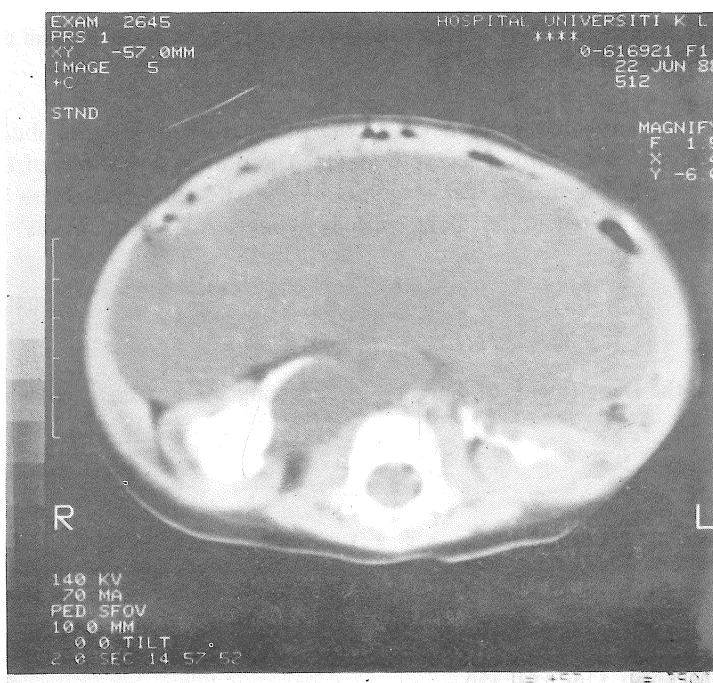

Fig. 2: Computed tomography of the abdomen showing a large cystic abdominal mass and a hydronephrotic right kidney.

At operation, the large cystic abdominal mass was the massively dilated and tortuous upper moiety ureter of a duplex right kidney. The upper moiety was grossly dilated with thinned parenchyma and a right upper pole nephrectomy was performed.

## Discussion

Renal duplication is the most commonly occurring major congenital abnormality in the urinary tract.<sup>1</sup> The three most significant associated abnormalities are (1) maldeveloped valve mechanism at the ureterovesical junction, (b) ectopic ureteral orifice and (c) ureterocele. These abnormalities may lead to progressive renal damage which may be prevented by early diagnosis.

The most common cause of an upper pole renal mass in children is an obstructed non-functioning upper pole collecting system in a duplex kidney.<sup>2</sup> The IVU features of an obstructed upper moiety in a duplex kidney are well known. These include lateral and downward displacement of the kidney, fewer numbers of calyces than usual and lack of a typical upper pole complex. Ultrasound offers a non-invasive means of confirmation, independent of renal function by excluding extrarenal causes for a displaced collecting system and demonstrating the asymmetrical upper pole hydronephrosis and a normal lower pole calyceal echo pattern.

In children, most ureteroceles are congenital. Thirty-three per cent of ureteroceles are associated with complete duplication and nearly all occur in the ureter of the upper moiety.<sup>1</sup> Ureteroceles can be subdivided into (i) simple – associated with a normally sited ureteral orifice, (ii) ectopic intravesical, (iii) ectopic extravesical. Significant dilation of the collecting system and back pressure atrophy, infection and impaired function can occur in the involved moiety due to the obstruction associated with a ureterocele. The ureterocele is usually obvious at urography but may be missed if filmed in the empty state. Ultrasound may show a cystic mass adjacent to the bladder and the differential diagnosis of such a non specific finding includes ovarian cyst, bladder diverticulum, hydrosalpinx and ureterocele.<sup>2</sup>

Nussbaum et al<sup>3</sup> reported five babies in their series who presented with a cystic abdominal mass formed by a grossly dilated and tortuous ectopic ureter. The proximal portions of these dilated ureters may be quite small. The differential diagnosis of a cystic abdominal mass in an infant should therefore include a dilated ureter along with lymphangioma, cystic Wilms' tumour and teratoma.

## Acknowledgements

I would like to thank the Department of Surgery for allowing me access to the clinical notes.

## References

1. Hartman GW, Hodson CJ: The duplex kidney and related abnormalities. *Clin Radiol* 1969; 20: 387–400.
2. Mascatello VJ, Smith EH, Carrera GF, et al: Ultrasonic evaluation of the obstructed duplex kidney. *AJR* 1977; 129: 113–120.
3. Nussbaum AR, Dorat JP, Jeffs RD, et al: Ectopic ureter and ureterocele: Their varied sonographic manifestations. *Radiology* 1986; 159: 227–235.