

# Anterior sacral meningocele

D Samuel, MBBS, DMRD

Lecturer

M. Puvaneswary, MBBS, FRCR

Lecturer

*Department of Radiology*

*Faculty of Medicine*

*Universiti of Malaya,*

*59100 Kuala Lumpur.*

## Summary

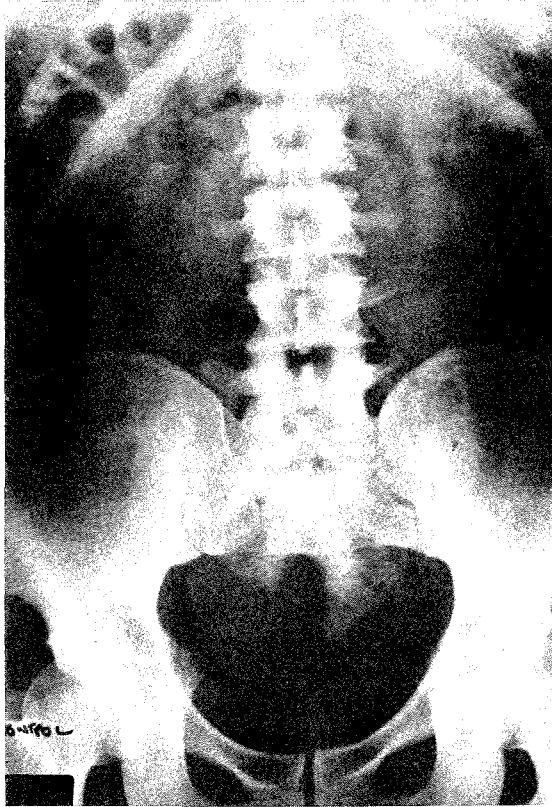
Anterior sacral meningocele is a rare congenital meningeal cyst herniating through a bony defect in the sacrum. Since its description by Bryant in 1837, only 154 cases have been reported in the world literature. The application of ultrasound and C.T. scan following myelography is discussed.

*Key words:* Meningocele, sacrum and presacral, low back ache, pelvis mass, ultrasound, myelogram, computerised tomogram.

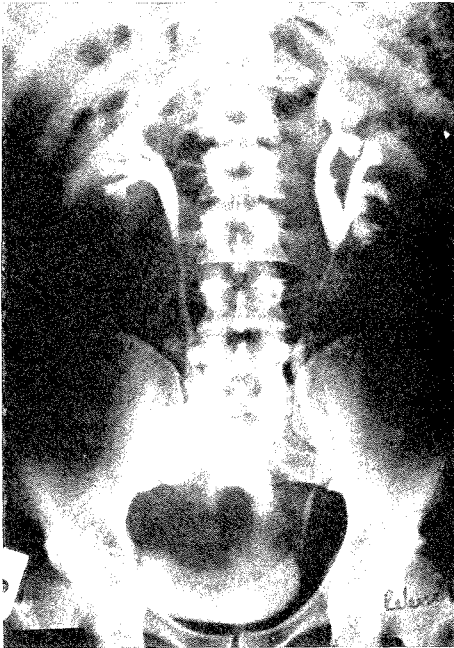
## Case report

A 24 year old man presented to the hospital in May, 1984 with low backache on staying in one position for sometime. The pain was dull in nature and disappeared with change of posture. There was some feeling of fullness in the pelvis. There was no change in bowel habits or neurological deficit. In October, 1983 he presented with frequency of micturition, nocturia and occasional haematuria and vague pain in the left renal angle. Urine analysis revealed rbc 72/ul, wbc 28/ul, cast and crystals negative; protein and sugar nil; urine culture grew *Klebsiella Aerogenes*. Hb 15.6mg%, pcv 45%, wbc 7,800/ul, ESR 2mm/hr, blood urea 6.3mmol/L, serum creatinine 11mmol/L, serum electrolytes were normal. Intravenous pyelogram revealed left renal calculi, and a scimitar defect of the sacrum and a presacral mass. He had pyelolithotomy for his left renal calculi in February, 1984. On present admission, in May, 1984, general physical examination revealed a vague mass and rectal examination detected a soft presacral mass posterior to the rectum. Examination of the central nervous system was normal. CSF obtained by lumbar puncture at the time of myelography revealed normal protein and sugar and was negative for culture. A roentgenogram of the abdomen demonstrated sacral scimitar sign of anterior sacral meningocele (Figure 1). Intravenous pyelogram demonstrated normal upper collecting system but marked distortion and anterosuperior displacement of the bladder (Figure 2a and b). Pelvic ultrasonography revealed a single large cystic mass occupying most of the pelvis and displacing the bladder anterosuperiorly (Figure 3).

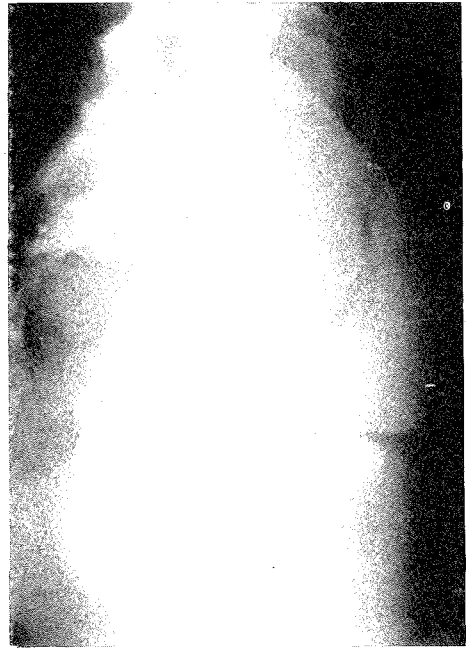
Metrizamine myelography demonstrated a narrow lumbar thecal sac, with contrast media entering just above the bony sacral defect into a large pelvic cyst through a 4mm wide opening (Figure 4). Computed tomography of the abdomen and lumbosacral spine following myelography, demonstrated a large round presacral mass which filled with contrast media. Mass was connected to the bony sacral defect posteriorly and displaced the urinary bladder anteriorly (Figure 5).



**Fig. 1** Anterior sacral meningocele



**Fig. 2A** Anterior sacral meningocele



**Fig. 2B** Anterior sacral meningocele

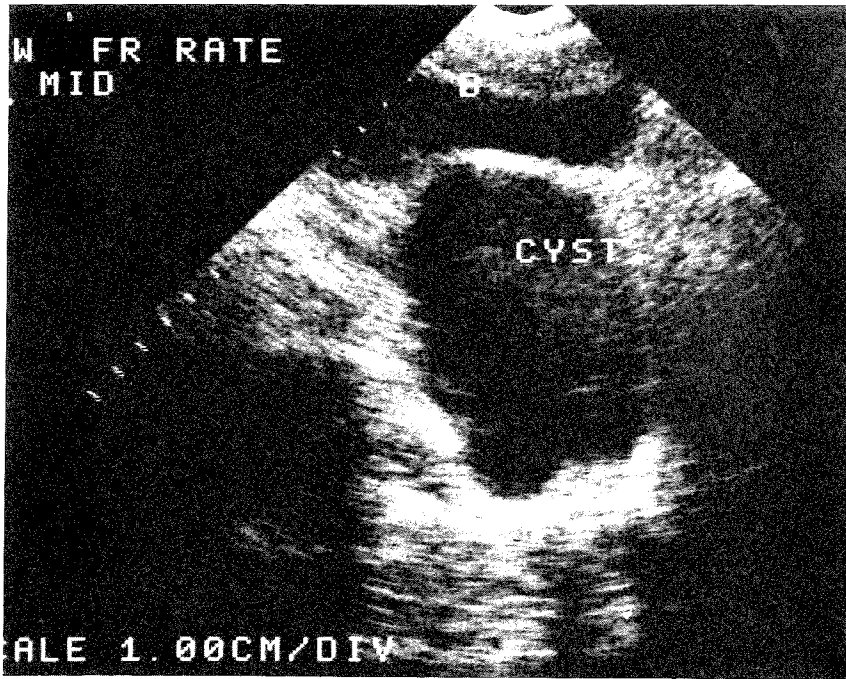


Fig. 3 Anterior sacral meningocele

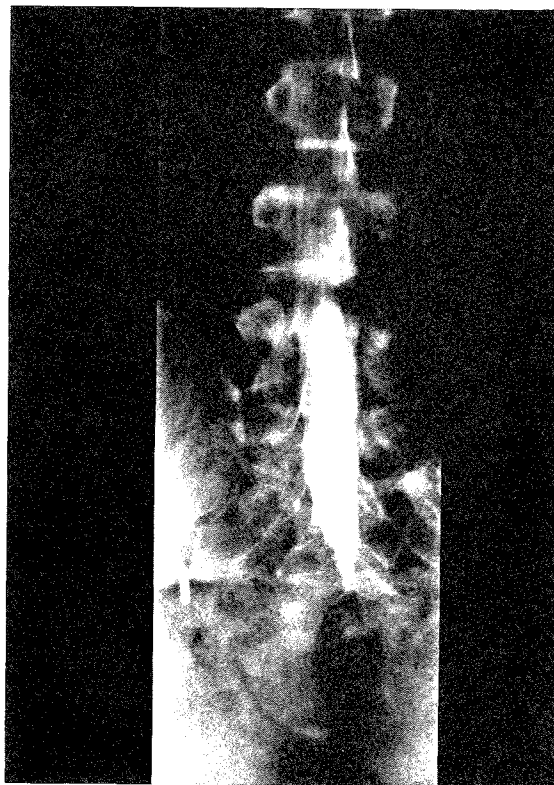
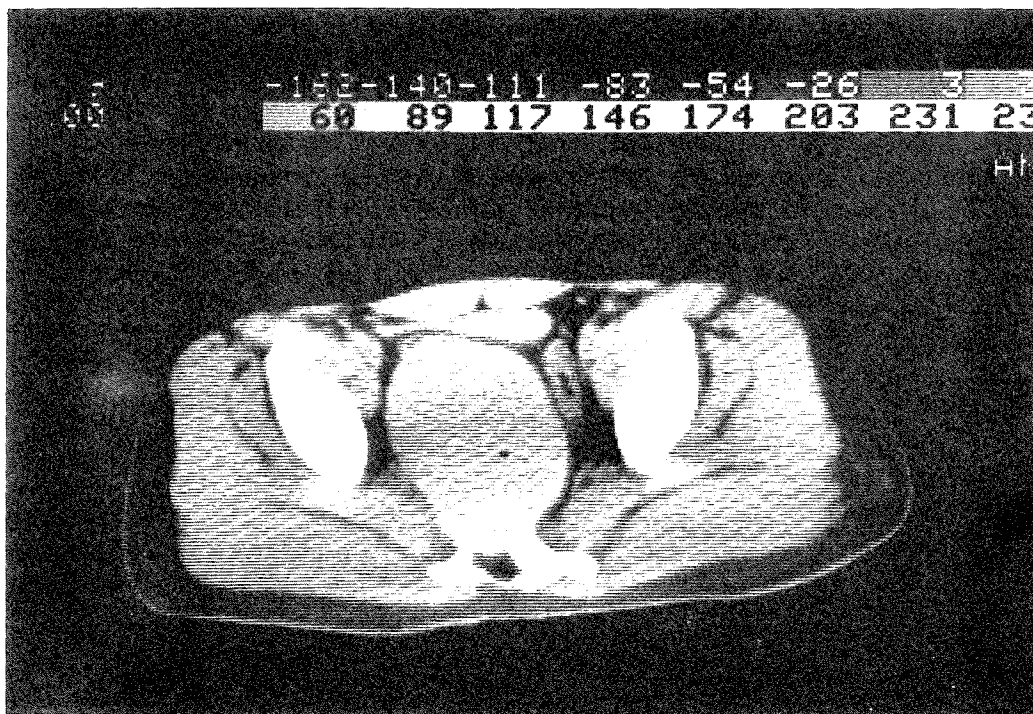


Fig. 4 Anterior sacral meningocele



**Fig. 5 Anterior sacral meningocele**

A diagnosis of anterior sacral meningocele was made. The patient was advised surgical excision of anterior meningocele which he refused.

### Discussion

Anterior sacral meningocele is a rare congenital lesion with marked preponderance in the adult female population. Males are often asymptomatic. It was first described by Bryant in 1837.

Anterior sacral meningocele is a herniation of the dura through a bony defect in the anterior surface of the sacrum. This anomaly is often associated with other congenital abnormalities and tumours eg. imperforate anus, anal stenosis, duplication of uterus and dermoid.<sup>1,2,8</sup> It may be associated with acquired conditions such as Marfan's syndrome and neurofibromatosis when herniation occurs through a widened sacral foramina.<sup>1</sup> Anterior sacral meningocele may remain asymptomatic until adult life, when they may present with pressure effects on the rectum or bladder with constipation, dystocia or urinary tract symptoms.<sup>1,2,3</sup> Complications such as rupture of the cyst may occur during delivery or during an abdominal intervention.<sup>4</sup>

The diagnosis should be entertained when a retrorectal mass is identified. This must be differentiated from teratoma, primary and secondary bony tumour and ovarian cysts. A plain x-ray of the abdomen usually shows a scimitar deformity of the sacrum. Previously myelography was the only reliable method for diagnosing a meningocele and demonstrate its communication with the spinal canal. However a narrow stalk or adhesion may prevent or delay the passage of the contrast material into the cyst.<sup>1,5</sup> A computed tomography scan following metrizamide myelography will clearly demonstrate and characterise the lesion. In a non-contrast study the

anterior sacral meningocele appears as a homogeneous cystic mass with density similar to cerebrospinal fluid.<sup>7</sup> Post myelography computed tomography scanning will demonstrate high attenuation of the meningocele being filled with contrast media and its communication with the thecal sac through the anterior sacral defect.<sup>9</sup>

Visualisation of its communication with the thecal sac differentiates this cyst from other intrapelvic liquid masses eg. ovarian cyst, diverticula of the bladder. Ultrasonography will demonstrate a large retrovesical cystic mass in a female patient posterior to the uterus.<sup>10</sup> Sonography would not however demonstrate the meningocele stalk and in a female patient may be mistaken for an ovarian cyst. Recently, magnetic resonance imaging has become the procedure of choice and a single case has so far been reported in the literature.<sup>11</sup>

## LEGEND

Figure 1 — A roentgenogram of the abdomen showing sacral scimitar sign of anterior sacral meningocele.

Figure 2a & b — Intravenous pyelogram showing normal upper collecting system but marked distortion and anterosuperior displacement of the bladder.

Figure 3 — Pelvic ultrasonography showing a single large cystic mass occupying most of the pelvis and displacing the bladder anterosuperiorly.

Figure 4 — Metrizamide myelography showing a normal lumbar thecal sac, with contrast media entering just above the bony sacral defect into a large pelvic cyst through a 4mm wide opening.

Figure 5 — Computed tomography of the abdomen and lumbosacral spine immediately after myelography, showing a large round presacral mass which filled with contrast media (metrizamide). Mass was connected to the bony sacral defect posteriorly and displaced the urinary bladder anteriorly.

## References

1. Oren M, Lorber B, Lee S, et al: Anterior sacral meningocele: report of five cases and review of the literature. *Dis Colon Rectum* 1977; 20: 492-505.
2. Smith H, Davis C: Anterior sacral meningocele: two case reports and discussion of surgical approach. *Neurosurgery* 1980; 7: 61-67.
3. Anderson F, Burke B: Anterior sacral meningocele: a presentation of three cases. *JAMA* 1977; 237: 39-42.
4. Baleriaux D, Osteaux M, Terwinghe G, et al: The management of anterior sacral meningocele with computed tomography. *Neuroradiology* 1977; 14: 42-43.
5. Sulston D; Sacral cysts. *Acta Radiol Diagn* 1963, 1: 787-795.
6. McCreath GT, Macpherson P: Sonography in the diagnosis and management of anterior sacral meningocele. *J. Clin. Ultrasound* 1980; 8: 133-137.
7. Villarejo F, Scavone C, Blazquez MG, et al: Anterior sacral meningocele: review of the literature. *Surg Neurol* 1983; 19: 57-71.
8. Quigley MR, Schinco F, Brown JT: Anterior sacral meningocele with an unusual presentation. Case report *J. Neurosurg* 1984; 61: 790-792.
9. Mapstone TB, White RJ, Takaoka Y: Anterior sacral meningocele. *Surg Neurol* 1981; 16: 44-47.
10. Dyck P and Wilson CB: Anterior sacral meningocele-case report. *J. Neurosurg* 1980; 53: 548-552.
11. Martin B and Boyer de Latour F: MR imaging of the anterior sacral meningocele — case report. *J. Comput Assist Tomogr* 1988 12(1) 166-167