

Primary mesenteric venous thrombosis – A case report

Samuel Kwan Sinn Tay, MBBS (Mal), FRCS (Glasgow), FRCSEd
Lecturer

Yew Pung Leong, MBBS (Monash), FRCS (Eng), FRCSEd
Lecturer and Consultant Vascular Surgeon

Department of Surgery
Universiti Kebangsaan Malaysia
Jalan Raja Muda,
50300 Kuala Lumpur

Summary

Mesenteric venous thrombosis has been described to occur in cases where there has been no apparent cause. The diagnosis is usually delayed because the signs and symptoms are non-specific. A case of primary mesenteric venous thrombosis is reported below. Its presentation and pathology are discussed. Treatment is surgery with resection of gangrenous bowel and primary anastomosis. Post-operative anticoagulation is advocated.

Introduction

Acute mesenteric ischemia is a grave condition with high mortality and morbidity. The aetiology may be differentiated into arterial or venous. Mesenteric venous thrombosis has been described as early as the 15th century¹ but interest in it became more apparent in the early 20th century. It has been estimated to be responsible for 15–45² per cent of all clinically significant mesenteric vascular accidents. A case of primary mesenteric venous thrombosis is described.

Case Report

LYT, a 44 year old Chinese man presented with a week's history of vague abdominal pain. Two days prior to admission, it became more severe with associated vomiting and abdominal distension. His bowel habit was unchanged. On examination, he was febrile with a tachycardia of 112 beats per minute. His abdomen was evenly distended, soft with mild left abdominal tenderness. Abdominal X-ray was unremarkable. He was then noted to be diabetic. A diagnosis of subacute intestinal obstruction was made and he was treated with nasogastric suction and intravenous drip. Over the next 24 hours, he deteriorated rapidly. He developed septicemic shock with generalised peritonitis. A repeat abdominal X-ray (Fig. 1) showed features suggestive of small bowel ischemia. Emergency laparotomy was performed.

At laparotomy, there was 1.5 litres of hemorrhagic ascitic fluid. Extensive small bowel gangrene was evident, leaving only the proximal 45.7 cm and the distal 91.4 cm of small bowel viable. The small bowel mesentery was thickened, oedematous and hemorrhagic. The mesenteric veins

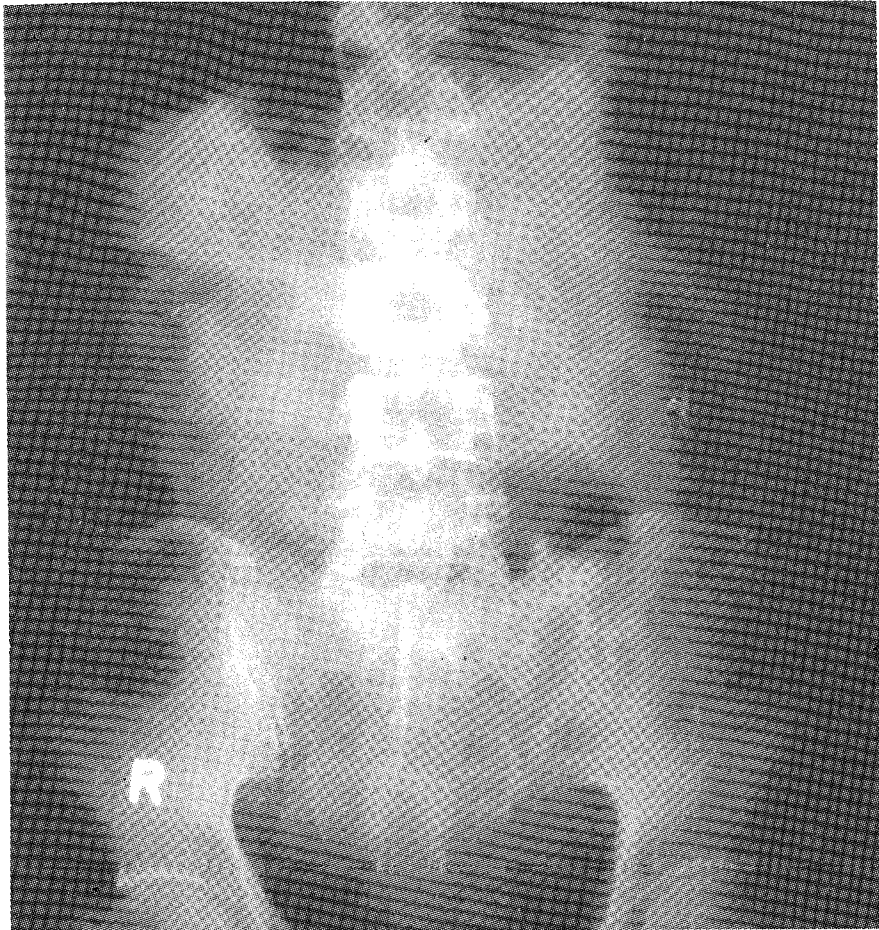


Fig. 1 There are distended loops of small bowel with mucosal and bowel wall thickening.

were thrombosed but the arteries were spurting when cut. The gangrenous small bowel was resected and continuity of the bowel re-established by end-end anastomosis. He was heparinised postoperatively.

His postoperative course was very stormy. His diabetic state was difficult to control requiring high doses of intravenous insulin. Septicemia was controlled with intravenous cefoperazone and metronidazole. Repeated blood cultures did not grow any organisms. He developed renal insufficiency but improved gradually over three weeks without need for renal dialysis. He developed melena on the 3rd postoperative day which persisted despite oral antacid and intravenous H_2 antagonist administration. Two days later, he developed gross hematuria. Prothrombin time was prolonged. Despite reducing the heparin dose to 10,000 units per day, he continued to have melena, gross hematuria and cardiovascular instability which required several units of blood transfusion. Heparinisation was then discontinued on the 10th postoperative day. He also had profuse diarrhoea which required oral anticholinergic therapy. This was gradually tailed off over one month. He was discharged well one month after the operation. Reviewed at 18 months, he remained well.

Discussion

Mesenteric venous thrombosis is not a common condition. It has been attributed to a variety of underlying pathologies.^{1,2} These included infection, hypercoagulable blood state, trauma to mesenteric veins and mechanical causes. None of these was apparent in this patient.

A prodrome of thrombophlebitis or episodic abdominal pain has been said to occur. This patient had abdominal pain for a week. Abdominal signs are minimal early in the course of the disease. Tenderness is marked while rigidity is often slight.

The pathology is thrombosis of the mesenteric veins and their tributaries while the arterial branches remain patent. The thrombosis can progress continuously or intermittently until all the anastomosing channels are obstructed.

Treatment is surgery, but this is usually performed late because diagnosis is difficult in the early stages. When diagnosis is delayed, as in this case, the patient develops generalised peritonitis and often becomes septicemic with cardiovascular collapse. When shock has supervened, the prognosis is grave. In this patient, the postoperative course was very stormy although he survived. There has been a report³ of the usefulness and accuracy of CT Scan and ultrasonography in making an early diagnosis of acute mesenteric vein thrombosis leading to successful conservative treatment.

Anticoagulation has been advocated postoperatively because of the possibility of recurrent mesenteric venous thrombosis.^{1,2} It was found that if recurrence of thrombosis were to occur, it usually occurred early.² As such, a six to ten week course of anticoagulation intravenous heparin initially followed by oral warfarin was recommended.

It is hoped that this case report will increase the awareness of this condition in patients who present with vague abdominal pain with nonspecific abdominal tenderness. An early diagnosis is dependent on an awareness of this condition and a high index of suspicion.

Acknowledgements

I thank Dr. Abdul Samad Sakijan, (Lecturer in Radiology, Universiti Kebangsaan Malaysia) for his comments on the radiographs.

References

1. Berry, FB and Bougas, JA. Agnogenic Venous Mesenteric Thrombosis. *Ann. Surg.*, 1950, 132: 450-474.
2. Naitove, A and Weismann, RE. Primary Mesenteric Venous Thrombosis. *Ann. Surg.*, 1965, 161: 516-523.
3. Verbanck, JJ; Rutgeerts, LJ; Haerens, MH; et al. Partial Splenoportal and Superior Mesenteric Venous Thrombosis. *Gastroenterology* 1984, 86: 949-952.