

Renal size in healthy Malaysian adults by ultrasonography

F. Wang, FRCPEd, FRACP
Professor and Head
Department of Medicine
Faculty of Medicine, University of Malaya,
59100 Kuala Lumpur

S.P. Cheok,
Medical Laboratory Technologist

B.B. Kuan, DMRD (Lond), FRCR (Lond)
Consultant Radiologist

Summary

Two hundred and five healthy Malaysian adults were scanned for the length of their kidneys and the cortical thickness by both the sector real time and linear array static B-scan diagnostic ultrasound. The length of the left kidney was found to measure 105 (98–111) mm for males, and 100 (94–106) mm for females on average from the sector scan and the static B-scan. The right renal length was 102 (96–119) mm for males, and 98 (92–103) mm for females on the average from readings of both scans. The left kidney is longer in length than the right kidney in males and females on both scans. The cortical thickness at the equator of the kidneys of males and females ranges from 12–14 mm. In both sexes, the lengths of the kidneys may be estimated by the distance between the first to the fourth lumbar transverse processes when there is no scoliosis.

Key words: Ultrasonography, renal size, cortical thickness.

Introduction

In the mid sixties, several authors have described the estimation of renal size in normal individuals using radiographs.^{1,2} As radiography involves exposure to radiation and its quality is dependent on renal function and other technical factors, diagnostic ultrasound was introduced as an alternate modality some ten years later for assessment of the structure and size of the kidney.

The present ultrasonograph incorporating real-time scanning provides quick and immediate scanning. Its role in abdominal scanning is firmly established. It is used widely in the assessment of renal function by extrapolation of the length and cortical thickness. This is dependent on very careful and meticulous localisation of the poles of the kidneys and corticomedullary junction. It is also dependent on known normal values.

The present study describes the estimation of renal size and cortical thickness in 200 normal Malaysians with diagnostic ultrasound using both the sector and linear array static B-scan modes, and the findings.

Materials and methods

Two hundred and five healthy Malaysians, ages ranging from 18 to 63 years, were examined by diagnostic ultrasound on both the sector and static B-scan modes. Five were excluded due to various abnormalities: presence of kidney stones (two cases), renal cyst (one case) raised serum creatinine (one case) and hypoplasia (one case). Of the other 200 subjects, there were 104 males and 96 females. The heights and weights were recorded (Table I). Patients with deformity of the lumbar spine were excluded.

Ninety-four (94.4) per cent of males and eighty-seven (87.5) per cent of females were between the ages of 20 and 50 years of age. The mean height of the males were 167 ± 5.4 mm and of the females was 153.7 ± 15.1 mm. The mean weight of the males was 65.0 ± 10.1 kg and the females was 52.2 ± 7.0 kg. (Table I)

All scans were performed using the Technicare EDP 1200 ultrasound scanner incorporating the linear array static B-scan and sector real time. The sector real time has a 3.5 MHz transducer, while a 3.5 or 5 MHz transducer was used on the static B-scan. Owing to the intrinsic differences between the two scanners, a difference of up to 5 per cent in the readings was accepted.

Table I
Height and weight

	Height Mean \pm s.d.	Weight Mean \pm s.d.	Age (years) 20–49 (%)	Mean (years)	Total
Male	167.0 ± 5.4	65.0 ± 10.1	97 (94)	35.12	104
Female	153.7 ± 15.1	52.2 ± 7.0	84 (87)	36.25	96

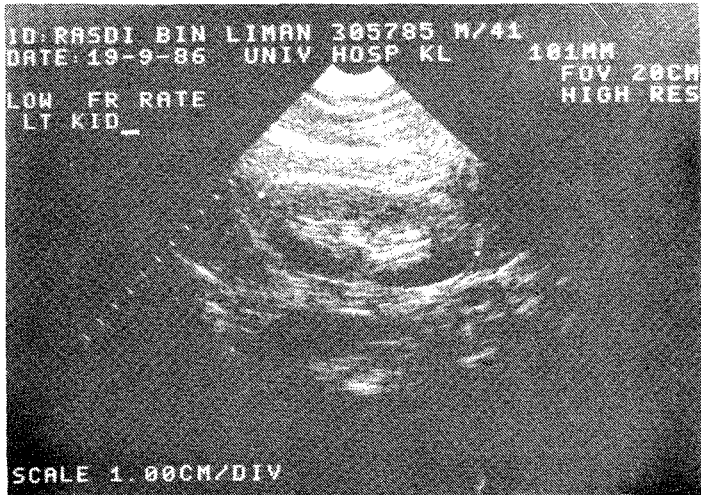Standard longitudinal ultrasound images of both kidneys were obtained with the subject lying in the prone position, and a folded pillow placed beneath the epigastrium. The sector probe was used initially, with at least three readings of the bipolar kidney length imaged on the longest axis which was obtained by repeated readjustments of the probe (Fig. 1, 2). The average of these measurements was then taken as the true longitudinal length. The static B-scan probe was then used with a suitable transducer depending on the patient's build. The longest longitudinal axes of both kidneys was again determined and imaged (Fig. 3) three times, the average of which was recorded as the true length. At least three measurements of the cortical thickness were made and the average taken as the true thickness. The cortical thickness at the widest part (equator) of the kidney was measured from the renal capsule to the arcuate vessel at the cortico-medullary junction. The cortical thickness at the poles were not measured. Whenever the arcuate vessel was not visualised, the cortico-medullary junction was used instead.

With the static B-scan, several longitudinal cuts were made parallel to the left side of the vertebral column until the lumbar vertebral transverse processes were imaged. These were recognised by the dense echoes with posterior acoustic shadowing that they produced (Fig. 4). The average distance between the first and fourth transverse processes of the lumbar vertebrae was then recorded.

Blood was taken for serum creatinine and urine collected for urine microscopy and protein. All subjects with serum creatinine above 100 μ moles/litre and abnormal urine sediments were eliminated from this study.

Results

The average length of the right kidney was found to measure 103.3 ± 6.4 mm (mean \pm 2 SD) for males, and 98.3 ± 5.4 mm for females on the sector scan; 101.2 ± 6.0 mm and 97.6 ± 5.6 mm respectively on the static B-scan (Table II). The left kidney was found to measure $105.4 \pm$

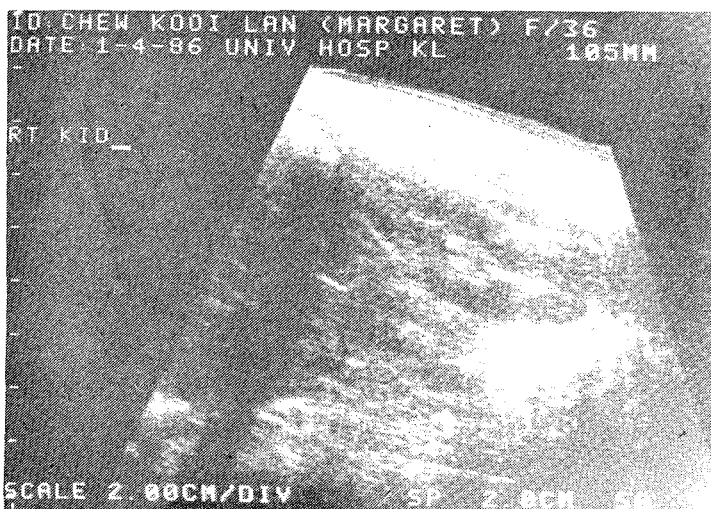
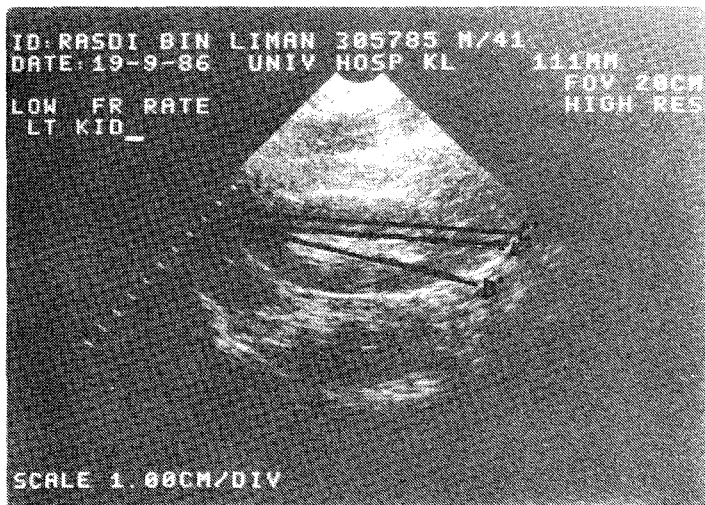
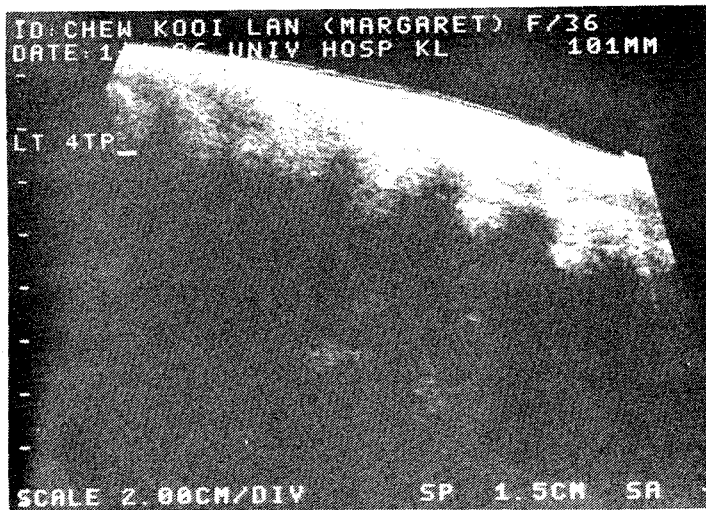



Table II
Renal length and cortical thickness in both the sexes for
both the right and left kidneys

	Males	Females	t	Significance
Right kidney sectors	103.3 ± 6.4	98.3 ± 5.3	t = 6.02 df = 198	P < 0.001
B-scan	101.2 ± 6.0	97.6 ± 5.6	t = 4.36 df = 198	P < 0.001
Cortical thickness	12.9 ± 0.8	12.7 ± 0.9		
Left kidney sectors	105.4 ± 6.5	99.7 ± 6.1	t = 6.36 df = 198	P < 0.001
B-scan	103.9 ± 6.6	99.7 ± 5.8	t = 4.79 df = 198	P < 0.001
Cortical thickness	13.1 ± 0.8	12.9 ± 0.9		

t = Student's T test

df = Degrees of freedom

6.0 mm for males, and 99.7 ± 6.1 mm for females on the sector scan; and 103.9 ± 6.6 mm and 99.7 ± 5.8 mm respectively on the static B-scan. The mean cortical thickness of the right kidney was found to measure 12.9 ± 0.8 mm for males and 12.7 ± 0.8 mm for females, while in the left kidney it measured 13.1 ± 0.8 mm in males and 12.9 ± 0.9 mm in females. The distance between the first and fourth lumbar transverse processes was 103.0 ± 6.5 mm for males and 97.8 ± 6.5 mm for females (Table III).

Table III
**Correlation between the first four lumbar transverse processes and
the-right and left kidneys in both sexes**

	Ultrasound	Kidney length		4 TP (mm)		Significance
		Males	Females	Males	Females	
Right kidney	Sector	*103.3 ± 6.4	*98.3 ± 5.3	103.0 ± 6.5	98.9 ± 6.5	P < 0.01
	B-scan	*101.2 ± 6.0	*97.6 ± 5.6			
Left kidney	Sector	*105.4 ± 6.5	*99.7 ± 6.1	103.0 ± 6.5	97.9 ± 6.5	P < 0.01
	B-scan	*103.9 ± 6.6	*99.7 ± 5.8			

4TP= Distance between Transverse Process of first to fourth Lumber Vertebrae

* = Significance < 0.01

Discussion

This study shows that the left kidney in the healthy adult Malaysian male and female is longer than the right kidney. The kidney in the male is of greater length than the kidney in the female (Table II–III). These findings are comparable to measurements in anatomic and radiographic studies.³ The length of the kidney correlates fairly well with the distance between the transverse processes of the first to fourth lumbar vertebrae and possibly with the height, weight and body surface area of the males. It also correlates well with the weight and body surface area of the female but not with the height of the females (Table IV). The reason for this is not apparent from this study. The difference in the thickness of the renal cortex in males and females are imperceptible by ultrasonography.

For practical purposes the following figures show the average lengths of the kidneys of healthy Malaysian males and females (Table V). This is based on the mean of the sector and the linear array B-scan findings.

These findings may still be applicable to the older patients where the renal mass may be reduced but renal lengths are minimally changed.⁴

The left kidney is longer than the right because it is located between the spleen and the spine and possibly compressed sideways by these structures. The right kidney however is compressed downwards by the liver. In standard anatomy and nephrology textbooks, the adult human kidney is said to be 11 cm in length, 50–75 mm wide and 25 mm thick. The thickness of the cortex of the kidney in the autopsy room is recorded as 10 mm. These measurements are due to the oligoemic states of the kidneys as opposed to the living vascularised state in the living. The exact size of healthy kidneys of Malaysians either in the vascularised or oligoemic states is not known.

Ultrasonography provides more accurate measurements of renal length than radiography. In radiography, the length of the kidney is magnified by the distance the kidney is separated from the X-ray plate so that an obese person will have apparently larger kidneys in ultrasonography of the kidneys there is no magnification. However, the true length of the kidney has to be carefully sought so that the mean of at least three best lengths will probably reflect the nearest

Table IV

Correlative table for significance in both sexes for kidney length, cortical thickness with height, weight and body surface area

	Ultrasound	Height (cm)	Weight (kg)	Body surface area (m ²)	Cortical thickness	
Right kidney	Males	Kidney length	P < 0.01	P < 0.01	P < 0.01	P < 0.01
		Cortical thickness	P < 0.01	P < 0.01	P < 0.01	P < 0.01
	Females	Kidney length	P < 0.05 N.S.	P < 0.01	P < 0.01	P < 0.01
		Cortical thickness	P < 0.05 N.S.	P < 0.01	P < 0.05	
Left kidney	Males	Kidney length	P < 0.01	P < 0.01	P < 0.01	P < 0.01
		Cortical thickness	P < 0.05 N.S.	P < 0.01	P < 0.01	
	Females	Kidney length	P < 0.05 N.S.	P < 0.01	P < 0.01	P < 0.01
		Cortical thickness	P < 0.05 N.S.	0.05 > P > 0.01	P < 0.05	

N.S. = Not Significant

Table V

Summary of normal kidney

	Left kidney (mm)		Right kidney (mm)	
	Length	Cortical Thickness	Length	Cortical Thickness
Males	105 (98–111)	13 (12–14)	102 (96–119)	13 (12–14)
Females	100 (94–106)	12.9 (12–14)	98 (92–103)	12.7 (12–14)

true length of the kidney. In Figure 1, Line A–A' cuts across the true length but line A–B' or C–C' will be less than the true length. By radiographic measurements, the length of the adult human kidney at its maximum size at about age 30 in Caucasians, is 13.5 cm (12.5–14 cm) for males. For females, at the same age, it is about 13 cm (12–13.5 cm). The length of the kidneys by ultrasound is 2–3 cm less than the radiographic measurements.³ The lengths of kidneys of Malaysians by intravenous urographic studies has not been made.

Most of the glomeruli are situated in the renal cortex: the area between the renal capsule and the cortico-medullary junction where the arcuate vessels run. Soon after acute renal failure the change in kidney size and cortical thickness may not be perceptible by ultrasonography.

In long standing kidney disease, the kidney undergoes fibrotic change; the glomeruli may be sclerotic and the renal cortex shrinks so that the bipolar length of the kidney decreases. Thus the presence of shrunken kidneys in a patient with clinical features of renal failure is almost always due to end stage disease.⁵ Ultrasonography of the kidneys is also useful in excluding structural lesions such as obstruction of the ureters, renal calculi or cystic lesions.³

Patients with chronic renal failure often have no clear history of past renal disease. However, when there is such a history, it does not follow that the renal failure is due to the past disease unless the progression of the disease has been closely recorded. It is important that every patient with raised serum creatinine should have an ultrasound study of the kidneys to provide direction for appropriate decisions of further procedures and further management. The renal lengths obtained in this study should be a useful guide.

Acknowledgements

We wish to thank Dr. D. Samuel, Head of Radiology Department for use of equipment, all the hospital staff who acted as volunteers and Ms Belinda Tan for typing.

References

1. Saunders, RC. The place of diagnostic ultrasound in the examination of kidneys not seen on excretory urography. *J. Urology* 1975; 114 : 813–821.
2. Saunders, RC & Jack DL. B-scans ultrasound in the evaluation of renal failure. *Radiology* 1976; 119 : 199–202.
3. David Sutton. Ultrasonography In: David Sutton (editor). *A textbook of Radiology and Imaging*. (Fourth edition) Edin. Churchill Livingstone 1987; 1787–1794.
4. Simon AL. Normal renal size: An absolute criterion. *Amer. J. of Roentgenol.* 1964; 92 : 271–274.
5. McClennan BC. Current approaches to the azotemic patient. *Radiology Clinic of North America* 1979; 27 : 197–211.