

Failed intubation in a case of oculoauriculovertebral dysplasia (Goldenhar's syndrome)

K. Mohandas, MBBS, FFARACS, MD
Department of Anaesthesiology

S. Selvarajah, MBBS, FRCSE, FACS
*Department of Ophthalmology
General Hospital
Kuala Lumpur*

Summary

A case of oculoauriculovertebral dysplasia (Goldenhar's syndrome) presented for the removal of epibulbar dermoid under general anaesthesia. Repeated attempts to intubate the patient after the induction of general anaesthesia failed. The problems encountered in such cases and their management are discussed.

Key words — Intubation, airway, ocular lipomo, Goldenhar's syndrome.

Introduction

Goldenhar's syndrome (oculo-auriculo-vertebral dysplasia) is characterised by epibulbar dermoids, auricular appendages, and vertebral anomalies including occipito-atlanto fusion, wedge and block vertebra, hemivertebra, spina bifida, and/or scoliosis. In addition to the above anomalies there are unilateral colobomas and occasionally microphthalmia; cataract or atrophy of the iris. The ears show bilateral appendages, and pretragal fistulae; occasionally microtia and deafness are present. The external auditory canal may be absent. The facies is characteristic with frontal bossing, hypomandibulosis, and sometimes poorly developed nostrils giving a "parrot-like" appearance. Maxillary hypoplasia, micrognathia, high arched palate, and dental malformation are also seen. Mental deficiency occurs in only 10-15% cases. Associated defects of heart, lungs and extremities are not infrequently present. No inherited pattern is known.¹ Goldenhar's syndrome is sometimes associated with hemifacial microsomia of which it may be a variant and both of these conditions show some resemblance to mandibulofacial dysostosis.

Case Report

A nine-year old Chinese male presented for removal of epibulbar dermoid in the left eye under general anaesthesia. During pre-anaesthetic evaluation the patient was noticed to have unilateral facial dysplasia with microstomia (Fig. 1a). Patient had deficient external auditory meatus with supernumerary ear tags (Fig. 1b). The left hand showed hypoplasia of the radius and the ulna. The thumb was absent in the left hand (Fig. 2). There were no signs of mental retardation and

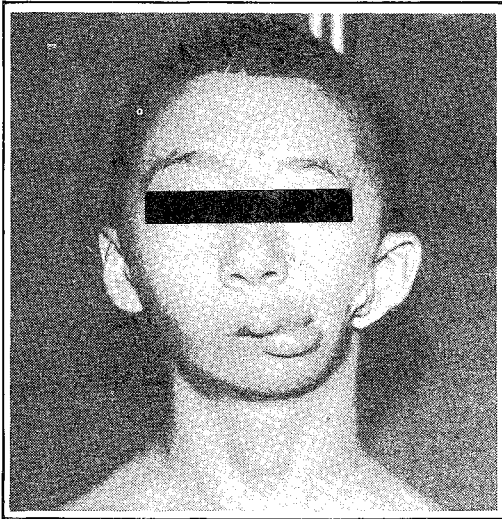
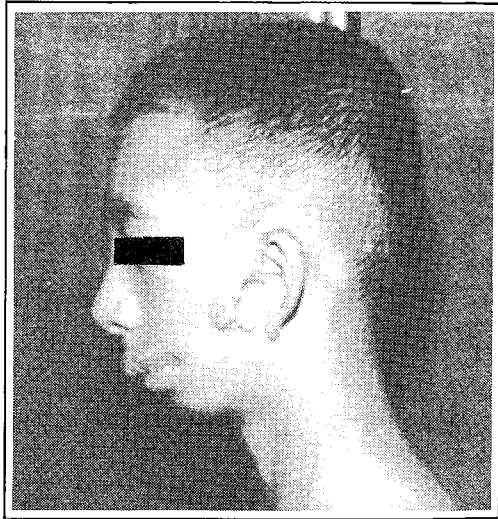


Fig. 1(a) : Note the epibulbar dermoid of the left eye



(b) : Supernumerary ear tags micrognathia.

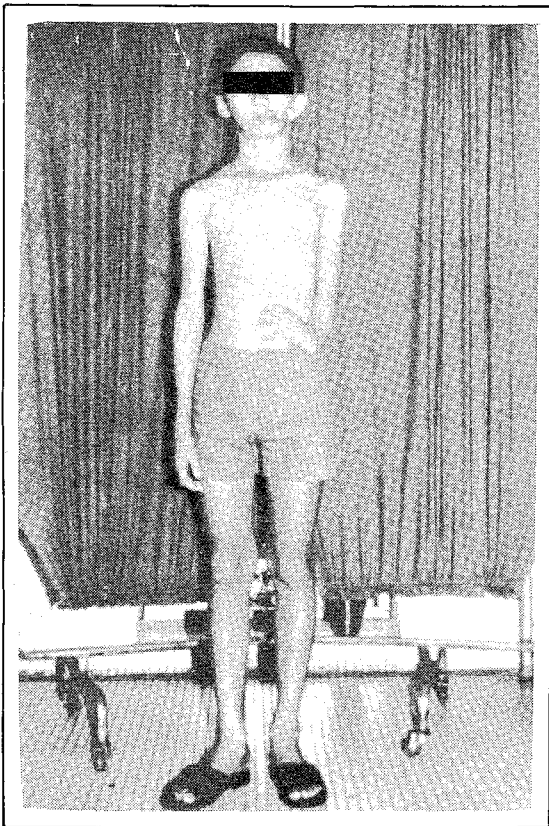


Fig 2: Showing facial dysplasia and abnormal upper limb.

the boy was studying in Standard III. The cardiovascular and respiratory systems were normal. Examination of the spine showed no abnormality. Patient was premedicated with intramuscular pethidine and promethazine.

Anaesthesia was induced with sleep dose of thiopentone and manual ventilation was attempted during the period of thiopentone apnoea. Ventilation was possible with mask and Magill circuit.

It was then decided to attempt intubation of the patient under paralysis. Intubation was attempted after obtaining paralysis with suxamethonium. Repeated attempts to visualize the glottis failed. The curved blade of the laryngoscope was changed to a straight blade and this also did not help. Ventilation with mask was carried out until patient's spontaneous respiration returned. Anaesthesia was continued with halothane and the patient breathing spontaneously through the mask. More attempts at intubation either with blind nasal intubation technique or with direct vision technique failed. Two naso-pharyngeal airways were then inserted into the two nostrils and with the help of protex universal connectors and endotracheal tube adaptors they were connected to the Magill circuit. Anaesthesia was continued with nitrous oxide, oxygen and halothane with the patient breathing spontaneously. The mouth was kept closed to prevent the patient from breathing through the mouth and diluting the anaesthetic gases. The ophthalmic surgeon removed the dermoid successfully. The operative procedure took about seven minutes. The patient's recovery from anaesthesia was uneventful and there was no post anaesthetic stridor or respiratory obstruction.

Discussion

The maintenance of the airway in our patient was without any problem during spontaneous breathing. Since the surgery was uncomplicated and of a short duration, the anaesthetic management was easy without intubation. However, if the patient had presented to us for any other surgery requiring muscle relaxation and controlled ventilation, management of this patient would have been altogether different and very difficult. Trans tracheal jet ventilation or a tracheostomy would have become a necessity in this patient to maintain ventilation and oxygenation. We did not have a fiberoptic laryngoscope which would have made intubation much easier in such cases. Assessment of the ability to ventilate a patient during the period of thiopentone apnoea is a very useful technique that helps the anaesthesiologist to decide about the administration of a muscle relaxant. Once ventilation could be maintained, and paralysis is contemplated the relaxant of choice is suxamethonium because of its short duration of action.

Intubation difficulties have been reported in cases of Pierre-Robin syndrome, Treacher-Collin syndrome (mandibulofacial dysostosis) and Goldenhar's syndrome.² Goldenhar's syndrome is sometimes associated with hemifacial microsomia (unilateral facial agenesis, otomandibular dysostosis) of which it may be a variant and both of these conditions show some resemblance to mandibulofacial dysostosis. Unilateral facial hypoplasia or aplasia of the mandibular ramus or condyle seen in Goldenhar's syndrome and hemifacial microsomia is absent in mandibulofacial dysostosis.

The necessity for careful evaluation of the airway in such case is usually very obvious by simply observing these patients. Micrognathia with receding jaw can make the visualization of the larynx impossible during attempted laryngoscopy. Cervical vertebral synostosis may prevent flexion or extension of the neck. Some of the methods for tracheal intubation may include the use of the fiberoptic laryngoscope, optical stylet, direct palpation of the epiglottis followed by "blind" oro or naso tracheal intubation, trans tracheal passage of guide wire retrogradely into the oropharynx.

No particular technique or drug is recommended. The anaesthetist should use techniques that allow spontaneous ventilation by the patient until he is certain that the airway can be managed. Only then, if at all, should muscle relaxants be used to facilitate tracheal intubation. The surgeon and the tracheostomy equipment should be present during the induction of anaesthesia.³

Acknowledgement

The authors wish to thank the Director General of Health Services Malaysia for permission to publish this paper.

References

1. John O Forfar, Gavin C Ameil. Textbook of Paediatrics: 3rd Edition. Churchill Livingstone 1984.
2. Feingold M, & Baum J: Goldenhar's Syndrome. Am J. Dis Child 1978; 132:136.
3. Richard E Berryhill Skin and Bone Disorders. In: Jordan Katz, Jonathan Benumof (Eds). Anesthesia and uncommon diseases: Philadelphia: W B Saunders, 1981 : 581.