

# Acute Stridor in Childhood; Retropharyngeal Abscess

YEO TING CHUAN MBBS(Mal), MRCP(Ire), MRCP(UK), DCH(Lond),

Paediatric Unit,  
Queen Elizabeth Hospital,  
88586, Kota Kinabalu,  
Sabah, Malaysia

**Summary:** Thirty-eight patients with acute stridor were admitted to the Paediatric Unit of the Alor Setar General Hospital over a three-year period (1984 – 1986). The causes are discussed and retropharyngeal abscess is highlighted as it is often initially overlooked. The clinical presentation and the problems in the diagnosis of the latter are discussed with reference to the three cases seen.

**Key words:** Acute stridor in childhood, retropharyngeal abscess.

## Introduction

Stridor of acute origin (commonly termed croup) is due to laryngeal or tracheal narrowing. The causes can be viral laryngotracheobronchitis (viral croup), acute epiglottitis, laryngeal diphtheria, retropharyngeal abscess, foreign body, allergic oedema, injury by steam or smoke inhalation or intubation and laryngeal spasm due to hypocalcaemia.<sup>1,2</sup> The relative importance of the various causes varies with different countries. Diphtheria is extremely rare in the developed countries. Retropharyngeal abscess was common in the pre-antibiotic era. It became less common with the introduction and the widespread use of antibiotics. It is, however, an important cause to recognise. Other than a good clinical examination, a high index of suspicion and a 'good' lateral x-ray film of the extended neck are essential for its diagnosis.

## Material and Methods

Over a three-year period (1984 – 1986), patients with acute stridor who were admitted to the Paediatric Unit of the Alor Star General Hospital were reviewed. Acute stridor is defined as stridor of less than seven days duration prior to hospital admission. Patients with chronic stridor were excluded from this study. The usual history and clinical examination were recorded. A 'careful throat examination' was performed on all the patients.

The laboratory investigations that were done included haemoglobin concentration, blood total white cell and differential counts, blood urea, serum electrolytes, throat swab for bacterial culture and sensitivity and x-ray films of the chest (postero-anterior view) and the neck (lateral view). Serum calcium was done on only one patient who had recurrent stridor. Viral studies were not done. Presumptive diagnosis of viral croup was made on the basis of typical clinical features and the exclusion of other causes.

This study did not include acute stridor associated with measles.

## Results

Thirty-eight patients had acute stridor. There were 26 Malays, 10 Chinese, one Indian and one Siamese. Twenty-two were males and 16 were females. Their ages

Cause	Number of patients	Mean age (months)
Viral laryngotracheobronchitis	31*	15
retropharyngeal abscess	3	9
laryngeal diphtheria	3	40
foreign body	1	12
Total	38	

\*including one patient with recurrent 'spasmodic' croup<sup>3</sup>

Table 1:  
Acute Stridor in childhood.

range from two months to four years. The causes and the mean ages of the patients are tabulated in Table 1.


Thirty patients had viral croup. The three cases of retropharyngeal abscess were initially diagnosed as viral croup. Three patients were suspected to have foreign body on admission, but only one turned out to be positive on bronchoscopy. There were three cases of laryngeal diphtheria (proven bacteriologically); however, two of them died soon after admission. They were admitted in a moribund state. Only one patient had recurrent 'spasmodic' croup.<sup>3</sup> He was admitted on three occasions with acute stridor. He was initially diagnosed as having viral croup, however, subsequent attacks were not associated with symptoms of upper respiratory infection. His serum calcium was normal. There were no deaths due to viral laryngotracheobronchitis, retropharyngeal abscess or foreign body. No case of acute epiglottitis or pseudomembranous croup was encountered over this three-year period. The three cases of retropharyngeal abscess are presented to highlight the problems in its diagnosis.

### Case One

A one-year-old Malay baby girl was referred from the Baling District Hospital with the diagnosis of viral laryngotracheobronchitis in respiratory failure. She had a history of low grade fever, cough, running nose and breathlessness for two days prior to admission. She had been immunised with BCG, DPT and Oral Polio vaccines. The past history was unremarkable.

On examination, she was afebrile. She was tachypnoeic and had inspiratory and expiratory stridor associated with sternal recession. The air entry was reduced bilaterally but there were no crepitations heard on auscultation of the lungs. Inspection of the 'throat' revealed a mildly inflamed pharynx. The cervical lymph nodes were not significantly enlarged. The other systems were normal.

Results of the investigations done revealed a haemoglobin concentration of 9.0g% and the blood total white cell count of 15,800 per mm<sup>3</sup> with a differential count of 63% polymorphs. The chest x-ray film was normal. Results of the blood gas analyses were normal too. She was started on an intravenous drip. Intravenous ampicillin and intranasal oxygen (via a catheter) were given. The following day, the stridor became worse and she was nursed in the Intensive Care Unit. She was intubated and put on continuous positive airway pressure with spontaneous respiration.



*Figure 1:*  
Lateral neck x-ray film showing widening of the prevertebral soft tissue space (indicated by an arrow) and anterior displacement of the larynx and the trachea.

No problems were encountered during intubation and on direct laryngoscopy, the pharynx and epiglottis appeared to be normal. However, a review of the lateral x-ray film of the neck revealed widening of the prevertebral soft tissue shadow with anterior displacement of the larynx and the trachea (Fig. 1). The diagnosis was changed to retropharyngeal abscess. The abscess was incised intra-orally under general anaesthesia and 4 cm<sup>3</sup> of thick pus was drained out. *Staphylococcus aureus* was isolated. The antibiotic was changed to cloxacillin. Following the procedure, she made an excellent recovery.

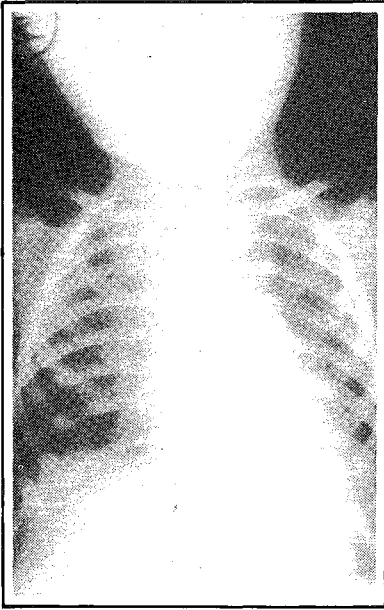
### Case Two

A one-year-old Malay baby girl was referred from the Sungai Petani District Hospital with a case of acute laryngotracheobronchitis with bronchopneumonia.

She had a history of fever and swelling on the left side of the neck for five days. Two days prior to admission, she was unable to swallow and had drooling of saliva. She had been immunised against tuberculosis, diphtheria, tetanus, whooping cough and poliomyelitis. The past history was not significant.

When seen initially, she was very fretful. She had a normal body temperature. She was not tachypnoeic although she had inspiratory stridor. On auscultation of the lungs, the air entry was reduced and crepitations heard bilaterally. There was a soft, tender swelling in the left cervical region. The child refused examination of the throat.

The results of the investigations were haemoglobin concentration 9.8g% and blood total white cell count 28,150 per mm<sup>3</sup> with a differential count of 70% polymorphs. The blood urea and serum electrolytes were normal. The chest x-ray film showed widening of the superior mediastinum and scattered opacities in both lung fields (Fig. 2).



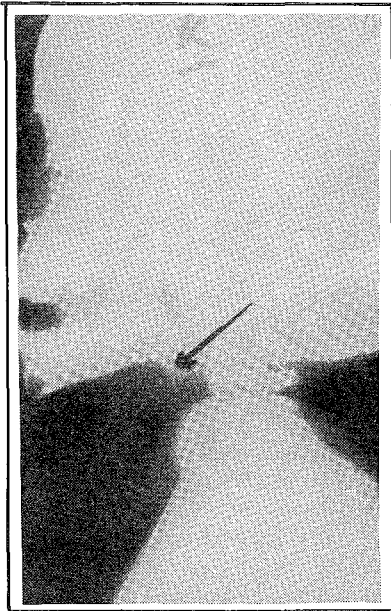
*Figure 2:*  
Chest x-ray film showing widening of the superior mediastinum and scattered opacities in both lung fields.

She was diagnosed as having acute laryngotracheobronchitis with bronchopneumonia and the left cervical swelling was thought to be an enlarged lymph node. An intravenous drip was set up and intravenous ampicillin was given on a six-hourly basis. The following morning, her condition deteriorated; she was cyanosed and tachypnoeic with severe stridor. She was intubated; during intubation, the posterior pharyngeal wall was noted to be 'bulging' and inflamed. The x-ray film of the lateral neck and the chest were carefully reviewed and it confirmed the retropharyngeal swelling (Fig. 3). The revised diagnosis was left cervical lymphadenitis and retropharyngeal abscess with superior mediastinitis. The antibiotic was changed to penicillin and netilmycin. The abscess was incised through the intraoral route and 50 cm<sup>3</sup> of pus was drained out. The organism isolated was *S. aureus*. The postoperative course was uneventful and she was discharged five days later.

### Case Three

A two-month-old Malay baby boy was admitted to the Paediatric Unit with a three-day history of cough and noisy breathing and a one-day history of fever prior to admission. He had been given BCG at birth. On admission, he was afebrile. He had inspiratory and expiratory stridor and excessive drooling of saliva. He had a respiratory rate of 44 per min. associated with sternal recession. On auscultation of the lungs, the air entry was reduced bilaterally. The pharynx was mildly inflamed on inspection. He also had a swelling on the left side of the neck which was not noticed on admission. The other systems were normal. He was initially diagnosed as having viral croup.

Results of the investigations showed a haemoglobin concentration of 10.1g% and the blood total white cell count of 15,400 per mm<sup>3</sup> with a differential

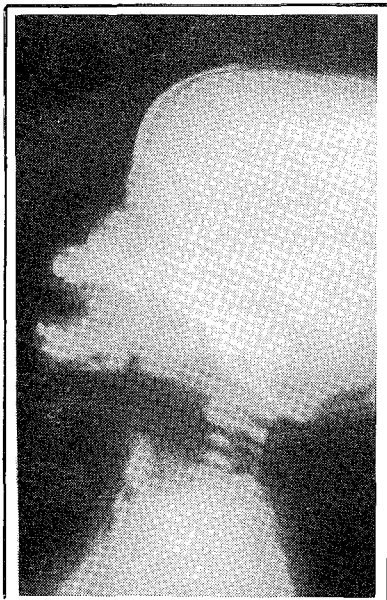

*Figure 3:*

Lateral neck radiograph showing widening of the prevertebral soft tissue shadow (indicated by an arrow), anterior displacement of the larynx and the trachea and loss of normal curvature of the cervical spine.

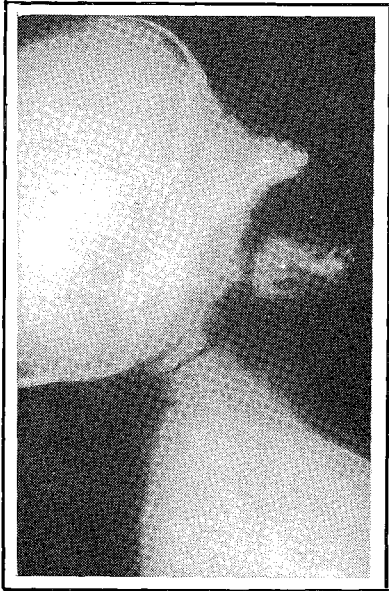count of 75% polymorphs. The blood urea and serum electrolytes were normal. The x-ray film of the chest was unremarkable but the x-ray film of the lateral neck showed marked widening of the prevertebral soft tissue shadow, anterior displacement of the larynx and the trachea and loss of normal curvature of the cervical spine (Fig 4).

The diagnosis was changed to left cervical abscess with retropharyngeal extension. Intravenous ampicillin and cloxacillin was commenced and arrangements were made for an incision and drainage (I + D) to be done as soon as possible. The I + D was done using the lateral cervical approach and 35 cm<sup>3</sup> of pus was drained out. *S. aureus* was isolated. The lateral neck x-ray was repeated (fig. 5). After the procedure, he made good recovery and he was discharged 10 days later.



*Figure 4:*

Lateral neck radiograph showing marked widening of the prevertebral soft tissue shadow, anterior displacement of the larynx and the trachea and loss of normal curvature of the cervical spine.



*Figure 5:*

Lateral neck x-ray film showing normal prevertebral soft tissue space and normal curvature of the cervical spine.

## Discussion

In the latest edition of the book 'Respiratory Illness in Children' by Phelan PD, Landau LI and Olinsky A, the authors listed the main causes of acute stridor<sup>3</sup> as shown in Table 2. Viral croup is the commonest cause of acute stridor in childhood. However, the relative importance of the other causes differs as was shown in our small series of patients. Retropharyngeal abscess and laryngeal diphtheria are relatively important causes. Acute epiglottitis, usually mentioned as a common cause in most paediatric books was not encountered during this period.

Only one patient was diagnosed as having recurrent 'spasmodic' croup.<sup>3</sup> This term is applied to a group of children who develops recurrent attacks of acute laryngeal obstruction. The initial episode of acute stridor is preceded by symptoms of upper respiratory infection and hence diagnosed as viral laryngotracheobronchitis. However, subsequent episodes occur without an obvious respiratory infection. The nature of this condition is obscure. It could be that recurrent 'spasmodic' croup is the manifestation of a hypersensitivity reaction to the viruses in some children who had a previous attack of acute laryngotracheobronchitis.<sup>5</sup>

We have not been able to document any case of pseudomembranous croup.<sup>4</sup> Pseudomembranous croup (other names include bacterial tracheitis and membranous laryngotracheobronchitis) is a serious form of laryngotracheobronchitis associated with sloughing of the respiratory epithelium and profuse mucopurulent secretions. It can resemble laryngeal diphtheria and acute epiglottitis in its presentation. The age-group of children affected is older than in viral croup; affected patients are toxic looking and febrile. The lateral x-ray film shows subglottic narrowing and frequently radioopaque material in the tracheal lumen. Unlike acute epiglottitis, the epiglottitis in this condition is normal. On endoscopy, a pseudomembrane consisting of thick mucopus and debris in the subglottic larynx and the trachea is seen. Unlike diphtheria, this pseudomembrane separates easily from

the lining of the airway without bleeding. The organism isolated is often *S. aureus*. Seven cases were reported by Henry RL et al<sup>4</sup> over a two-year period in the Royal Alexandra Hospital for Children in Camperdown, New South Wales, Australia in 1983.

acute laryngotracheobronchitis	very common
acute epiglottitis	common
laryngeal foreign body	uncommon
diphtheria	uncommon
acute angioneurotic oedema	rare
retropharyngeal abscess	rare

Table II:  
Causes of acute stridor in childhood.

Retropharyngeal abscess, as a cause of acute stridor, is often overlooked. There are many reasons for this.

It has become less common with the widespread use of antibiotics. It is listed as a rare cause of acute stridor in the major textbooks of paediatrics. Doctors seldom come across such a case and hence may not be aware of the condition as a cause of acute stridor.

A good knowledge of the regional anatomy of the neck is required to understand the predisposing factors, symptoms and signs of a retropharyngeal abscess. The anatomy and physiology of neck abscesses have been reviewed elsewhere.<sup>6-10</sup> In children, retropharyngeal abscess is due to infection of the ear, nose, throat or adjacent structures with spread to the retropharyngeal area by direct continuity or by lymphatics to the retropharyngeal lymph nodes. In adults, the infection which gives rise to a retropharyngeal abscess is often secondary to regional trauma such as foreign body ingestion, endotracheal intubation, endoscopic procedures, external penetrating injuries, vertebral fractures and even blunt neck injuries.<sup>10</sup> The onset of the symptoms and signs are often insidious in children. The symptoms may resemble those of viral laryngotracheobronchitis. In the three cases described, although the patients had a history of fever before admission, their body temperatures were normal on admission.

Retropharyngeal abscess usually occurs in infants and young children. Brown, in 1918, reported that 96% of retropharyngeal abscesses occurred in children under six years of age and 50% occurred in infants between six and 12 months.<sup>11</sup> More recently, Ravindra et al<sup>12</sup> reported four cases, all of whom were infants. The three cases reported here are infants.

The examination of the throat of infants and young children is not easy. A lot of skill and patience is required. Many of them resent throat examination. The relatively small size of the oral cavity makes examination difficult. Hence the retropharyngeal swelling may be missed. Furthermore, there may not be any swelling at all (as in case one, unlike in adults, where the presence of a bulging, red boggy swelling is diagnostic of a retropharyngeal abscess). It has been

---

suggested that it is justified to examine the pharynx under general anaesthesia if there is any doubt even though the initial finding on throat examination is negative.<sup>8</sup> It has been mentioned that palpation is an important manoeuvre in the diagnosis of a retropharyngeal abscess. However, it is difficult to do in infants and young children. A lateral neck x-ray is a very useful investigation in the diagnosis of a retropharyngeal abscess. However, problems are encountered in taking 'good' lateral x-ray films and its interpretation in infants and young children.

The size of the pre-vertebral soft tissue shadow varies with age. It is thicker in infants than in adults. The normal dimensions have been determined by Wholey et al.<sup>13</sup> The retropharyngeal space was measured from the anterior-inferior aspect of the second cervical vertebra to the posterior pharyngeal wall. The normal sagittal measurement for children 15 years and below was 3.5 mm (range 2–7 mm) and for adults was 3.4 mm (range 1–7 mm). Thus, when this measurement exceeds seven mm in children and adults, an abnormality exists in this space. As a rule of thumb, in children, the anterior-posterior diameter of the pre-vertebral soft tissue shadow should not normally exceed the diameter of the contiguous vertebral body.<sup>8</sup>

Changes in the thickness of the pre-vertebral soft tissue shadow can occur with different phases of respiration, crying, swallowing and various positions of neck flexion and extension because of the pliability of the airways and the mobility of the pre-vertebral soft tissues in infants and young children. The soft tissue shadow is thin during inspiration but thicker during expiration. The soft tissue shadow can be widened in the flexed position.<sup>14,15</sup> A true lateral x-ray film of the neck at the peak of inspiration with the neck fully extended is necessary for proper evaluation.

The complications of a retropharyngeal abscess which have been reported are asphyxiation, rupture of the abscess and aspiration causing pneumonia and empyema, spread into the superior and posterior mediastinum causing mediastinitis and life-threatening vascular complications. The internal jugular vein may be thrombosed and the carotid artery may be eroded resulting in fatal haemorrhage.<sup>10</sup> Mediastinal involvement can only be diagnosed radiologically. This complication was seen in one of our cases.

A variety of aerobic bacteria (*S. aureus*, *Streptococcus pyogenes*) and anaerobic bacteria (*Bacteroides species*) have been isolated; however, the commonest organism is *S. aureus*. The treatment of retropharyngeal abscess is I + D and the administration of the appropriate antibiotic. The I + D can be done either intra orally or extraorally using the lateral cervical approach. Some surgeons favour the intraoral approach for small localised abscesses and the lateral cervical approach for large abscesses.

## Conclusion

Viral laryngotracheobronchitis is the commonest cause of acute stridor in childhood. The relative importance of the other causes varies. Retropharyngeal abscess is often overlooked. A high index of suspicion and a thorough lateral neck x-ray



---

are essential for its diagnosis. Early diagnosis and treatment are important to avert life-threatening complications.

## References

- <sup>1</sup> Simpson H, Russel G, Forfar J O, Respiratory disorders. In : Forfar J O, Arneil G C (eds). Textbook of Paediatrics; Volume 1. 4th ed. Edinburgh, London, Melbourne and New York: Churchill Livingstone, 1984 : 525–611.
- <sup>2</sup> Stridor. In : Illingworth R S (ed). Common symptoms of disease in children. 6th ed. Oxford, London, Edinburgh and Melbourne: Blackwell Scientific Publications, 1979; 155–61.
- <sup>3</sup> Clinical patterns of acute respiratory infection; Respiratory noises. In: Phelan P D, Landan L I, Olinsky A (eds). 2nd ed. Oxford, London, Edinburgh, Boston and Melbourne: Blackwell Scientific Publications, 1982; 51–131.
- <sup>4</sup> Henry R L, Mellis C M, Benjamin B. Pseudomembranous croup. Arch Dis Child 1983; 58: 180–83.
- <sup>5</sup> Urquart G E D, Kennedy D H, Ariyawansa J P. Croup associated with parainfluenza type 1 virus: two sub-populations. Br Med J 1979; 1: 1604.
- <sup>6</sup> Wong Y K, Novotny G M, Retropharyngeal space-A review of anatomy, physiology, pathology and clinical presentation. J Otolaryngol 1978; 7 : 528–36.
- <sup>7</sup> Paonessa D F, Goldstein J C. Anatomy and physiology of head and neck infections on the fascia of the face and neck. Otolaryngol Clin North Am 1976; 9 : 561–80.
- <sup>8</sup> Seid A B, Dunbar J S, Cotton R T. Retropharyngeal abscesses in children revisited. LARYNGOSCOPE 1979; 89 : 1717–24.
- <sup>9</sup> de Clerq L D, Chole R A. Retropharyngeal abscess in the adult. Otolaryngol Head Neck Surg 1980; 88 : 684–89.
- <sup>10</sup> Barret G E, Koopmann C F, Coulthard S W. Retropharyngeal abscess – A 10-year experience. LARYNGOSCOPE 1984; 94 : 455–63.
- <sup>11</sup> Brown J M. Acute retropharyngeal abscesses in children. LARYNGOSCOPE 1919; 29 : 9–12.
- <sup>12</sup> Ravindra C, Merchant R, Dalal S, Pareksh S. Retropharyngeal abscesses in infants. Indian J Paediatr 1983; 50 : 449–50.
- <sup>13</sup> Wholey M H, Bruner A J, Baker H. L. The lateral roentgenogram of the neck. Radiology 1958; 71 : 350–56.
- <sup>14</sup> Brenner G H. Variations in the depth of the cervical prevertebral tissues in normal infants studied by cine-fluorography. Am J Roentgenol 1964; 91 : 573–77.
- <sup>15</sup> Swischuk L E, Smith P C, Fagan C J. Abnormalities of the pharynx and larynx in childhood. Sem Roentgenol 1974; 9 : 238–300.