

ACNE FULMINANS WITH DAPSONE INDUCED HAEMOLYSIS: A CASE REPORT

ROKIAH ISMAIL

INTRODUCTION

Acne is one of the most common disorders affecting mankind. Although acne does not cause death, it however produces a lot of discomfort, disfigurement and psychological trauma, particularly in teenagers.

Acne vulgaris is a chronic condition involving the pilosebaceous unit of the skin. It is characterised by the presence of comedones, inflammatory papules, pustules or cysts, and eventually by scarring. The end result of acne varies from hyperpigmentation, slight pitting, to extremely disfiguring scars that may develop into keloids.

Acne fulminans is a rare disorder and is characterised by sudden explosive appearance of highly inflammatory, tender, crusted, ulcerated lesions involving the back, chest and face. It is one of the most scarring acute dermatologic disorders of young people.

A case of acne fulminans in a young female who developed haemolysis due to dapsone is reported here.

CASE HISTORY

A 22-year-old Malay female student, who was previously healthy, developed mild acne three months prior to admission to the hospital. She was seen by her physician who prescribed her oral tetracycline and topical benzoyl peroxide.

One week before admission, the patient noticed sudden development of pustules on her face. She

was seen at the Dermatology Clinic, University Hospital, Kuala Lumpur. Physical examination showed a healthy young female with severe pustular acne on her forehead and cheeks (Fig. 1). There was no fever or arthralgia. Due to her poor response to the oral tetracycline prescribed previously by her doctor, she was started on oral dapsone 100/mg daily and advised to wash her face with 1% cetrimide solution.

One week later, she was seen again at the clinic with worsening of the lesions. She developed pain on the face and low grade fever. Physical examination showed that there were severe inflammation with pustules on the face. Some of these lesions had excoriated to form ulcers. Others were crusted and some were haemorrhagic. There were no comedones (Fig. 2).

There were tender, shotty cervical lymph nodes palpable. There was no pallor, cyanosis or dehydration. She had low grade fever. Her blood pressure was 130/90 mmHg, and the pulse rate was 80/min and was regular. All the other systems were normal. A diagnosis of acne fulminans was made and she was admitted to the medical ward.

Initial investigations showed haemoglobin of 13.7g%, reticulocyte count was normal. The total white cell count was 9200/ul and the neutrophils were 89%. The test for glucose-6-phosphate dehydrogenase was normal. Blood urea, serum electrolytes, and serum creatinine were normal. Urine microscopic examination was normal. A swab from the pustule was sent for culture and sensitivity. It grew *Staphylococcus pyogenes*. Repeat blood cultures showed no growth.

While in the ward, the patient was continued on 1% cetrimide facial wash three times a day, and dapsone was continued orally. However,

Rokiah Ismail, MBBS (Mal), MRCP(UK)
Dip.Derm.(Lond), Dip.Venerology (Lond)
Department of Medicine
Faculty of Medicine, University of Malaya
59100 Kuala Lumpur, Malaysia

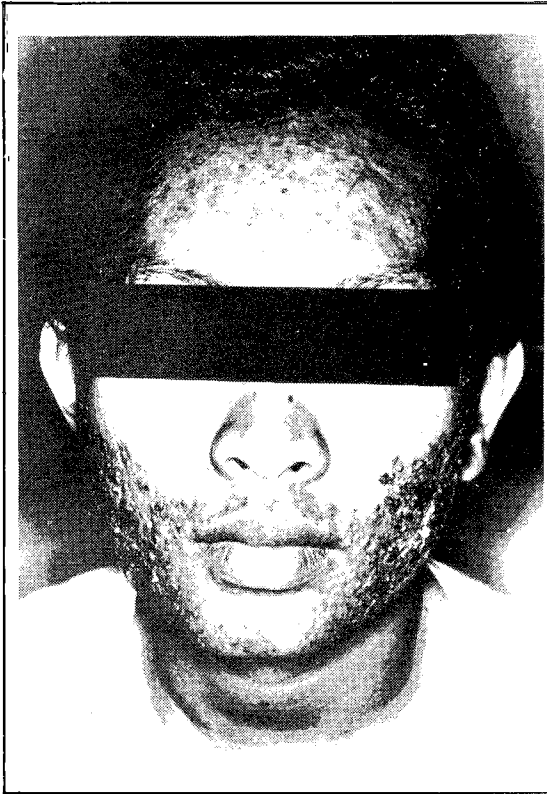


Fig. 1 Extensive pustules on the face and forehead.

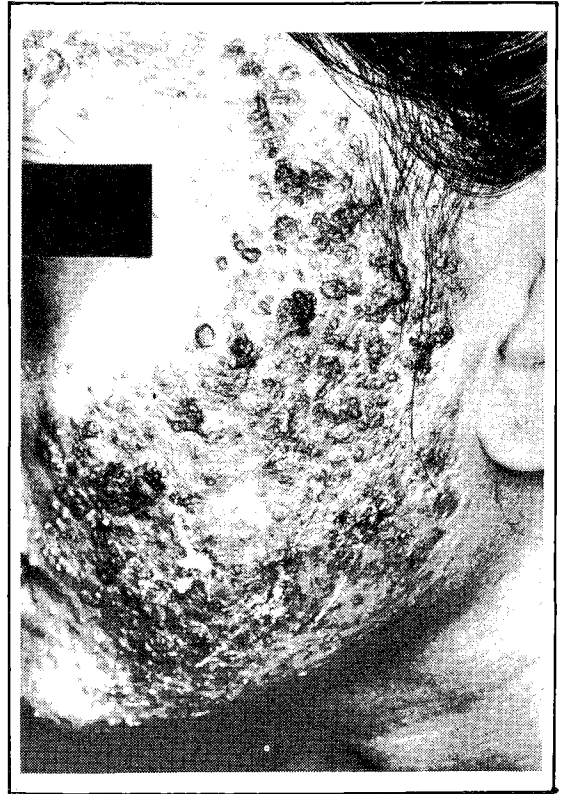


Fig. 2 Crusted lesions on the cheeks.

after one week of hospitalisation, the lesions progressively worsened with severe pustulation and marked inflammatory changes in the skin. She also complained of pain over the skin lesions. She was started on high dose intravenous cloxacillin.

After two weeks of hospital stay, despite both systemic and topical therapy, the patient became progressively worse. She was toxic-looking, with high fever, malaise and weight loss. She also complained of pain on both ankles. At the same time she was noted to be cyanosed. There was no jaundice. That evening she developed hypotension. She was then started on intravenous hydrocortisone, and cefotaxime was added to the cloxacillin. At that time a diagnosis of dapsone-induced haemolysis was also entertained. Blood and urine samples were sent for methemoglobin and were negative. A direct Coombs test was negative. There was marked reticulocytosis — from 3% to 20.6% over a period of one week.

Her haemoglobin dropped from 13.7g% to 8.4g%. There was leucocytosis of 13,800/ul, and the erythrocyte sedimentation rate was 36 mm in the first hour. Dapsone was immediately stopped and high doses of vitamin C and intravenous methylene blue were given. At the same time she was started on oral prednisolone 20mg 3 times a day. There was dramatic improvement of the facial lesions. The patient felt better and the lesions were less painful. Her appetite returned. The prednisolone was slowly tailed down.

Six weeks after admission, she was discharged well. However, there were deep scars on her face. On discharge from the ward, she was maintained on low dose oral tetracycline and topical benzoyl peroxide.

DISCUSSION

Acne fulminans differs from other forms of acne in that this condition is a rare, severely

scarring disease and appears with sudden violent onset.

Although previous reports suggest the occurrence of acne fulminans in male teenagers, one case was reported in a 29-year old male.^{1,2} Musculoskeletal symptoms have been reported in about half of the cases.¹

This patient had polyarthralgia involving both ankles, although there were no associated radiological changes as was previously described. Haemolysis due to dapsone was suspected in this patient when her symptoms worsened, she became hypotensive and the haemoglobin dropped, with marked reticulocytosis. There is a direct relationship between the dose of dapsone and the extent of haemolysis. Degowin noted that haemolysis was uncommon in the dose of 100mg/day. However, some authors reported that haemolysis with dapsone therapy can occur immediately following its use, especially when the initial dose given was higher than 100mg/day.³

However in this case the initial dose of dapsone was 100mg/day and she developed haemolysis within two weeks of institution of therapy. On the suspicion of dapsone-induced haemolysis, the drug was withdrawn and the patient showed dramatic improvement.

Dapsone: 4, 4-diamino diphenyl-sulphone.

REFERENCES

- ¹ Goldschmidt H, Leyden JJ, Stein KH. Acne fulminans: Investigations of acute febrile ulcerative acne. *Arch Dermatol* 1977; 113 : 444-449.
- ² Kelly AP, Bruns RE. Acute febrile ulcerative conglobate acne with polyarthralgia. *Arch Dermatol* 1971; 104: 182-187.
- ³ Desforges JR, Thayer WW, Dawson JP. Haemolytic anaemia-induced by sulfoxone therapy with investigations into the mechanism of its production. *Am J Med* 1959; 27 : 132-136.