

CHOLEDOCHAL CYST AND CHOLANGIOCARCINOMA

N.T.L. YEOH
K. SOMASUNDARAM
S. F. ALHADY
M. PARAMSOTHY

INTRODUCTION

Carcinoma of the biliary tract is a rare complication of choledochal cysts.^{1,2} Furthermore, the greater predisposition of the cyst wall to neoplastic change has been cited as additional justification for cyst excision rather than on-site internal drainage as the primary choice of operation. The report concerns a patient who developed cholangiocarcinoma despite excision of a choledochal cyst and presented with symptoms of biliary obstruction within one year of the operation. Although this is a rare complication, the need for careful long-term follow-up is supported by this observation.

N.T.L. Yeoh
Department of Surgery
School of Medical Sciences
Universiti Sains Malaysia
Minden, Penang

K. Somasundaram
Department of Surgery

S. F. Alhady
Department of Pathology

M. Paramsothy
Department of Nuclear Medicine
Faculty of Medicine
University of Malaya
59100 Kuala Lumpur, Malaysia

CASE HISTORY

A 19-year-old girl presented with a three weeks history of right upper quadrant pain, anorexia and nausea. Associated with this, she had noticed a painful swelling in the right upper abdomen and epigastrium. She had had a similar episode eight years ago which had resolved spontaneously. She had not been jaundiced and her urine and stools had been of a normal colour.

She was a well-nourished girl with a slight tinge of jaundice. She was afebrile with a regular pulse of 64 beats/min and a BP of 130/80 mmHg.

On abdominal examination, there was a 15 cm hemispherical swelling extending from below the right subcostal margin. It was tender to palpation and moved with respiration. The liver and spleen were not palpable. Rectal examination revealed normal-coloured stools.

She had a haemoglobin level of 12.1 g/100 ml and a white cell count of 7,600 cells/ul. Her liver function tests showed a mildly elevated bilirubin of 2.5 SI units with marked elevation of the alkaline phosphatase to over 350 SI units. Her liver enzymes were also mildly elevated with a SGPT of 280 SI units and SGOT of greater than 150 SI units.

Investigations including ultrasound, barium meal, CT Scan and 99m Tc-EHIDA hepatobiliary scintigram confirmed this mass to be a choledochal cyst. The right and left hepatic ducts were also seen to be grossly dilated (Fig. 1).

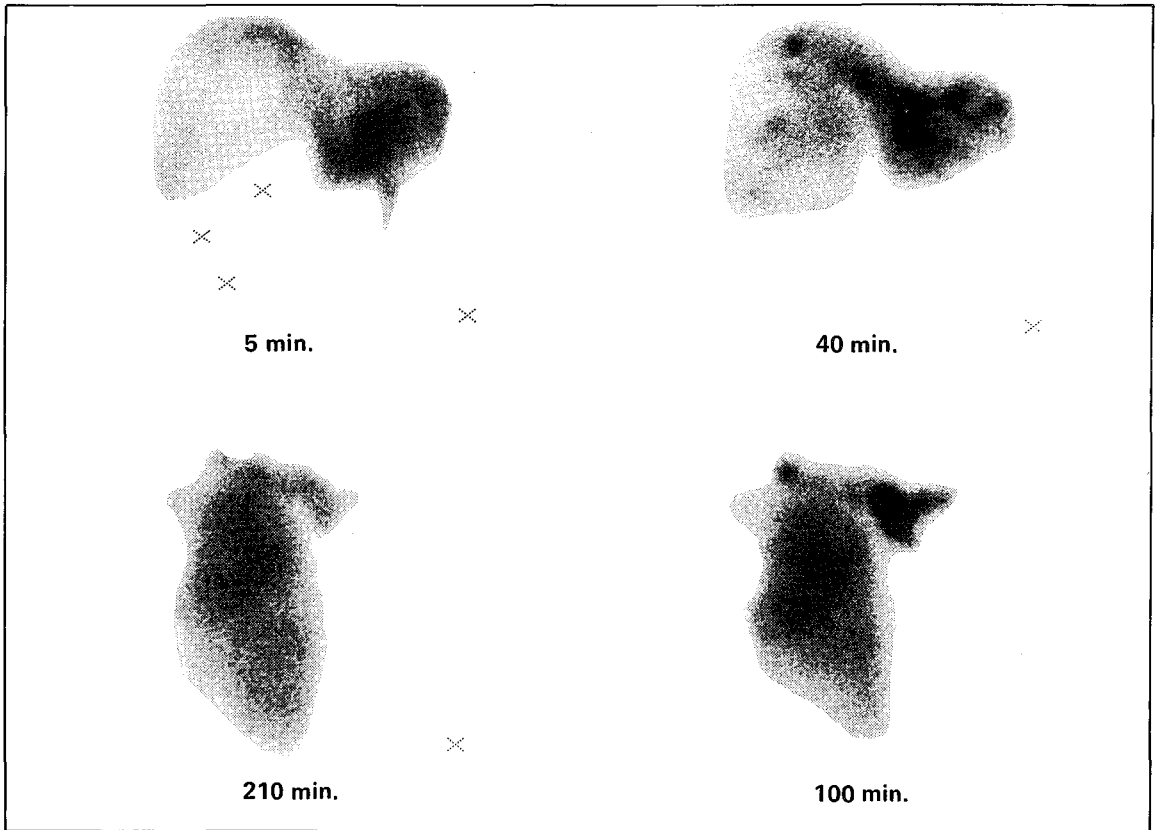


Fig. 1 99m Tc-EHIDA hepatobiliary scintigram showing delayed excretion from the liver, dilated hepatic ducts and a choledochal cyst.

At laparotomy, a large 10 cm x 10 cm Type I choledochal cyst was found. It contained 2 litres of uninfected bile. The cyst was excised leaving a 2 cm cuff distal to the bifurcation of the hepatic ducts. A Roux-en-Y loop of jejunum was then anastomosed to the hepatic duct.

Her post-operative recovery was unremarkable and when discharged nine days later, her liver function tests had all returned to within normal limits.

Histological examination of the cyst confirmed it to be a choledochal cyst with no evidence of malignancy.

A repeat 99m Tc-EHIDA hepatobiliary scintigram done two months later showed free flow of

the radiopharmaceutical into the bowel with no evidence of any obstruction (Fig. 2).

She remained well for a year when she presented with epigastric pain, fever and jaundice of two weeks duration. Examination then showed her to be pyrexial with a tender palpable liver which extended two finger breadths below the costal margin. Her liver function tests showed that her bilirubin was 28 SI units. Alkaline phosphatase was greater than 350 SI units, SGOT was greater than 300 SI units and SGPT was 380 SI units. Blood culture grew *Escherichia coli*. She was treated initially with antibiotics to which she responded very well and except for a persistently elevated alkaline phosphatase. The other parameters of liver function returned to normal.

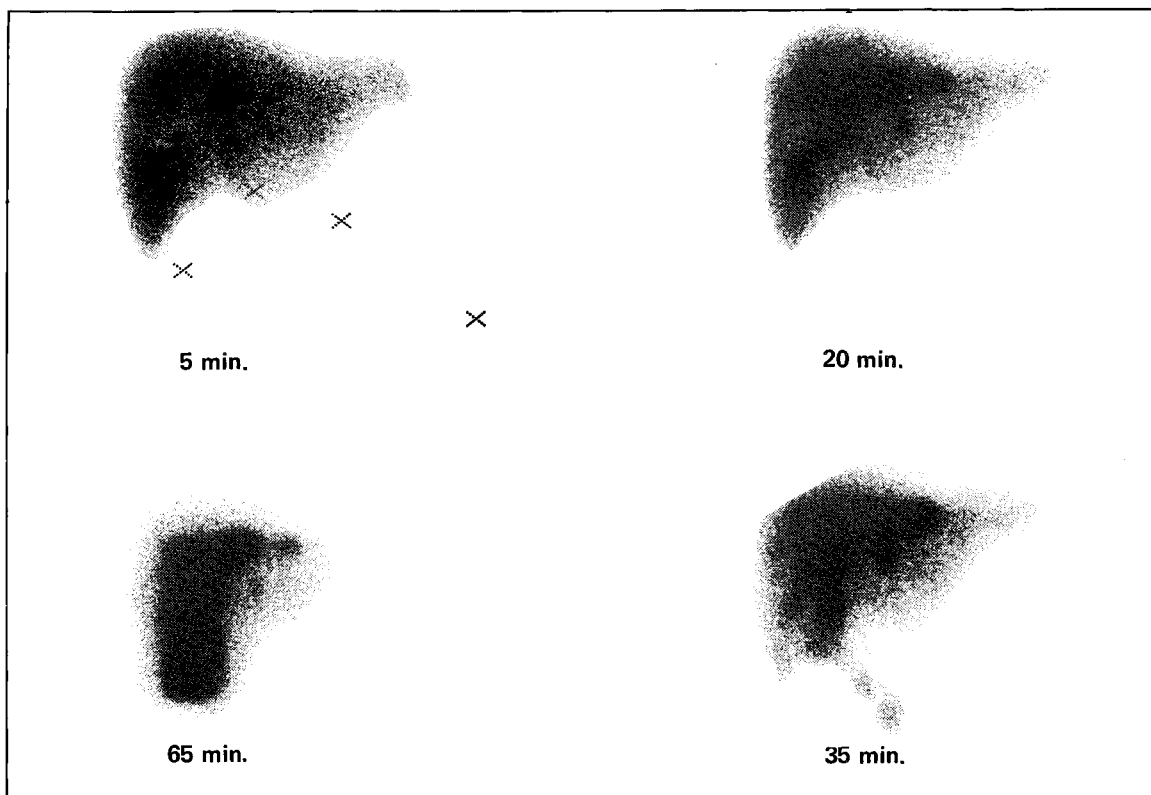


Fig. 2 ^{99m}Tc -EHIDA hepatobiliary scintigram two months post-operative showing free flow of radiopharmaceutical into the bowel.

Subsequent investigations including a percutaneous transhepatic cholangiogram showed gross dilatation of the left hepatic duct (Fig. 3). At laparotomy, the Roux-en-Y jejunal loop was identified and when traced to the porta hepatis it was found that there was a hard craggy mass 6 cm x 6 cm arising from the quadrate lobe which was compressing the hepatico-jejunal anastomosis.

In addition, there were two nodules over the dome of the right lobe of the liver. Frozen section biopsy of the mass showed it to be a cholangiocarcinoma. The left hepatic duct was markedly dilated and contained pus. It was drained by a U-tube. The right hepatic duct was only partially obstructed by the tumour.

Post-operatively, she had episodes of cholangitis which responded to antibiotics. However her general condition deteriorated. She developed

ascites and progressive liver failure and died two months later.

No post-mortem was obtained but multiple needle biopsies of the liver showed diffuse infiltration of the liver of malignant glandular structures which predominated in the portal areas consistent with cholangiocarcinoma (Fig. 4).

DISCUSSION

Although the first case of a choledochal cyst was reputed to have been reported by Vater in 1723, it was not until 1944 that Irwin³ reported on a case of a choledochal cyst with a carcinomatous change in the cyst wall. This was followed by another report in 1944 of another case, this time, the association was with a hepatic carcinoma. Since then, there have been scattered reports noting this link. In his review in 1977, Todani²

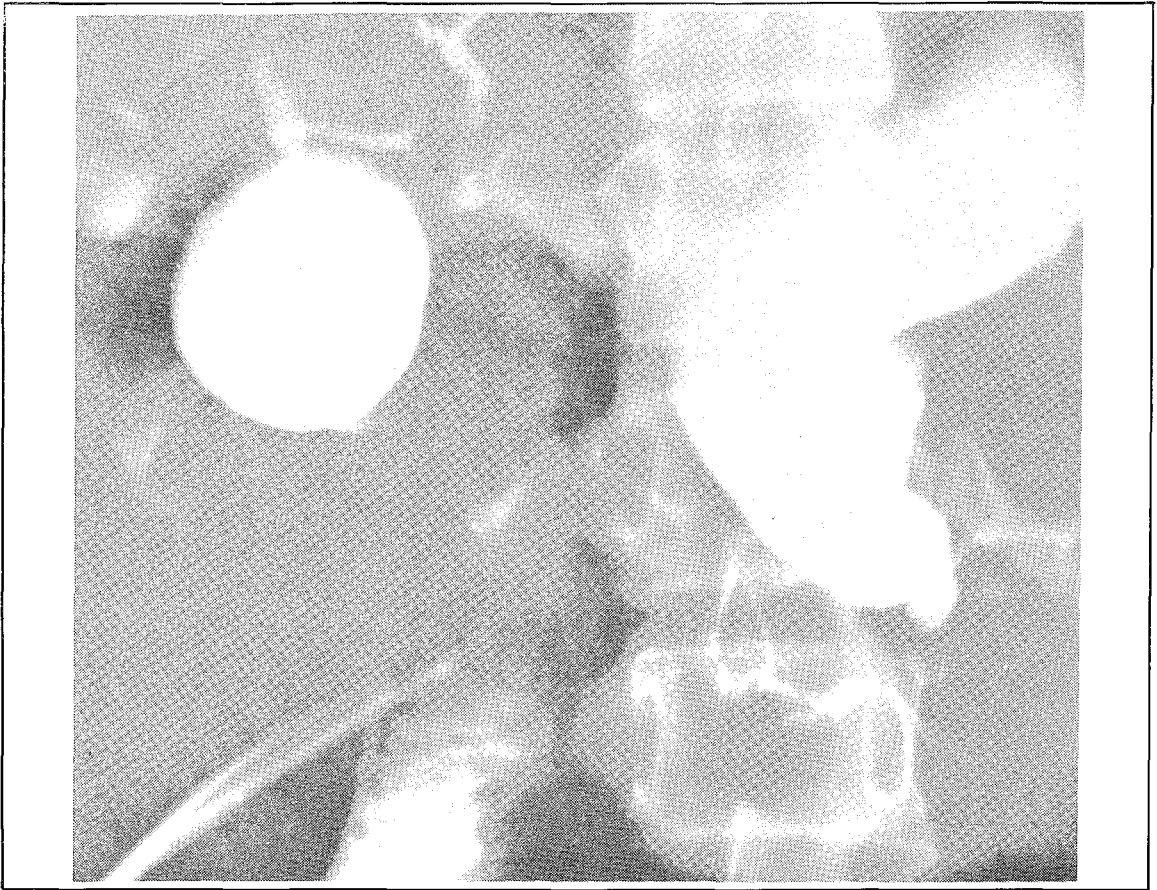


Fig. 3 Percutaneous transhepatic cholangiogram showing gross dilatation of left hepatic duct.

noted that there were 33 cases in the world literature.

Flannigan⁵ in his review in 1975, noted that when carcinoma develops in association with a choledochal cyst it may be of various histological types. The most common is the adenocarcinoma, but cases of squamous cell carcinoma have also been reported. These tumours may arise from any part of the biliary tree, including the intrahepatic bile ducts. The most frequent sites however tend to be the posterior cyst wall. It is for this reason that many authors^{1,2,6-8} have advocated excision of the cyst with primary hepatico-jejunostomy as the treatment of choice.

Whichever method of surgical treatment is employed, the possibility of malignant change is ever present. These patients therefore require life-long follow-up and any suggestion of the development of cholangitis should be intensively investigated to exclude the presence of malignant change. To date, there have been no survivals following the diagnosis of malignancy in choledochal cysts and this is all the more tragic as the average age of these patients is only 32 years.⁵

Gallagher⁹ described a case similar to ours. Their patient developed an intrahepatic carcinoma following excision of the choledochal cyst. This

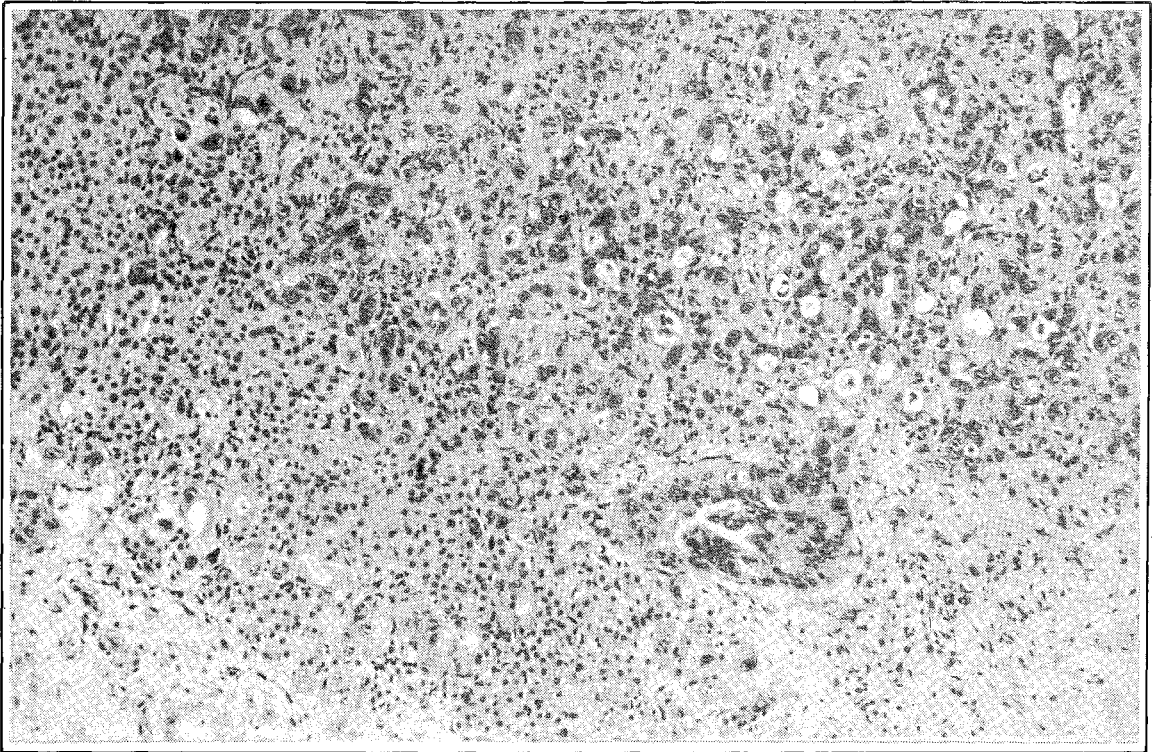


Fig. 4 Malignant glandular structures of cholangiocarcinoma infiltrating liver parenchyma (H & E) x 112.

reinforces the theory of global instability of the biliary epithelium associated with chronic bile stasis in patients with choledochal cyst. Excision of the cyst although does not completely protect the patient from later development of carcinoma in the intrahepatic ducts but nevertheless eliminates the risk of carcinoma in the cyst wall. It also provides for a better drainage of the biliary tree thereby preventing the stagnation of bile and its possible carcinogenic effects on the biliary epithelium.

REFERENCES

- ¹ Kasai M, Asakura Y, Taira Y. Surgical management of choledochal cyst. *Surgery* 1970; 172 : 844-851.
- ² Todani T, Watanabe Y, Narusue M *et al.* Congenital bile duct cysts. *Am J Surg* 1977; 134 : 263-269.
- ³ Irwin S T, Morison, J E. Congenital cyst of the common bile duct containing stones and undergoing cancerous change. *Br J Surg* 1944; 32 : 319-321.
- ⁴ Armanino L P. Idiopathic dilatation of the common bile duct with coexistent primary hepatic carcinoma: Report of a case. *Ann Intern Med* 1946; 24 : 714-726.
- ⁵ Fannigan D P. Biliary cysts. *Ann Surg* 1975; 182 : 635-643.
- ⁶ Warran K W, Kune G A, Hardy K J. Biliary duct cysts. *Surg Clin N Amer* 1968; 48 : 567-577.
- ⁷ MacFarlane J R, Gleen F. Carcinoma in choledochal cysts. *JAMA* 1967; 202 : 1003-1006.
- ⁸ Ackerholm P, Benediktsdottir K, Lundell *et al.* Cholangiocarcinoma in a patient with biliary cysts. *Acta Chir Scand* 1981; 147 : 605-607.
- ⁹ Gallagher R J, Millis R R, Mitchinson M J. Congenital dilatation of intrahepatic bile ducts with cholangiocarcinoma. *J Clin Pathol* 1972; 25 : 804-808.