

# PULMONARY VALVE ECHOCARDIOGRAM IN THE EVALUATION OF PULMONARY ARTERIAL HYPERTENSION IN THE PRESENCE OF INTRACARDIAC SHUNTS

FONG CHEE YEE  
K. T. SINGHAM

## SUMMARY

*The purpose of this study was to assess M-mode echocardiographic criteria for pulmonary artery hypertension in patients with intracardiac shunts, and to observe any signs not previously described.*

*Forty-seven consecutive cardiac catheterised patients with routine M-mode echocardiogram done were reviewed. Twenty-six patients had atrial septal defect, nine had ventricular septal defect (VSD), four had patent ductus arteriosus (PDA), five had Eisenmenger syndrome and three had combined VSD and PDA.*

*Fifteen of 20 patients with pulmonary artery mean pressure (PAMP) of more than 50 mmHg demonstrated diminished  $\alpha$ -dip ( $p < 0.001$ ), reduced e-f slope ( $p < 0.01$ ) and increased b-c slope to  $> 380$  mm/sec ( $p < 0.01$ ). The presence of systolic flutter or mid-systolic notch, or both was not observed in patients with normal PAMP,*

*but was noted in all of the 20 patients with raised pressure ( $> 50$  mmHg).*

*This study confirms the limitation of M-mode echocardiographic features in the evaluation of pulmonary artery hypertension in patients with intracardiac shunt, though clinically useful.*

## INTRODUCTION

Echocardiography has been noted to be of value in the diagnosis of pulmonary arterial hypertension.<sup>1,2</sup> Although pulmonary artery pressure cannot be estimated directly, changes in the patterns of pulmonary valve (PV) motion does allow some quantitative evaluation of pulmonary artery haemodynamics.

It is well known that the pulmonary valve is technically the most difficult valve to record echocardiographically, particularly in normal subjects. Detection rate has been reported at 35–55%.<sup>3</sup> We reviewed our records to see if there is a relationship between the PV echocardiographic patterns and pulmonary arterial pressure in patients with intracardiac shunts.

The present study is to evaluate the previously described M-mode PV patterns in the presence of pulmonary arterial hypertension and to note any features not previously described.

---

Fong Chee Yee, ASMLT  
Chief Cardiopulmonary Technologist  
Penawar Subang Jaya Medical Centre  
1, Jalan SS12/1A, 47500 Petaling Jaya  
Selangor, Malaysia

K. T. Singham, FRACP, FACC  
Associate Professor of Medicine  
Faculty of Medicine, University of Malaya  
59100 Kuala Lumpur

---

## MATERIALS AND METHODS

### Patients

The study population consisted of 47 patients who had right heart catheterisations and PV echocardiograms. There were 22 males and 25 females, their ages ranging from five to 66 years (average 21 years).

### Cardiac catheterisation

Pulmonary artery pressures were obtained during cardiac catheterisation using standard techniques. The 47 patients were divided into three groups: group A consisted of 13 patients with normal pulmonary artery mean pressure of less than 20 mmHg; group B had 14 patients with mildly raised PAMP (21 to 49 mmHg); and group C of 20 patients with a PAMP of more than 50 mmHg. None of these patients had a right ventricle end-diastolic pressure exceeding 10 mmHg. All patients were in sinus rhythm.

The cardiac catheterisation diagnosis was atrial septal defect in 26 patients, ventricular septal defect (VSD) in nine patients, patent ductus arteriosus (PDA) in four patients, Eisenmenger syndrome in five patients and combined VSD and PDA in three patients. Patients with complex congenital heart disease with intracardiac shunts were excluded from the study.

### Echocardiogram

The echocardiogram examination was performed with an Ekoline 20A echocardiograph using a 2.25 MHz transducer and a multichannel Cambridge stripchart recorder. M-mode echocardiogram, electrocardiogram, and where possible the phonocardiogram, were recorded at a paper speed of 50 or 75 mm per second. In all patients the PV echocardiogram was obtained by methods previously described.<sup>1,2,4</sup> At least three consecutive cardiac cycles during quiet respiration were recorded, analysed and averaged.

The analysis of the PV echocardiogram (Fig. 1) begins with consideration of the 'a' wave. It follows the P-wave of the ECG and reflects the effects of right atrial contraction on PV

motion.<sup>5,6</sup> In this study, the maximum a-dip was measured at quiet respiration.

The 'b' point, following 'a' wave, represents the position of the wave at the onset of ventricular ejection. The posterior PV leaflet moves rapidly posteriorly to point 'c'. Thus, 'b-c' slope reflects the fully opened position of the leaflet. The maximum slope was measured.

Point 'c to d' is indicated by a gradual anterior movement of the PV leaflet. This reflects the opening period of the leaflet throughout the occurrence of mid-systolic closure and/or fluttering was observed during this phase. Following this period of PV opening the valve closes rapidly in diastole. It is indicated from point 'd to e'. During diastole the leaflets move from 'e' to a point 'f'. The initial rapid slope was measured.

### Data analysis

Paired comparisons were made using the t-test. The pulmonary artery mean pressures were plotted against the pulmonary valve a-dip, diastolic 'e-f' slope and systolic opening 'b-c' slope, recorded echocardiographically.

In addition, the systolic segment of the PV echocardiogram were observed for mid-systolic closure and/or fluttering.

## RESULTS

### The a-dip

Table I shows the relation between a-dip and pulmonary artery mean pressure. In group C, we found that 15 of 20 (75%) patients demonstrated complete absence of the a-dip. The mean a-dip in this group is  $0.8 \pm 1$  mm ( $p < 0.001$ ). There is a general indication that the a-dip diminishes as the PAMP increases, as shown in the table.

The group A patients had a mean a-dip of  $2.1 \pm 2.6$  mm with a range of 0 to 7 mm. We noted 7 of 14 (50%) had an absence of the a-dip. There was no significant difference in the mean value between group A and group B. It can be

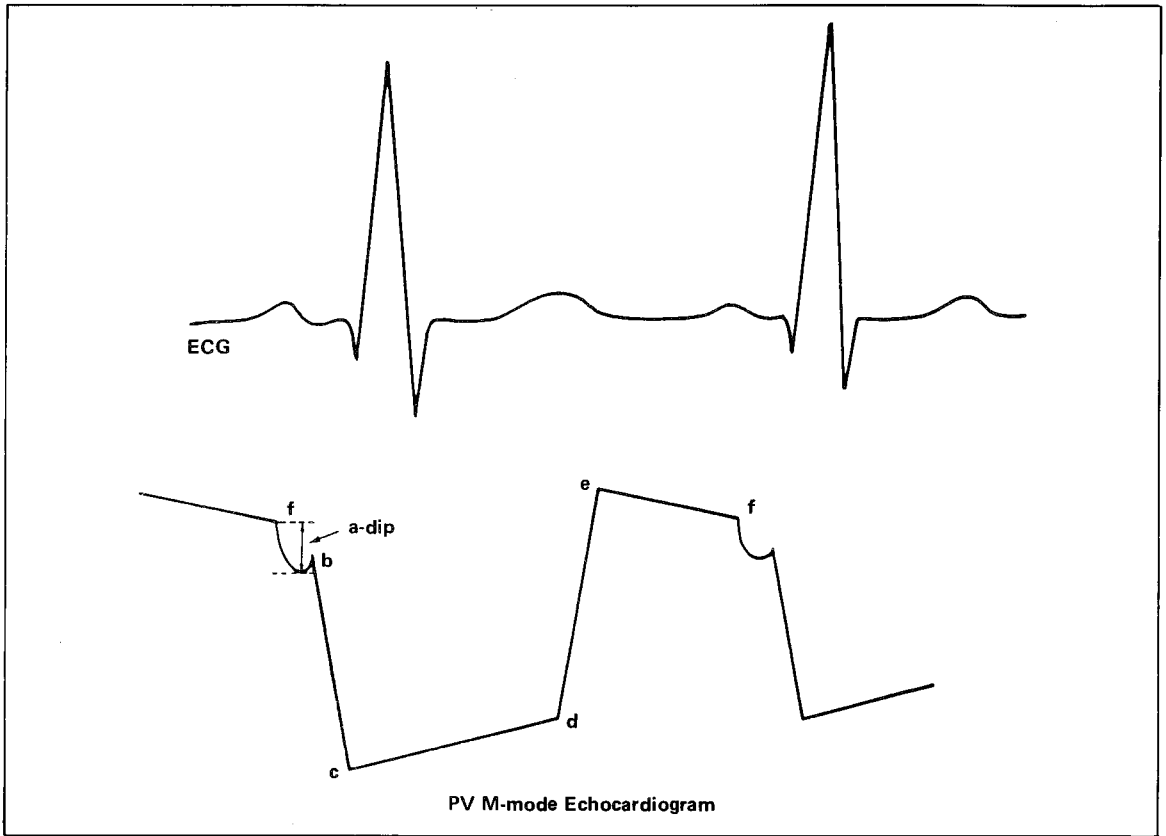


Fig. 1 This diagram demonstrates the pattern of posterior pulmonary valve echocardiogram and its relationship to the ECG.

TABLE I  
ECHOCARDIOGRAPHIC DATA OF PULMONARY VALVE IN RELATION TO  
PULMONARY ARTERY MEAN PRESSURES

M-mode feature	Group A ( $\leq 20$ mmHg)			P	Group B (21–49 mmHg)			P	Group C ( $> 50$ mmHg)			P
	mean	S.D. ( $\pm$ )	(range)		mean	S.D. ( $\pm$ )	(range)		mean	S.D. ( $\pm$ )	(range)	
a-dip (mm)	2.1	2.6	( 0–7 )	$<0.001$	2.0	2.5	( 0–7 )	$<0.001$	0.8	1.0	( 0–3 )	$<0.001$
e-f slope (mm/sec)	32.0	23.5	( 5–98 )	$>0.05$	15.0	17.0	( –3–50 )	$>0.10$	10.0	13.0	( –3–47 )	$<0.01$
b-c slope (mm/sec)	348.0	127.0	(210–600)	$>0.10$	345.0	82.0	(220–400)	$>0.10$	425.0	95.0	(300–560)	$<0.001$
Flutter			0				3				7	
Notch			0				2				3	
Flutter & Notch			0				0				13	

observed that the presence of a normal a-dip was not a sensitive predictor of normal PAMP.

### The b-c slope

The b-c slope was compared with pulmonary artery mean pressure. In 13 patients with normal PAMP, the b-c slope was  $349 \pm 129$  mm/sec ( $p > 0.10$ ) versus  $425 \pm 94$  mm/sec ( $p < 0.001$ ) of group C. Mean b-c slope in group A was similar to that in group B.

In assessing the normal (PAMP  $\leq 20$  mmHg) and abnormal (PAMP  $> 21$  mmHg), the b-c slope was not significantly higher. However there is indication of a higher b-c slope ( $> 380$  mm/sec) in 15 of 20 patients with pulmonary artery mean pressure of more than 50 mmHg.

### The e-f slope

The e-f slope was compared with pulmonary artery mean pressure and was definitely reduced in group B than in normal PAMP. It did not correlate with group A ( $p > 0.05$ ) and group B ( $p > 0.10$ ) but was significant with group C ( $p < 0.01$ ). The overlap in measurements was too great to allow separation between groups.

### Systolic flutter and/or mid-systolic closure

In patients with elevated pulmonary artery mean pressure, we have noted systolic fluttering and/or mid-systolic closure (Fig. 2) which was not present in any of the 14 patients with normal PAMP. Pulmonary valve flutter and mid-systolic closure appear to co-exist. All 20 (100%) patients

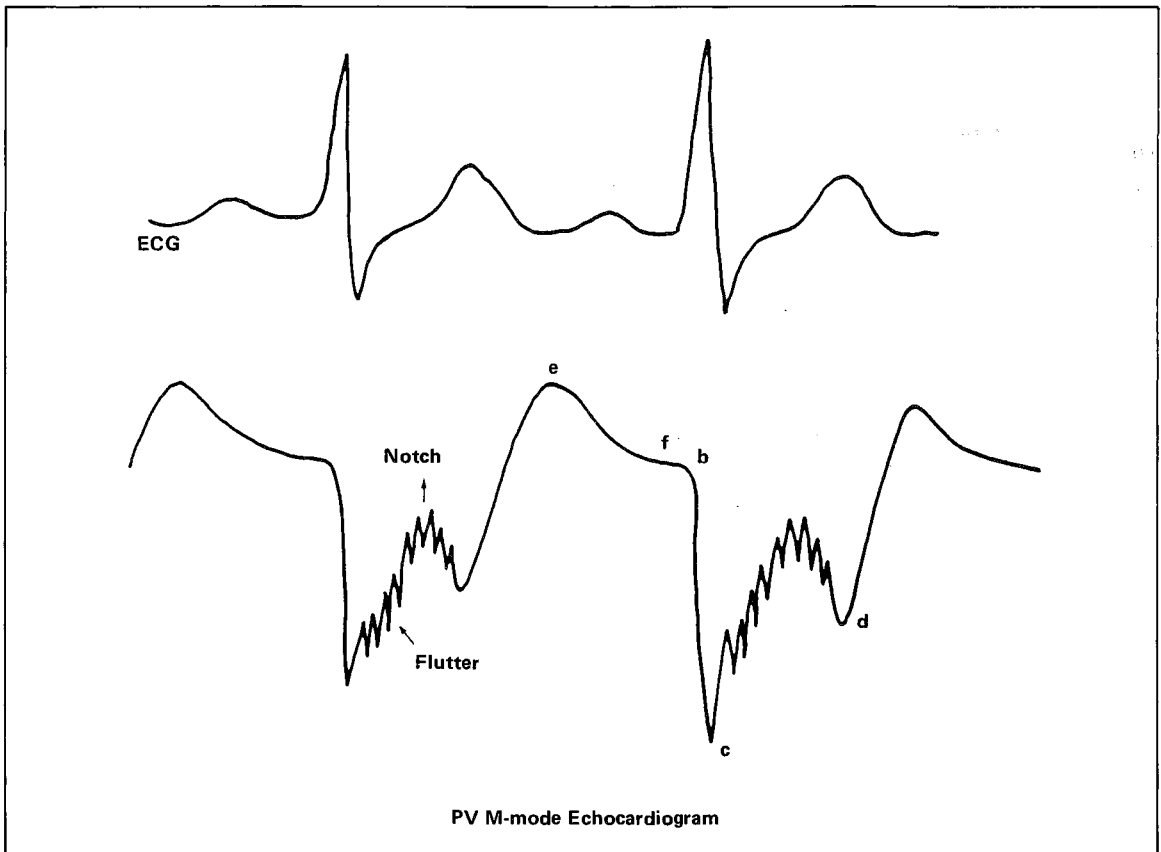


Fig. 2 A diagrammatic illustration of PV echocardiogram with absent a-dip, systolic fluttering and notch as noted in patient with pulmonary arterial mean pressure of  $> 50$  mmHg.

with significant raised PAMP (group C) demonstrated these features.

In group B, the three patients that demonstrated systolic fluttering had PAMP of 30 mmHg and 36 mmHg. There were two patients with PAMP of 42 mmHg and 30 mmHg who had mid-systolic closure of the pulmonary-valve.

## DISCUSSION

It is usually difficult to obtain complete recordings of the pulmonary valve echocardiogram. However the diastolic and early systolic portion may be satisfactorily recorded with experience. Pulmonary valve motion patterns usually become more readily visualised in patients with elevated pulmonary artery pressures as echocardiographic windows are available due to dilation of the pulmonary artery.

The changes in pulmonary valve motion patterns are known to be affected by such variables as respiration, heart rate, increased right ventricular end-diastolic pressures, left atrial volume changes, and transducer placement. In spite of these difficulties, the echocardiographic study of the pulmonary valve motion when interpreted together with the clinical findings may provide valuable information as to the pulmonary haemodynamics as is demonstrated in this study. As have been observed in previous studies, characteristic alterations in the pulmonary valve echocardiogram were noted in pulmonary artery hypertension.

In seven of 14 patients with normal pulmonary mean pressure, no a-dip was recorded. Six of these patients had atrial septal defects. Nanda *et. al.*,<sup>6</sup> Weyman *et. al.*,<sup>2</sup> found that a-dip is 2 mm in all their normal patients. Pocoski and Shah<sup>7</sup> showed 72% of their subjects with normal pulmonary mean pressure also had  $> 2$  mm a-dip. As our study is of patients with intracardiac shunts, it may indicate that the pulmonary valve a-dip variation might be due to other variables such as left atrial size and stroke volume as suggested by Pocoski and Shah.<sup>7</sup> Hada *et. al.*,<sup>5</sup> concluded that the a-dip is influenced mainly by right heart diastolic haemodynamics. As a general observation, there is

definitely reduced or absent a-dip ( $0.8 \pm 1$  mm,  $p < 0.001$ ) in our patients with pulmonary artery mean pressure of 50 mmHg.

A b-c slope of greater than 330 mm/sec in elevated pulmonary artery mean pressure has been reported.<sup>3</sup> A number of studies<sup>2,5,7</sup> were unable to confirm this feature on echocardiogram (Fig. 3). In this study of patients with shunts, it appears that those with pulmonary artery mean pressure of more than 50 mmHg do have steeper b-c slopes than others with normal PAMP ( $p < 0.001$ ).

A rapid e-f slope has been noted to be rather non-specific in evaluating pulmonary pressure. In this study, when the pulmonary mean pressure was in excess of 50 mmHg, we found a reduced e-f slope ( $p < 0.01$ ). In patients with normal pressure there was poor correlation ( $p > 0.05$ ). This might suggest that some other underlying factors may influence the e-f slope and that it is not an indicator of pulmonary artery pressure as claimed by Pocoski and Shah.<sup>7</sup>

The mid-systolic closure of the pulmonary valve is generally regarded as the most important echocardiographic feature of significant pulmonary hypertension. However there are a few reports<sup>8,9</sup> of mid-systolic closure occurring in patients with normal pulmonary artery mean pressure. In our study the most striking pulmonary valve appearances were the presence of both systolic flutter and mid-systolic closure in patients with pulmonary artery mean pressures above 50 mmHg.

In most reports, either one of these features were noted and the frequency of both being present was less. We noted with interest the presence of both features in all four patients with patient ductus arteriosus with pulmonary hypertension and five patients with Eisenmenger syndrome, all of whom had pulmonary artery mean pressure in excess of 50 mmHg.

This study confirms the previous observation that M-mode pulmonary valve echocardiograms

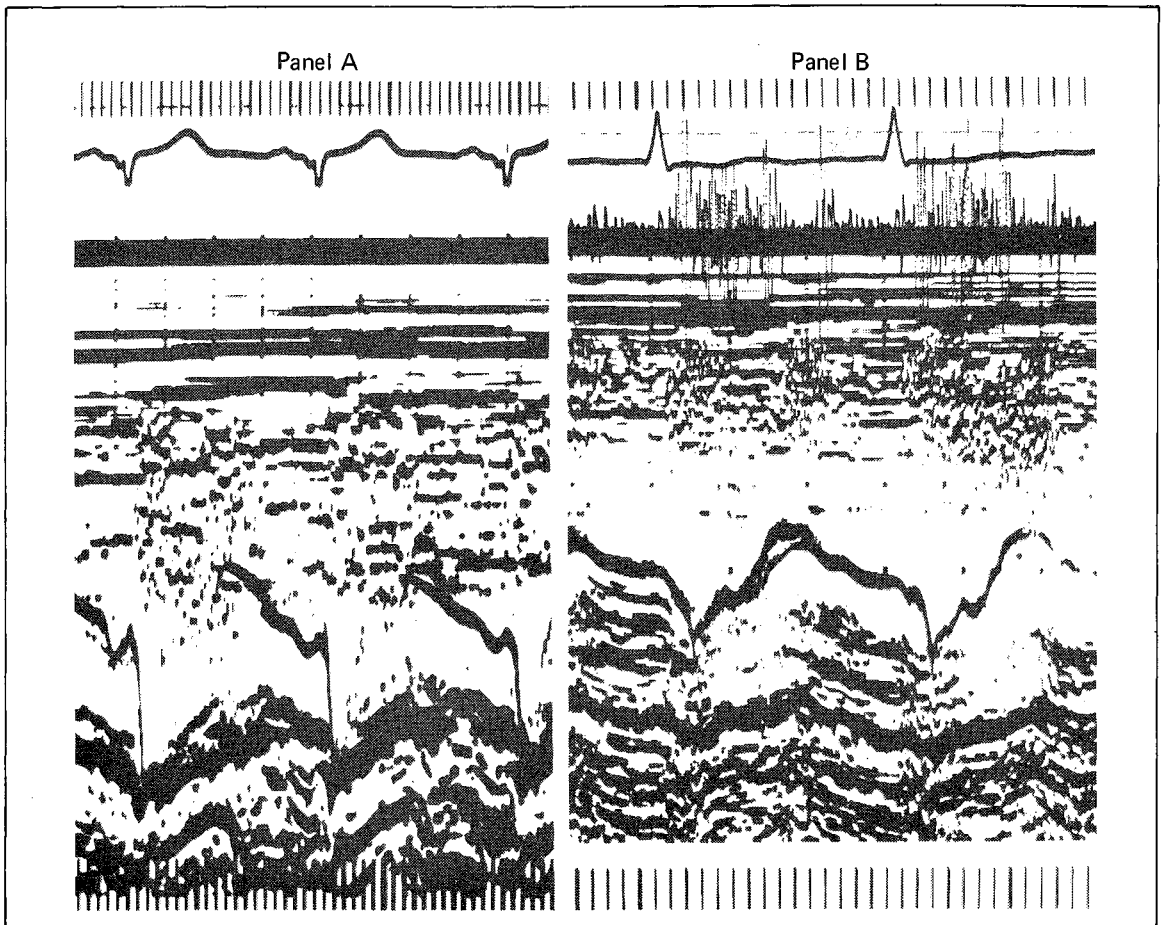


Fig. 3 Pulmonary valve echocardiogram in panel A shows an e-f slope of 28 mm/s, 3 mm a-dip and b-c slope of 480 mm/s in a VSD patient with PAMP of 18 mmHg. Panel B shows absence a-dip and presence of mid-systolic notch with fine fluttering in another VSD patient with PAMP of 52 mmHg. Despite of a raised pressure the e-f slope remained rather steep and b-c slope was not significantly steeper. (VSD = ventricular septal defect, PAMP = pulmonary artery mean pressure.)

may be of clinical use in evaluating pulmonary artery hypertension whether in the presence or absence of intracardiac shunts.

The echocardiographic features under consideration although useful in assessment of pulmonary artery hypertension in patients with shunts, are of limited value in predicting accurately the degree of pulmonary artery hypertension. The only consistent feature that appears to predict a pulmonary artery mean pressure in excess of 50 mmHg is the occurrence of mid-systolic closure with fluttering of the pulmonary valve.

## REFERENCES

- <sup>1</sup> Gramiak R, Nanda N C, Shah P M. Echocardiographic detection of pulmonary valve. *Radiology* 1972; 102 : 153-157.
- <sup>2</sup> Weyman A E, Dillon J C, Feigenbaun H, Chang S. Echocardiographic patterns of pulmonary valve motion with pulmonary hypertension. *Circulation* 1974 : 50 : 905-910.
- <sup>3</sup> Lew W, Karlner J S. Assessment of pulmonary valve echogram in normal subjects and in patients with pulmonary artery hypertension. *Br Heart J* 1979; 42 : 147-161.

- <sup>4</sup> Weyman A E. Pulmonary valve echo motion in clinical practice. *Am J Cardiol* 1977; 62 : 843–855.
- <sup>5</sup> Hada Y, Sakamoto T, Hayashi T, Ichiyasu H *et. al.* Echocardiogram of normal pulmonary valve. Physiological data and effect of atrial contraction on the valve motion. *Jpn Heart J* 1977; 18 : 421–433.
- <sup>6</sup> Nanda N C, Gramiak R, Rabinson T I, Shah P M. Echocardiographic evaluation of pulmonary hypertension. *Circulation* 1974; 50 : 575–581.
- <sup>7</sup> Pocoski D J, Shah P M. Physiologic correlates of echocardiographic pulmonary valve motion in diastole. *Circulation* 1978; 58 : 1064–1071.
- <sup>8</sup> Kaku R, Neumann A, Bommer W, Weinert L, *et. al.* Sensitivity and specificity of the pulmonary valve echogram in the detection of pulmonary hypertension (abst). *Am J Cardiol* 1978; 41 : 436.
- <sup>9</sup> Bauman W, Wann L S, Childress R, Weyman A E, *et. al.* Mid-systolic notching of the pulmonary valve in the absence of pulmonary hypertension. *Am J Cardiol* 1979; 43 : 1049–1052.