

INFANTILE COXA VARA

K. S. DHILLON

SUMMARY

Infantile or developmental coxa vara is a relatively infrequent localised dysplasia of unknown etiology which usually presents in the second or third year of life soon after the child begins walking. The clinical and radiological picture is usually characteristic especially when seen early. Early surgery leads to a satisfactory outcome. However, difficulty arises in diagnosis and treatment when patients present late. Three cases diagnosed in adolescence at the University Hospital, Kuala Lumpur over the last 10 years are presented to increase awareness of this condition, which may be underdiagnosed, and the difficulties in diagnosis and treatment with late presentation are stressed.

INTRODUCTION

The normal neck shaft angle is 150° in a newborn, 126° in the adult, and 120° in the aged. This gradual decrease in the neck shaft angle with age is thought to be due to the relative difference in growth rate between the greater trochanter and the femoral neck, and by the muscular and gravitational forces which act on the proximal femur. Coxa vara refers to an abnormal decrease in the neck shaft angle and may be caused by various congenital or acquired conditions. It is important to find the cause of the deformity as that determines the prognosis, likelihood of associated conditions and orthopaedic management.

Infantile or developmental coxa vara is a localised dysplasia of unknown aetiology which is not evident

at birth and is believed to be due to a developmental abnormality which presents at second or third year of life.

Clinical presentation

Diagnosis is by radiography which shows the characteristic features described by Fairbank¹ and includes: a decreased neck shaft angle to less than 110° ; a wide vertically-aligned epiphyseal plate; an irregular metaphyseal ossification; a shortened femoral neck; a triangular osseous fragment adjacent to inferior margin of the physis; a normal but osteoporotic femoral head; and a straight femoral shaft.

Infantile coxa vara should be excluded if radiographs show abnormalities of the acetabulum or capital femoral epiphysis, femoral bowing, excessive femoral shortening or fibular hypoplasia. Coxa vara may be associated with metaphyseal or epiphyseal dysplasia which involves other joints and with biochemical abnormalities e.g. rickets. These should be excluded by appropriate investigations.

CASE HISTORY

Case 1

A 19-year-old Chinese female presented with pain in the left hip following a trivial injury a week prior to admission. Examination revealed shortening of the left lower limb by 5 cm with gross and painful limitation of abduction and internal rotation. She also confessed to having a limp since her early days in school. She had associated pain, off and on, on exertion.

There was no history of significant trauma or infection requiring hospitalization in the past. Radiograph (Fig. 1) of the left hip showed marked coxa vara with a neck shaft angle reduced to 60° ; an osteoporotic head lying in the interior part of the acetabulum and separated

K. S. Dhillon, FRCS (Edin)
Lecturer, Department of Orthopaedic Surgery
Faculty of Medicine
University of Malaya
59100 Kuala Lumpur, Malaysia

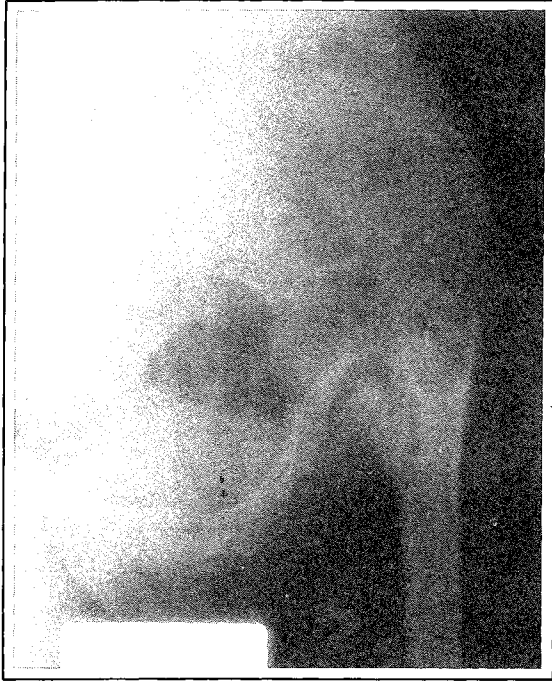


Fig. 1 A pre-operative radiograph of Case 1, left hip joint showing marked coxa vara, a vertical pseudoarthrosis and beak shaped high riding trochanter.

from the neck of femur by a vertical gap denoting a pseudoarthrosis, and a high riding beak-shaped trochanter lying close to the ilium. No other skeletal abnormalities were detected. All biochemical tests, including levels of calcium, inorganic phosphate and alkaline phosphates were normal.

A closing wedge valgus osteotomy was carried out using a 130° fixed angle A.O blade plate for internal fixation, without any external immobilization. Post operative course was uneventful. When the osteotomy had united, the fixed angle A.O plate was removed at four months post-operatively and two A.O cancellous screws were inserted, since the neck was osteoporotic.

When last seen four years after the operation, she had full flexion, abduction 45°, adduction 45° and internal rotation 30° and external rotation of 45°. She was able to squat, run, climb stairs and walk without obvious limp. There was no pain in the hip. Shortening has been reduced to 1 cm; X-ray of the hip showed a relatively well formed head with neck shaft angle of 126° (Fig. 2) with union of the previous pseudoarthrosis.

Case 2

A 16-year-old Chinese male presented in October 1982 with a history of limp for several years and an

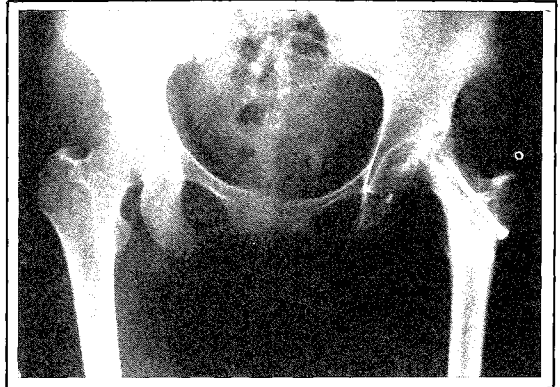

Fig. 2 A post-operative radiograph Case 1. Left hip after osteotomy had united, fixed angle plate removed and cancellous screws inserted to protect the osteoporotic neck. A well corrected neck shaft angle is shown.

occasional pain in the left hip brought on by exertion or minor trauma. He had no history of significant trauma or infection needing hospitalization. All other joints and bones were normal on examination except the left hip joint. Examination of the left hip showed 3 cm femoral shortening; flexion was 90°, abduction 0°, adduction 30° with severely limited rotation.

Radiographs showed a marked coxa vara with a neck shaft angle reduced to 90° with a vertical pseudoarthrosis and proximal migration of the greater trochanter (Fig. 3).

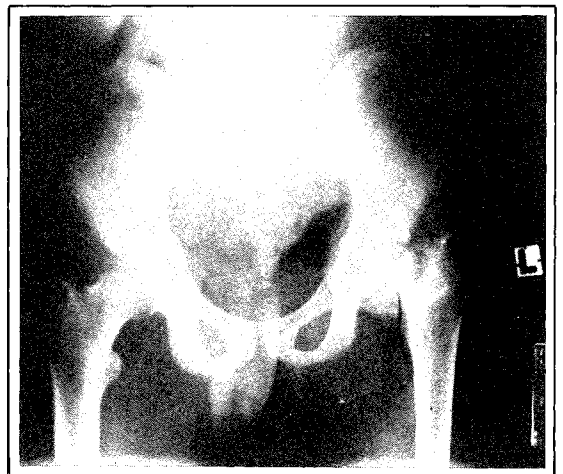


Fig. 3 A pre-operative radiograph of Case 2 with coxa vara and a vertical pseudoarthrosis.

A valgus osteotomy was carried out. Fixation was with a 130° fixed angle A.O blade plate. Three months following osteotomy the pseudoarthrosis had united and the neck shaft angle had improved to 120° (Fig. 4). Range of hip movements were full in flexion, abduction. External rotation and internal rotation was about 25°. Shortening was reduced from 3 cm to 0.5 cm.

Case 3

A 13-year-old Indian female presented in March 1984 with complaints of a limp and pain in the right hip on weight bearing for several years. There was no history of any significant trauma or infection needing hospitalization. Examination revealed a 4 cm shortening with range of motion in right hip reduced to flexion of 100°, abduction of 20°, adduction 30°, internal rotation 15° and external rotation 20°. Examination of the other joints was normal.

Radiograph (Fig. 5) showed, as in Case 1, a small head situated inferiorly in a shallow and rather vertical acetabulum. Trochanter was beak-shaped and lying close to the ilium. The spiphyseal line was vertical and appeared as a pseudoarthrosis. The neck shaft angle was reduced to 60°. In all three cases, the triangular fragment classically described was not identified even with tomograms.

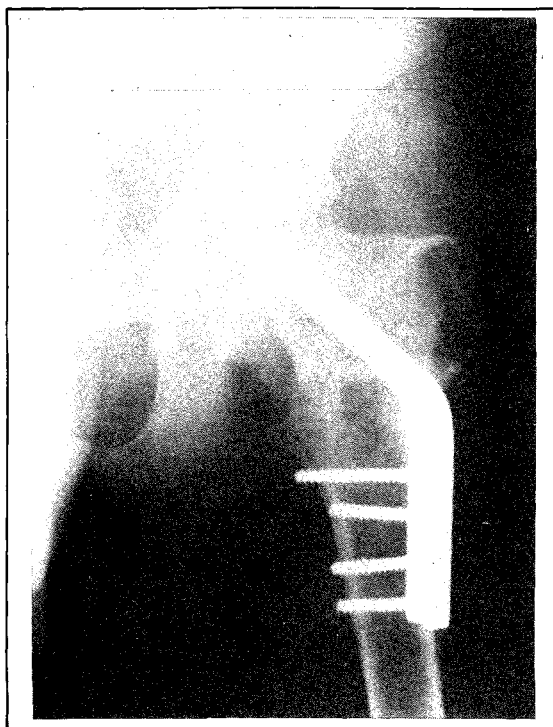


Fig. 4 A post-operative radiograph of Case 2, with pseudoarthrosis and osteotomy united and a corrected neck shaft angle.

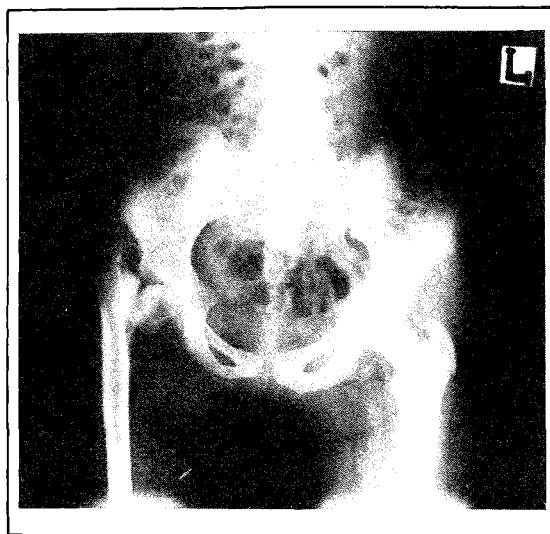


Fig. 5 A pre-operative radiograph of Case 3, right hip showing coxa vara, vertical pseudoarthrosis and a beak shaped high riding trochanter.

In this case a Pauwel's osteotomy was carried out and fixed with a 130° angled blade plate (Fig. 6). When seen last, 12 months after the operation, she had 1 cm shortening with full flexion, adduction of 35°, abduction 35°, internal rotation 25°, external rotation of 35°. She had no pain and the limp was inconspicuous. She was able to squat, run and climb stairs without difficulty.

DISCUSSION

Hofmeister in 1894 is generally credited for coining the term 'coxa vara'.² In 1896, Kreder³ gave the first detailed description of congenital coxa vara. In 1899, Whitman made an impassioned plea for a more careful classification of coxa vara on the basis of aetiology. Acquired coxa vara is a common deformity and may be due to a variety of causes. Infantile coxa vara, also known as developmental or congenital coxa vara, is a condition of unknown aetiology and there is no universal agreement as to the cause. Pouzet and Duncan⁴ held that the condition is the result of a developmental error. Various other theories have been put forward but the most attractive is that of Nilsson,⁵ who suggested that it is due to embryonic vascular disturbance. The modern tendency is to explain infantile coxa vara as a post-natal aseptic necrosis of the femoral neck and this condition should be differentiated from coxa vara associated with other conditions.

The condition is rare and few large series have been reported. Mesurier⁶ reported one case for every 13 cases of congenital dislocation of the hip and calculated the incidence to be 1 in 25,000. At the University Hospital,

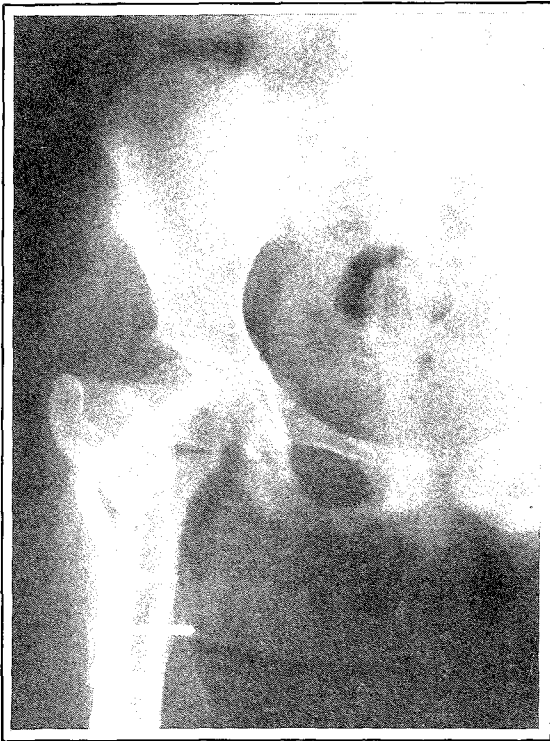

Fig. 6 A post-operative radiograph of Case 3, the pseudoarthrosis and osteotomy has united and the neck shaft angle corrected.

Kuala Lumpur, these have been the only three cases over the last ten years. Obviously many more never seek treatment. Some may be diagnosed as an old septic arthritis and treated conservatively.

Classically this condition presents in the third or fourth year of life as a painless limp. As children reach adolescence and adulthood, the limp worsens and becomes painful especially after minor trauma. Later pain becomes constant due to degenerative changes in the hip joint. All our cases presented in adolescence, as the mild limp in the earlier years was ignored because of absence of pain. As the limp became worse, associated with repeated episodes of pain, then only did the patients seek medical help.

Physical examination reveals some shortening, proximal migration of the trochanter, a positive Trendelenberg sign with limitation of hip movements especially abduction and internal rotation.

Radiographic examination in all the three cases showed a vertically disposed pseudoarthrosis but the triangular fragment or inverted Y-shaped epiphyseal line which is classically described was not seen in our cases because by adolescence the triangular fragment gets attached to the

distal fragment of the neck. In such cases, the diagnosis can be confused with old septic arthritis of the hip leading to pathological separation of the epiphysis.

However, in septic arthritis the head may become avascular and disappear or there may be no connection between the head and the rest of the femur. Fracture neck of femur with non union should also be kept in mind. However, all these conditions may be excluded by a carefully-taken history. There is nothing characteristic of the microscopic appearance of the defect in the neck.⁷ It usually shows normal bone, cartilage and fibrous tissue as was the case in our three patients.

Congenital coxa vara was originally considered hopeless. If untreated, ossification rarely occurs and the condition proceeds to the established non union and the usual sequelae results in disruption of the hip joint, including arthritis, pain and increased disability.

In earlier days conservative attitude was adopted by Barr⁷ and by Nilssonne.⁵ They advocated non-weight bearing with limb in wide abduction or under traction. Barr suggested a Brackett type of reconstruction after puberty.

However, over the years, a subtrochanteric valgus osteotomy has become a standard mode of treatment with satisfactory results. In all our three cases, osteotomy was fixed with an angle plate and has uniformly produced prompt union of the pseudoarthrosis without any form of external immobilization. The rationale of this operation is that the vertical defect is made horizontal with a valgus osteotomy to reduce the shearing forces at the pseudoarthrosis.

In two of our patients where the neck shaft angle was 60° and trochanter had migrated proximally, correction was impossible without extensive soft tissue release. Adductor release is essential but in these two cases an abductor release had to be carried out. Occasionally iliopsoas tenotomy may be necessary. In spite of extensive soft tissue release, function of the hip was not affected as within six months, reattachment and compensation occur.

ACKNOWLEDGEMENT

The author wishes to thank Associate Professor (Dr) S. Sengupta for his assistance in preparing this paper and the Director, University Hospital, Kuala Lumpur, for permission to publish the paper. I would also like to thank Ms Chua for typing the manuscript and Medical Illustration Unit for the illustration.

REFERENCES

- ¹ Fairbank T. Infantile or cervical coxa vara. In Fairbank T, Bristow W R, Platt H (eds). *Robert Jones' Birthday Volume (A collection of surgical essays)*. London: Oxford University Press, 1928: 225-241.
- ² Whitman Royal. Further observation on coxa vara, with particular reference to its aetiology and treatment. *New York Medical J* 1899;69 : 73-81.
- ³ Kredel L. Coxa vara congenital. *Centralbl f chir* 1896; 23 : 969-973.
- ⁴ Duncan G A. Congenital and developmental coxa vara. *Surgery* 1938 ; 3 : 741-765.
- ⁵ Nilsonne Herald. Beitrag ZUR Kenntnis der kongenitalen form de coxa vara *Acta Radiol* 1924;3 : 383-406.
- ⁶ Le Mesurier A B. Developmental coxa vara. *J Bone Joint Surgery* 1948; 30B : 595-605.
- ⁷ Barr J S. Congenital coxa vara. *Arch Surgery* 1929; 18 : 1909-1919.