

ISCHAEMIC GANGRENE OF LEG DUE TO RING CONSTRICTION: A CASE REPORT

C. R. THAMBI DORAI

SUMMARY

An infant with bilateral congenital ring constrictions in the legs presenting with ischaemic gangrene of one leg is reported. The ischaemia was precipitated by greenstick fracture, the constriction ring producing a 'tourniquet effect' on the swollen tissues. Prophylactic release of deep annular constrictions is advised to prevent complications.

INTRODUCTION

Congenital ring constrictions have been recorded in the arm, forearm, wrist and fingers of the upper limb and leg, foot and toes of the lower limb.¹ They may vary in depth from shallow grooves to deep constrictions.¹ Deep constrictions interfere with the lymphatic and vascular circulation in the distal parts of the limb.² This case report illustrates the acute vascular compression they can produce.

CASE HISTORY

A female, Malay infant aged five months was hospitalised with discolouration of the lower third of the left leg and foot for two days. From birth, the infant was noticed to have annular grooves in

both the legs at the junction of the middle and lower thirds. Both feet were said to be slightly swollen from birth (probably due to lymphoedema).

Two days prior to admission, the mother observed that the swelling in the infant's left leg and foot had increased. Within a few hours, the limb below the groove was severely swollen and the infant was referred to the hospital the next day. The mother was unaware of any trauma to the leg.

On admission, the child had low grade fever. The left leg below the constriction was brownish-black in colour, cold, oedematous; the peripheral pulses were not palpable and there was exudation of brownish fluid from blisters in the skin, all indicating moist gangrene due to vascular compression (Fig. 1). The five toes of the left leg were so grossly swollen that their features could not be discerned. The other leg showed a similar ring constriction at the same level with minimal lymphoedema of the foot; there were five toes. The great toe and second toe were short, stubby, and rounded at the tip. There was no syndactyly. The cardiovascular system was normal.

An X-ray of the left leg and foot revealed greenstick fracture of the lower one-third of tibia below the level of the constriction groove with gross swelling of the soft tissues from the constriction below. The annular constriction groove was involving the skin and full thickness

C. R. Thambi Dorai, MS, MNAMS, FRCS
Surgeon, District Hospital
34000 Taiping
Perak, Malaysia

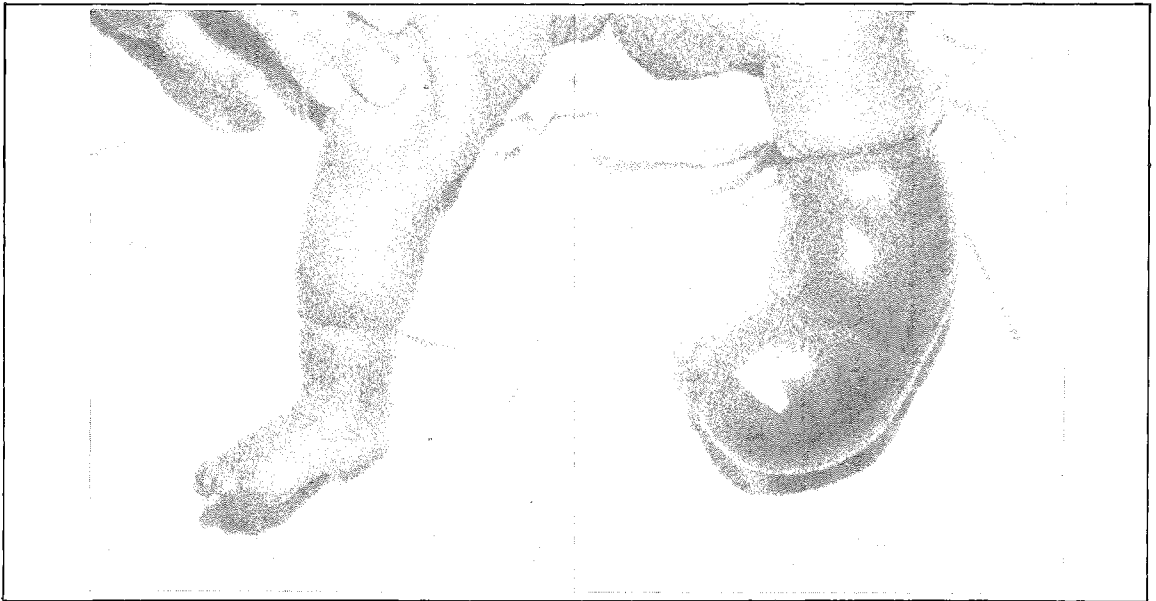

Fig. 1 Bilateral ring constrictions with gangrene of the left leg.

of the subcutaneous tissue. The bones of the left leg and foot were otherwise normal; the ossification centres were consistent with age. An X-ray of the right leg showed a similar ring constriction at the same level. The tarsal and metatarsal bones were normally ossified consistent with age. The great toe showed only the proximal phalanx and this was shorter than normal. The second toe showed only a proximal phalanx of normal length and shape.

The left leg was amputated below the knee, 3.5 cm above the site of constriction, using equal posterior and anterior flaps and myoplastic technique. The wound healed by primary intention.

Two weeks following the amputation, the release of the constriction ring in the right leg by Z-plasty was contemplated. The operation was planned in two stages. In the first stage, Z-plasty was done over the lateral and posterior aspects of the leg. In depth, the ring constriction was involving full thickness of skin and subcutaneous tissue. Flaps including the skin and subcutaneous tissue were raised and Z-plasty was done (Fig. 2).

The sutures were removed on the eighth post-operative day; the wound healed by primary

intention. The Z-plasty for the remaining part of the ring was scheduled six weeks later but the mother was not keen on operation. However the circular disposition of the constriction has been rectified by the first Z-plasty and the oedema in the foot has become less.

DISCUSSION

The aetiology of ring constrictions is unknown.³ The present concept is that they are due to focal defects in the development of the limb leading to circumferential necrosis in the limb.² There is no familial tendency.³

The following anatomical types are described: a simple ring in the skin, often multiple;³ a deeper ring often associated with distal abnormalities, particularly lymphoedema;³ severe constriction ring leading to intrauterine gangrene and amputation² at birth only depressions, grooves or healed stumps with residual strands may remain visible; constriction ring accompanied by distal abnormalities like syndactyly, and this is due to necrosis of tissue and fusion of parts comparable to untreated third degree burns with bridges of scar.²

The treatment of ring constrictions depend on their depth.³ Shallow rings may be excised and

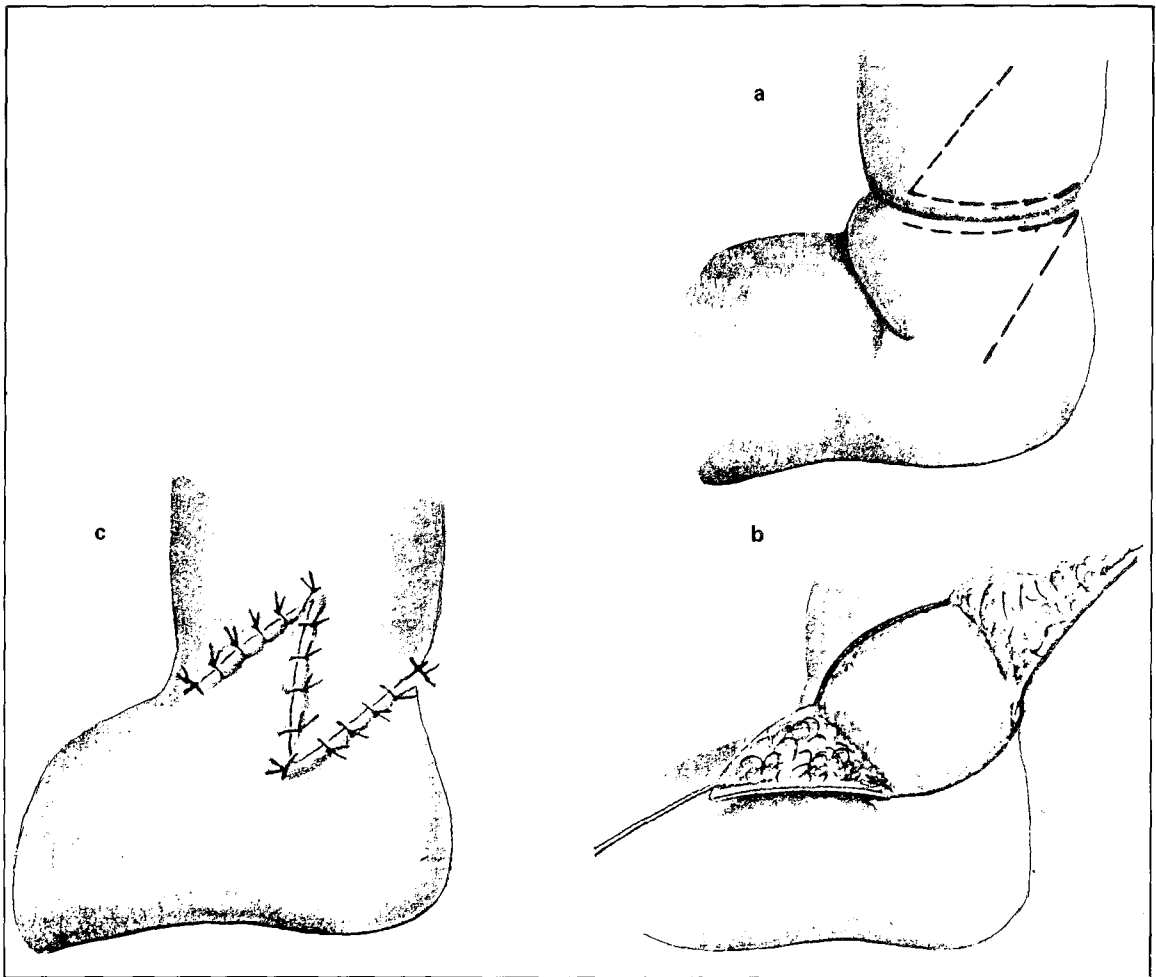


Fig. 2 The technique of Z-plasty.

sutured while deeper rings require staged Z-plasties. Simple excision and suture of deeper rings may result in recurrent contraction of the circular scar. Since the circulation across the ring may be tenuous, the Z-plasty is to be done in stages, dealing with only half of the ring at a time.

This case illustrates the serious complication which can suddenly result from ring constrictions and emphasises the need for early prophylactic treatment of deep ring constrictions, even if asymptomatic.

ACKNOWLEDGEMENT

The author wishes to thank Tan Sri Datuk (Dr)

Abdul Khalid bin Sahan, the Director-General of Health, Malaysia for permission to publish the case report.

REFERENCES

- ¹ Manson Brown J J. *Surgery of childhood* (ed). London: Edward Arnold publications Ltd., 1962:436.
- ² Swanson A B, Barsky A J, Entin M A. Classification of limb malformations on the basis of embryological failures. *Surg Clin N Amer* 1968; 48 : 1169–1179.
- ³ Patterson T J S. Ring constrictions. In: Charles Rob, Rodney Smith (eds). *Operative Surgery: Paediatric Surgery*. London: Butterworth, 1978; 377–379.