

CONGENITAL DIAPHRAGMATIC HERNIA- THE CLASSICAL TYPE: A CASE REPORT

V. VENKATESWARAN

SUMMARY

A case of classical congenital diaphragmatic hernia is discussed. The rare right-sided classical type – incidence of 1 in 30,000 to 1 in 81,000 live births – and diaphragmatic eventration are often grouped together as Congenital Diaphragmatic Herniae. We had nine in 57,783 live births in ten years.

Viscera occupying the hemithorax causing irritation, distorted superior and inferior vena cavae, overdistended lung with return to persistent (primitive) fetal circulation, ipsi, bi and contra-lateral pneumothoraces, and twisted liver lobes precipitate acute cardiac failure, complicating the urgent surgical intervention.

CASE REPORT

A congenitally cyanotic, bradycardiac, 2.4kg male child was delivered at Toa Payoh Hospital, with laboured respiration, chest retraction, poor right-sided air entry, transilluminant right lower

V. Venkateswaran, MBBS, MRCS, LRCP
DARCP&S, FFARCS
Department of Anaesthesia
Toa Payoh Hospital, Toa Payoh Rise
Singapore 1129

Reprints: Dr. V. Venkateswaran, Department of Anaesthesia, Kandang Kerbau Hospital, Singapore 0821

chest. Intubation with a 3mm portex endotracheal tube, and ventilation with a 20cm pressure and +2PEEP achieved air entry on the left side only; the radiograph (Fig. 1) confirmed a classical right diaphragmatic hernia. Intravenous bicarbonate and dextrose controlled the respiratory and metabolic acidoses.

Ventilating 35-40min at 2.4l per min readjustment of the tube allowed a leak and some right sided aeration. "Thumbing" was done with an Ayre's T-piece system, with a 1cm diameter 10ml expiratory limb, fresh gas flow directed towards the patient. Precordial stethoscope,

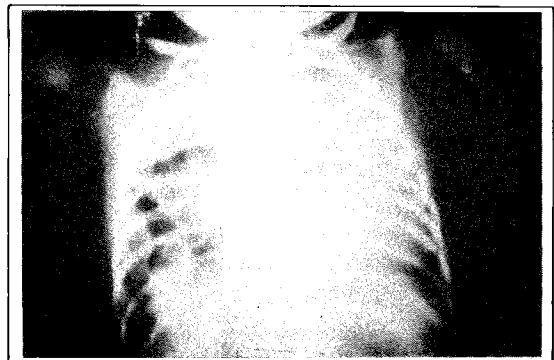


Fig.1a Radiography soon after birth shows air-filled viscera in the right hemithorax, with deviation of the mediastinum (note the stomach tube and the endotracheal tube) and crowding out of the opposite hemithorax. The bubble of air below the diaphragm shows an erect intra-abdominal stomach.

ECG, rectal thermometry continuously monitored the parameters. Ketamine 4mg, pancuronium 0.2mg and 0.1mg 75 min later were administered for a two-hour anaesthetic, starting seven hours after birth. Warmed paediatric dextrose saline over two hours and warmed blood 15ml over 25min, were transfused for a blood loss of 20ml (measured with a side test-tube attached to the paediatric sucker). Postoperatively air entry was less on the right.

A subcostal laparotomy showed a 7cm right hemidiaphragmatic defect with defined anterior and posterior rims. The hernial sac contained small gut, lobe of a dumbbell-shaped liver, caecum, colon; a right hypoplastic lung and a small left pneumothorax were encountered. Retrieving the viscera abdominally, excising the dissected hernial sac, the diaphragmatic defect was closed. 30ml of air was aspirated from the right chest, before closure and no chest drain was inserted. Air was injected into the left chest allowing the lung to fall away from the pleura, during chest tube insertion into the left side.

Postoperatively in the neonatal ICU ventilating with +2PEEP, ECG, temperature, oxygen percutaneously, were monitored. Chest drain was inserted for a right pneumothorax (Fig. 2), which occurred while in the ICU, in addition to the chest tube inserted into the left-side while in the operating theatre.

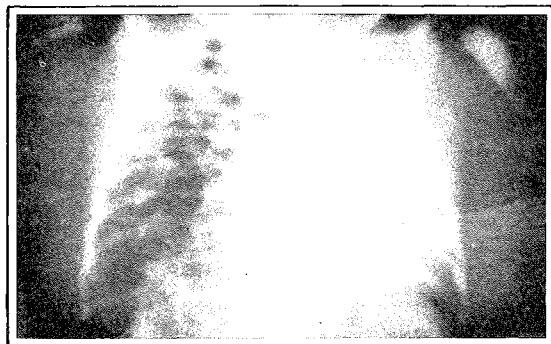


Fig.1b After a few hours the distension of the viscera is more and there is more deviation of the mediastinum.

24 hours postoperatively, the child was restless, cyanotic, acidotic and hypoxic though breathing spontaneously. Changing the endotracheal tube, FIO_2 to 0.8 with PEEP, the PAO_2 was only 47mm with a tachycardia, but became bradycardiac. Despite manual ventilation hardly any chest movement occurred. The child died 26 hours postoperatively.

A postmortem bronchogram (Fig. 3) visualised well, the left lower, right lower, middle, partially the left upper and unexpanded right upper lobe, with no tracheal obstruction.

DISCUSSION

In the intrauterine eighth to tenth week, the foregut mesentery forms the crura, septum transversum the central tendon, and the anterior diaphragm forms before the posterior portion. Pleuro-peritoneal communication is posterolateral. Failure of pleuro-peritoneal canals closure, often due to agenesis of diaphragmatic leaves, causes the classical type (anteriorly Morgagni, posterolaterally Bochdalek), where viscera herniate with the peritoneum as hernial sac and the rim as the hernial ring. In "aftercoming head of the breech" (associated with Erb's palsy and sternomastoid tumour), the baby's shoulder pressure weakening the developing diaphragm, failure to mesodermise or muscularise causes eventration — peritoneal covered viscera through a membranous diaphragm. Ramakrishnan¹ had 147 eventrations to 86 classical types. Five times commoner on the left,

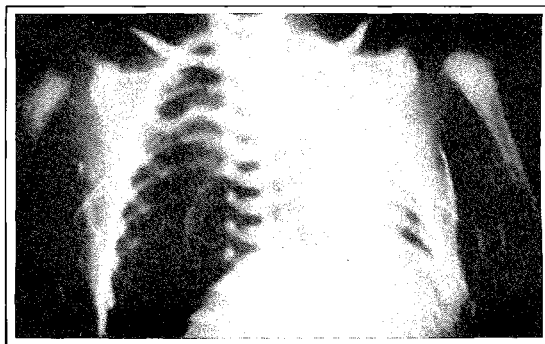


Fig. 2 Chest tubes are in place in both hemithoraces (left side inserted in the operating theatre, right side in the ICU). Shadow of the hypoplastic lung is seen.

it is twice commoner in males. Only 16-18 bronchiolar generations develop against the normal 22. Alveolar sacs are also reduced.² The respiratory distress may be due to the pulmonary hypoplasia (Fig. 3), weighing as low as 2g compared to the normal 17-35g; often even the contralateral lung is 10% lighter than normal. The hypoplasia which is of prognostic value, depend on the intrauterine period of herniation. Associated cardiac pathology of 23% and intestinal malrotations of 50% have been reported; Dierdoff Stephan states that the thickened pulmonary arteriolar muscles cause pulmonary hypertension,² even contralaterally. Renal abnormalities are rare though sequestered lung lobes are reported.

If the ARDS and surgery are within four hours the mortality is high. There is a 33% survival after surgery if done within first 24 hours, the mortality is in the fifth group. There is a high survival rate for those requiring surgery after the third day.

The acute and subacute types are diagnosed at birth, or within a few days; the chronic type presents with failure to thrive or lung infections.

The hyporesonant ipsilateral chest with absent breath sounds, becomes hyper-resonant with visceral distension, causing mediastinal shift and dullness contralaterally (Fig. 2). Cardiac failure,

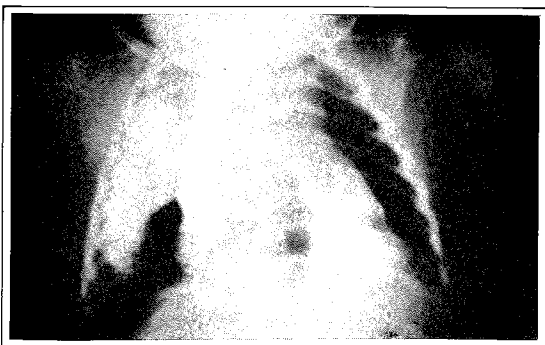

Fig. 3 The bronchogram visualises the lower lobe of the left lung, lower and middle lobes of the right lung with the right upper lobe partly visualised.

pulmonary aspiration, right to left shunting occur. Loops of gut are confused with lobar emphysema (Fig. 1). Contrast studies show an intra-abdominal erect stomach.¹ In eventration an inverted stomach with thin diaphragmatic outline is likely.

Awake intubation, an intentional leak, gastric suction (possibly blown-up during resuscitation), correction of acidoses, elevation of normal side minimising mediastinal distortion by the affected side facilitate anaesthesia. Halothane, ketamine with 100% oxygen without nitrous oxide reduces 'closed space effect'. Pancuronium or atracurium is recommended. There are advocates for the use of Fentanyl and dehydrobenzperidol. "Thumbing" gives a continuous assessment of the changing compliance. Ventilating 30-35/min, with 3.14 times the minute volume is recommended. A catheter alongside the viscera to release any suction effect in the hemithorax during retrieval is advisable. An electively created ventral hernia accommodates the retrieved viscera. Postoperative ventilation with PEEP is necessary; CPAP hastens weaning. Dexamethasone and antibiotics minimise infection and glottic oedema. Sudden hypoxia, acidosis, deterioration and death are often due to pulmonary hypertension, caused by pulmonary arteriolar muscle walls in spasm, overdistension of healthy lung with blood and resultant right to left shunting, overtransfusion and flooding the pulmonary side *via* a patent foramen ovale or ductus arteriosus. Some suggest surgical closure of the patent ductus but then a fatal diastolic hypertension should be anticipated. The ipsilateral lung expands within three days. Pulmonary hypertension is treated with simultaneous dopamine administration for systemic circulatory support. Transient³ improvement in oxygenation – "honeymoon period" – is prognostically good.

CONCLUSION

Acute cardiac and respiratory failures are the two main causes of mortality and their anticipation and management of a team of paediatrician, surgeon, and anaesthetist experienced in neonatology are vital.

REFERENCES

- ¹ Ramakrishnan M S. Eventration of diaphragm. *Ann Acad of Medicine – Paediatric Surgery* 1981; 10:4.
- ² Dierdorf Stephan F, Krishna Gopal. Anaesthetic management of neonatal surgical emergencies. Review article. *Anaesthesia and Analgesia* 1981; 60:4.
- ³ Bloss R S, Turmen T, Peardmore H E, Aranda J V. Tolazoline therapy for persistent pulmonary hypertension after congenital diaphragmatic hernia repair. *J Paed* 1980; 97:984–988.