

# INTRACRANIAL MENINGIOMAS: A REPORT OF 13 CASES

KAZEM DJAVADKHANI  
HALILI RAHMAT

## SUMMARY

*This is a report of 13 cases of meningiomas treated in the Neurosurgical Unit, Universiti Kebangsaan Malaysia, General Hospital, Kuala Lumpur, over a period of nine months from September 1982.*

## INTRODUCTION

Meningiomas are histologically benign tumours that arise from arachnoidal cells. They are the second most common primary intracranial tumours in adults. Their peak incidence is in the fourth and fifth decades and, unlike other primary brain tumours, meningiomas occur more commonly in women than in men.

Meningiomas may arise wherever arachnoidal cells are present, but the chief sites of origin

are over the cerebral convexity or base of skull. Meningiomas of the foramen magnum, posterior fossa, or ventricular system also occur but are relatively uncommon.

## MATERIALS AND METHODS

Of the 13 cases observed, nine were Malays, three Chinese, and one Indian. The numbers are too small to draw any conclusion as to the incidence of meningiomas according to the race. Of these, ten were females and three males. The female preponderance is in keeping with other reports.<sup>1</sup> Eight patients were in the fourth and fifth decades of life, three over 50 years of age and two under 20 years of age (Fig. 1). Meningiomas tend to occur between the fourth and fifth decades of life.<sup>2</sup>

## Clinical Features

The common presenting features were as follows: nine patients presented with headache, and eight with visual disturbance, nausea and vomiting. In four, there were convulsions and in two others there were hemiparesis and parathesias. Three patients had symptoms for more than three months, and four for one year before the diagnosis was made.

## Ophthalmologic Findings

Eight patients had bilateral papilloedema, two had bilateral optic atrophy and in three the

---

Kazem Djavadkhani, MD, Dip Neurosurgery (Belg)  
Consultant/Neurosurgeon  
Faculty of Medicine  
Universiti Kebangsaan Malaysia  
50300 Kuala Lumpur, Malaysia

Halili Rahmat, MBBS  
Medical Officer  
Neurosurgical Unit, Department of Surgery,  
Faculty of Medicine  
Universiti Kebangsaan Malaysia  
50300 Kuala Lumpur, Malaysia

---

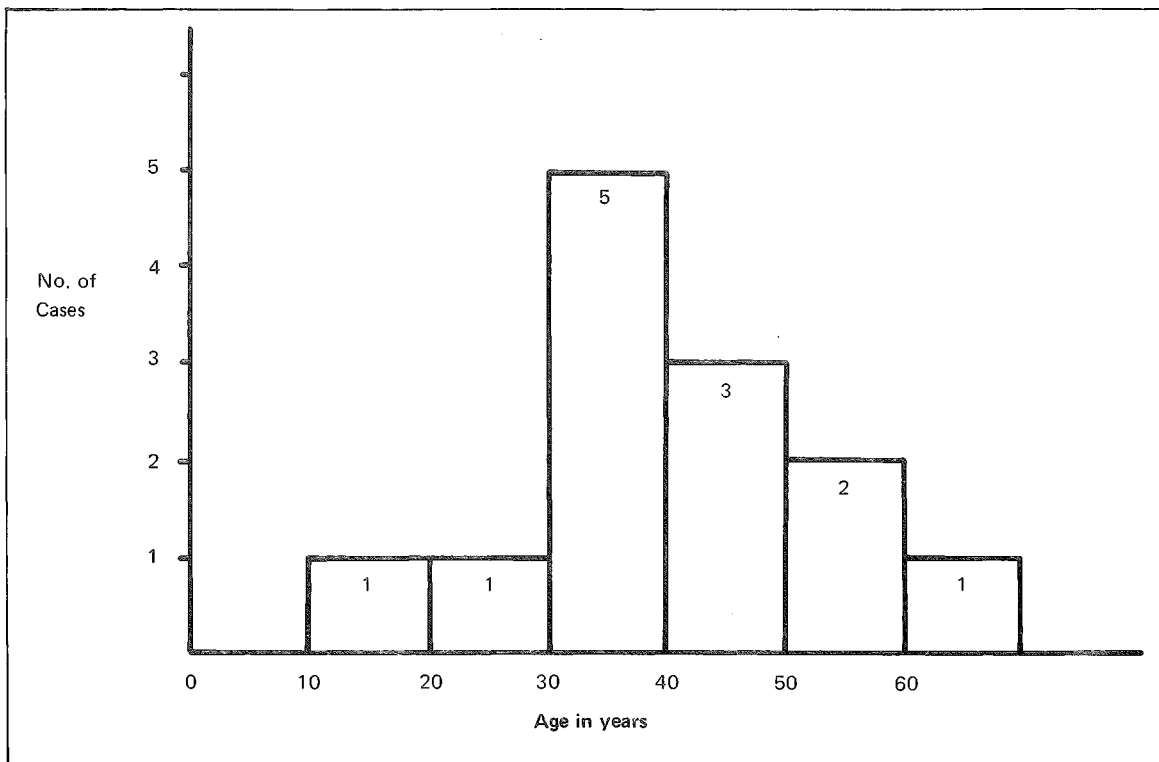


Fig. 1 Age incidence in 13 cases of Meningioma.

fundi were normal. Visual acuity was normal in seven patients, one had moderately reduced acuity and in four this was severely reduced to counting fingers or light perception only. One patient had no perception of light.

**Investigations**

In five patients, plain skull X-ray showed no abnormality. In five patients, there was abnormality of the sella turcica.

Hyperostosis, increase in vascularity and tumour calcification were seen in one case each. Carotid angiography in 11 cases yielded a positive result. In two cases the examination failed because of inability to catheterize the common carotid artery.

In Fig. 2 arteriogram shows accumulation of the contrast medium in a very vascular parasagittal meningioma. The lesion was seen on CAT

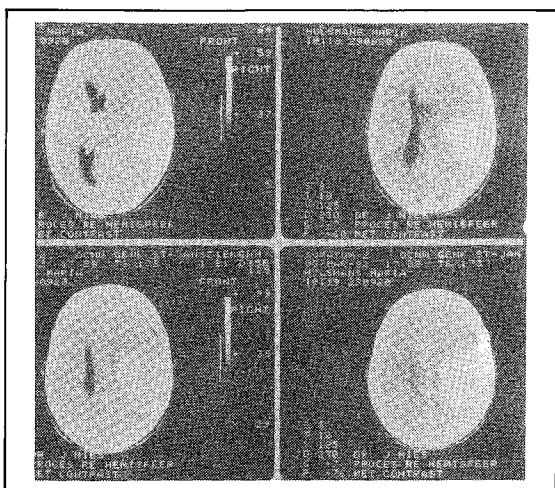
Scan in twelve patients. In one patient this was not done (Fig. 3).

**Anatomical Location of the Tumours**

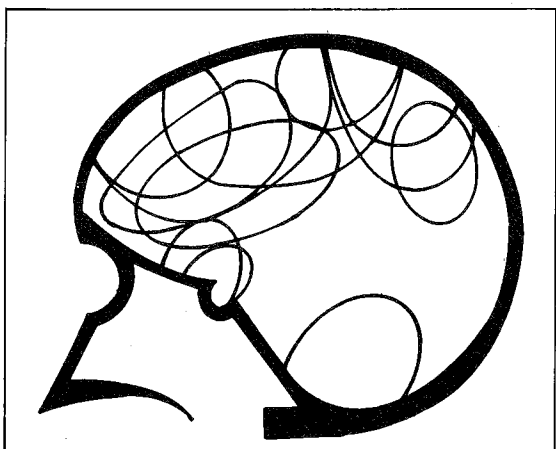
Six cases were convexity meningiomas, four were parasagittal, two were in the tuberculum sella and one in the posterior fossa (Fig. 4).

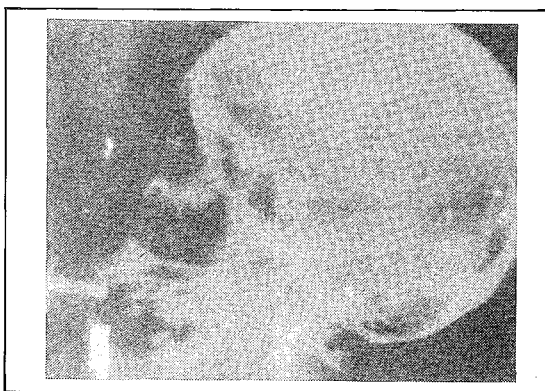

Fig. 2 Arteriogram shows accumulation of the contrast medium in a parasagittal meningioma.



**Fig. 3** Computerised Tomography Scan in a Convexity Meningioma.



**Fig. 4** The Anatomical Distribution of 13 meningiomas.

### Treatment

Craniotomy was performed in all cases. In ten, the tumour was totally removed and in two partial removal was performed at the initial operation followed by total removal at a second operation. One patient has partial removal only.

### Size of the Tumour

In two cases the tumour was less than 6 cm in diameter; in ten cases between 6 to 10 cm in

diameter; in one case, it was over 10 cm in diameter.

### RESULTS

All patients have been followed up for a mean period of 12 months. There has been no recurrence to date. Nine patients had good results and had no residual symptom. In nine patients recovery was uneventful. Eight of these had fundal changes which returned to normal. Three patients had wound infection, one had pneumonia which was successfully treated by antibiotic. Two patients developed post operative hemiplegia which later improved but did not recover completely. There were no deaths.

### DISCUSSION

Meningiomas constitute about 15% of all intracranial tumours, roughly a third of the number of gliomas.<sup>3</sup> They may occur at any age but the peak incidence is in middle age. In contrast to the gliomas they are more common in females than in males.<sup>4</sup>

The simplest form is seen on the convexity of the cerebral hemisphere. The tumour forms a rounded mass, has a precise margin, is clearly demarcated from the brain and is firmly attached to the overlying dura mater.

A meningioma can be expected to recur if removal is incomplete. In general, the recurrent tumour has the same histological appearance as the original specimen. Occasionally, the tumour may show histological evidence of malignancy with an infiltrating margin.<sup>5</sup>

Multiple meningiomas occur in 5% of cases. The microscopic appearances of meningioma are variable. This has led to a multiplicity of classification, and a confusion in terminology. A commonly accepted classification is: meningeal fibroblastoma; lepto meningioma; arachnoidal fibroblastoma; dural endothelioma.<sup>1</sup>

Symptoms and signs of meningiomas are commonly due to raised intracranial pressure as

may occur in any intracranial tumour. The focal neurological symptoms depend on the location of the tumour. Since meningiomas are slow growing tumours the symptoms may be present for a long period of time as occurred in some of these patients.

Plain X-ray may help in the diagnosis. Eight of 13 cases in this study showed radiologic changes. Three of these showed hyperstosis or increased vascularity of the skull. Calcification is highly suggestive of meningioma.

The majority can be diagnosed by carotid angiography or CAT Scan.

## REFERENCES

- <sup>1</sup> Merrit H. *A Text book of Neurology*. Philadelphia: Lea & Febiger, 1975: 241-248.
- <sup>2</sup> Northfield D W C. The Surgery of the Central Nervous System. In *The Meningiomas*. Oxford, London: Black Well Scientific Publications 1973: 229-261.
- <sup>3</sup> Cushing H, Eisenhardt L. *Meningiomas, their classification, regional behaviour, life-history and surgical end result*. Springfield: Thomas, 1938.
- <sup>4</sup> Ehler N, Malmros R. The Suprasellar Meningioma. *Acta Ophthalmol (Copenhagen)* 1973; 25 : 425.
- <sup>5</sup> Martin A, Samuels (M D. *Manual of Neurologic Therapeutics*. Boston: Little, Brown and Company 1978: 219-225.