

# TRUE ANKYLOSIS OF TEMPOROMANDIBULAR JOINT: A CASE REPORT

K. C LING

## SUMMARY

A unilateral true ankylosis of the temporomandibular joint of traumatic origin and of 23 years duration is reported. Its pathogenesis and treatment are discussed.

## INTRODUCTION

True ankylosis of the temporomandibular joint is defined as bony or fibrous union between the joint surfaces. It is not a common disorder. The record at the Department of Oral Surgery of the Faculty of Dentistry, University of Malaya shows only six other cases in the last ten years.

There are several causes of true ankylosis of the temporomandibular joint. Trauma to the mandibular condylar process is the principal cause. The main forms of trauma are intracapsular fracture sustained during a fall or road traffic accident, gunshot injury and forceps injury during delivery.

The following case is reported because of its rarity, the unusually long duration of

ankylosis and the clinical picture which is typical of unilateral ankylosis occurring before adolescence.

## CASE REPORT

A 27-year-old Chinese female saw the author for her inability to open her mouth widely. This disability started in her childhood after a fall when the patient was four-years-old. It got progressively worse until the last few years. The patient had difficulty chewing solid food but had no problem with speech. She also noticed asymmetry of her lower jaw.

Patient's medical history was noncontributory. She appeared to be in good health and well nourished.

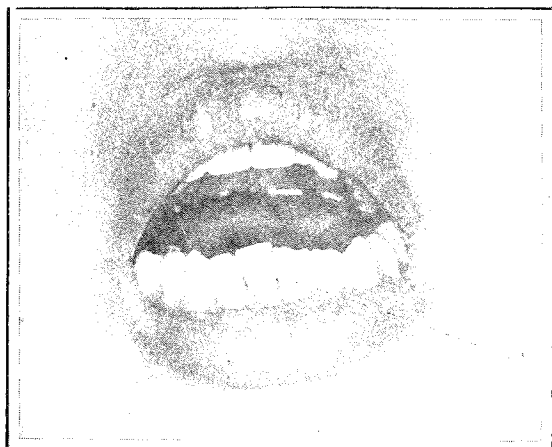
Extraoral examination revealed obvious mandibular asymmetry with the chin deviated to the left side and flattening of the face on the right. The mandible was retrognathic. Mouth opening was 18 mm between the incisal edges (Fig. 1). The chin deviated further to the left on mouth opening. The right condyle was felt to move normally but only minimal movement was detected on the left.

Intraorally, oral hygiene was unsatisfactory. Generalised calculi and multiple grossly carious teeth were seen. A partial upper denture was present.

---

K. C. Ling  
BDS (S'pore), MDS (S'pore), FDSRCS (Eng)  
Department of Oral Surgery  
Faculty of Dentistry  
University of Malaya  
51900 Kuala Lumpur, Malaysia

---



**Fig. 1 Preoperative mouth opening.**

Radiological examination showed incomplete bony union between the articular surface of the left condylar head and the roof of the glenoid fossa. There was also incomplete bony union between the new bone in the lateral aspect of the condylar neck and the new bone arising from the zygomatic process of the temporal bone. The left condylar head appeared medially-displaced.

Routine urinalysis, haematological and biochemical investigations were normal.

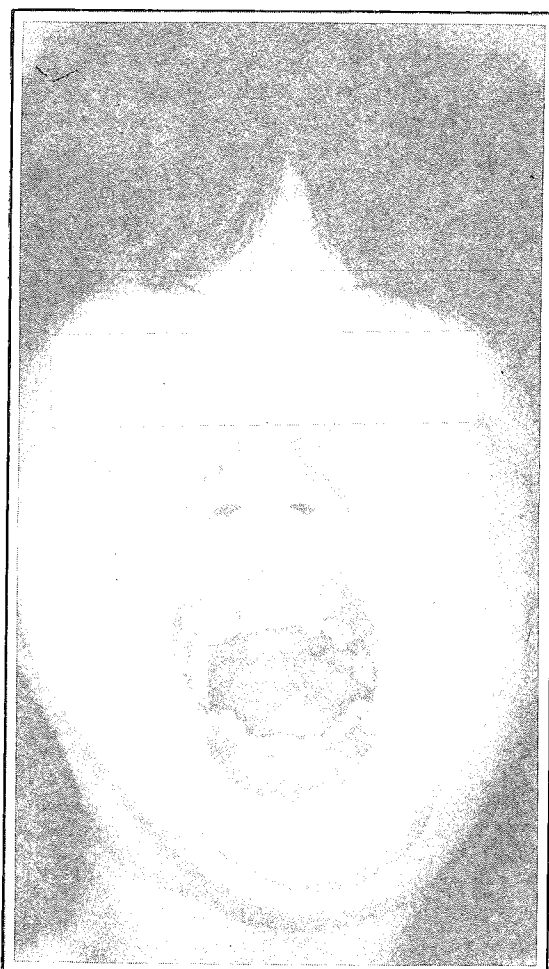
A diagnosis of partial (fibrous) true ankylosis of the left temporomandibular joint was made.

Under general endotracheal anaesthesia and via a preauricular incision, the ankylosed joint was exposed. A horizontal ramus ostectomy was done removing about 3 mm thickness of bone below the coronoid process and the ankylosed condylar process. A medium grade silastic (silicone elastomer) sheet of 2 mm thickness was interposed between the bone ends and secured to the proximal bone end with a 25-gauge soft stainless steel wire. Contralateral coronoidectomy was then performed via intra-oral route. The mouth opening was measured and found to be 35 mm.

The postoperative x-ray showed the silastic sheet to be in good position. Jaw exercise was commenced on the seventh post-operative day by

forcibly opening the mouth with the help of wooden tongue spatulas. Patient was told to increase the number of spatulas daily. The exercise was done three times a day for five minutes each time. After two months, a Robert's jaw exerciser was used instead. Six months after the operation the maximum opening of 35 mm was achieved (Fig. 2). There was no pain or noise on mouth opening and she could eat any type of food. There was some degree of preauricular numbness due most probably to damage to the auriculo-temporal branch of the trigeminal nerve during the operation.

Patient was advised to have secondary genioplasty and osteotomy to correct the



**Fig. 2 Postoperative mouth opening.**

mandibular deformity but she was not amenable to the advice.

## DISCUSSION

The fall at four years of age was the most likely cause of ankylosis in this patient. It is postulated here that there was an intracapsular fracture of the left mandibular condylar process with medial displacement of the condylar head. The ensuing haemarthrosis contained the highly-osteogenic bony fragments. Organization of the haematoma produced the fibro-osseous mass.

MacLennan<sup>2</sup> found that children below the age of five years would appear to be more prone to permanent growth changes following fracture of the condylar process. This was so in this patient. Mandibular deformity following ankylosis was presumably due to irreparable damage to the remodelling capacity of the condyle and not to its inherent growth potential.<sup>2</sup>

Treatment for true ankylosis of temporomandibular joint is surgery. Many surgical techniques have been designed to deal with temporomandibular joint ankylosis. Essentially, there are different forms of arthroplasty which is the creation of either a new joint in the location of the old joint or a false joint in the ramus leaving the pathological joint untouched. In this patient a false joint was created in the ramus near the old joint. This was done because it was difficult and hazardous to free the condyle that had ankylosed

to the glenoid fossa and the zygomatic arch, as the floor of the middle cranial fossa was the roof of the glenoid fossa. Topazian<sup>3</sup> had reported that recurrence of ankylosis was less likely with interposition arthroplasty than with gap arthroplasty. In this case silastic was used with good result.

It is also believed that relapse may be attributed to the failure to recognize post-ankylosis contracture formation in both temporalis tendons. So surgeons advocate bilateral coronoidectomy or temporal myotomy. Bilateral coronoidectomy was done in this patient.

Post-operative daily physiotherapy is of prime importance. Ineffectual physiotherapy can jeopardize an otherwise successful result. The daily dilatation prevents the new joint from tethering down to a limited range of movement because the patient can recover full muscle strength through daily jaw use.

## REFERENCES

- 1 MacLennan W D. Consideration of 180 cases of typical fractures of the mandibular condylar process. *Br J Plast Surg* 1952; 5: 122-128.
- 2 Rowe N L. Ankylosis of the temporomandibular joint. *Jl Royal Coll Surg Edinb* 1982; 27: 67-79, 167-173, 209-218.
- 3 Topazian R G. Comparison of gap and interposition arthroplasty in the treatment of temporomandibular joint ankylosis. *J Oral Surg* 1966; 24: 405-409.