

# TRAUMATIC NEUROMA IN WALL OF RECURRENT UNICYSTIC AMELOBLASTOMA: A CASE REPORT

ROSNAH BTE ZAIN  
K. C. LING

## SUMMARY

*This is a case report of a recurrent lesion diagnosed histologically as a unicystic ameloblastoma. The concomitant presence of a traumatic neuroma was observed within the wall of the recurrent lesion. The mode of development of the traumatic neuroma, and the reason for the recurrence were presented.*

## INTRODUCTION

Traumatic neuromas or amputation neuromas are common findings within soft tissues following previous surgery. Centrally located lesions are not so common and those reported had been within the posterior mandible.<sup>1</sup> Clinically, these lesions may or may not be accompanied by pain and microscopically consist of a nonneoplastic, nonencapsulated tangled mass of nerve tissue within scar tissue.

The unicystic ameloblastoma is a recently described entity which carries the connotation of a clinically benign, non-aggressive tumour as

compared to the conventional ameloblastoma.<sup>2</sup> A clinical diagnosis of unicystic ameloblastoma could never be made due to its radiographic appearance mimicking that of a benign cystic lesion. The histopathologic diagnosis of unicystic ameloblastoma can only be made with the observation of ameloblastomatous epithelium within the cyst lining or wall.

The purpose of this article is to report an unusual case of traumatic neuroma within the wall of a recurrent unicystic ameloblastoma. Such concurrent appearance of the two lesions has not been reported in the English literature.

## CASE HISTORY

A 23-year-old Chinese male patient presented at the Dental Faculty, University Hospital for post-operative follow-up. The patient had a lesion removed about one-and-a-half years ago from the left mandible in a General Hospital.

The patient had no complaints and appeared well. There was no obvious swelling extraorally. There was anaesthesia on the left side of the lower lip; mouth opening was normal. Intra-oral examination revealed bucco-lingual bony expansion of the left ramus of the mandible.

Radiological examination showed a large unilocular radiolucency in the left ramus of the mandible. It destroyed the coronoid process,

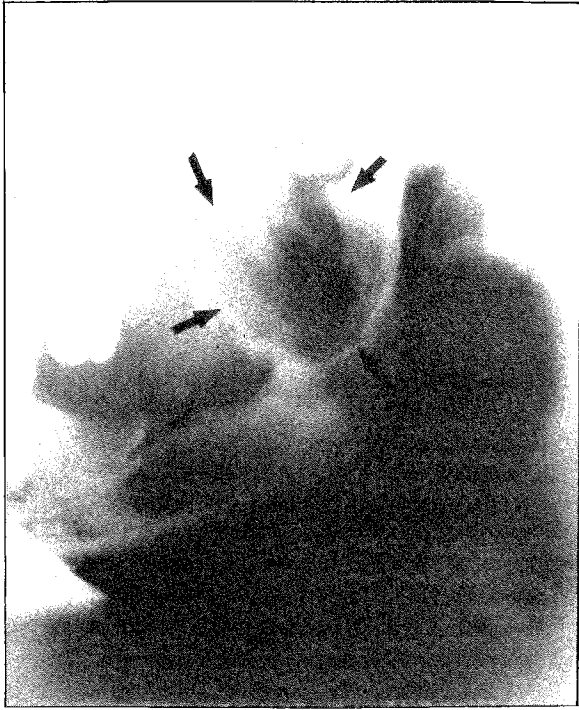
---

Rosnah bte Zain, BSc (Qld), MS (Mich)  
Department of Oral Pathology and Oral Medicine

K.C. Ling, BDS (Spore), MBS (Spore), FDSRCS (Engl)  
Department of Oral Surgery

Dental Faculty  
University of Malaya  
Kuala Lumpur, Malaysia

---



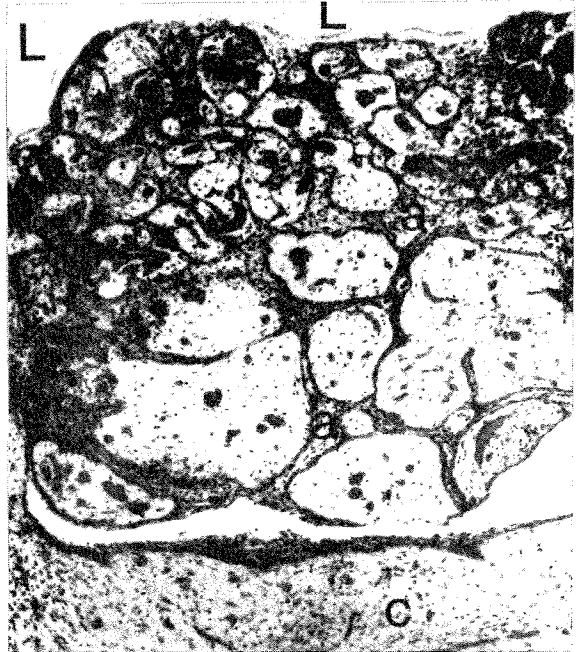
**Fig. 1** A unilocular radiolucent area involving the left ramus extending into the coronoid process. (Arrows showing the boundary of the lesion.)

the sigmoid notch and the anterior border of the ramus (Fig. 1). Haematological and biochemical investigations were normal.

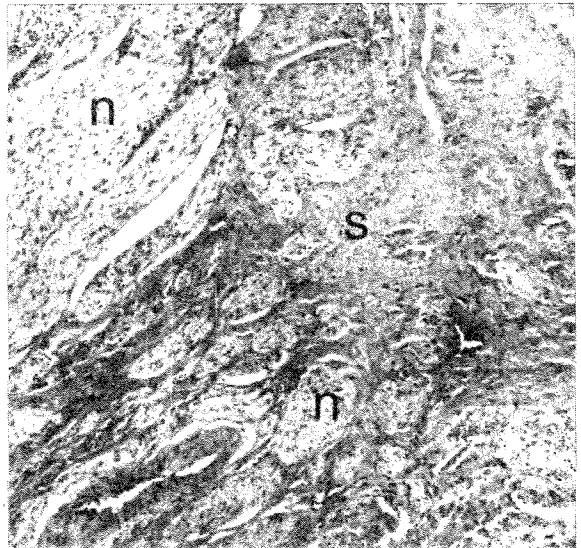
A provisional diagnosis of recurrent odontogenic keratocyst was made. Under general anaesthesia and through a submandibular incision, the lesion was enucleated. A thin layer of bony wall was removed with a bur to ensure that no lesional tissue was left behind. Healing was uneventful.

Histologically, there was a cyst wall lined by ameloblastomatous epithelium. Nodules of the ameloblastomatous epithelium projected into the lumen (Fig. 2a). A traumatic neuroma composed of many nerve bundles in a fibrous connective tissue matrix (or scar tissue) was evident within the cystic wall (Fig. 2b). The diagnosis was recurrent unicystic ameloblastoma with traumatic neuroma in its wall.

Clinically and radiologically, there was no recurrence eight months postoperatively.



**Fig. 2 a.** Photomicrograph of the cystic wall with an intraluminal ameloblastomatous proliferation: (L – lumen, a – ameloblastomatous epithelium, c – cystic wall; Original magnification – 33X).



**b.** Photomicrograph of a portion of the cystic wall containing many traumatic neuromata (n) within scar tissue (s). (Original magnification – 33X.)

## DISCUSSION

The occurrence of the traumatic neuroma is most likely to be due to the sectioning of the inferior dental nerve during the previous surgery. Gardner,<sup>3</sup> in his discussion on treatment of recurrent ameloblastoma mentioned the fact that cases have occurred in which apparent recurrences of ameloblastoma were found to be fibrous scar or traumatic neuroma on histologic examination. The present case further substantiates Gardner's observation but in this case a recurrent ameloblastoma was also evident.

The nature of the previous surgery was unknown and even though unicystic ameloblastoma is known

to have a low recurrence rate,<sup>2,3</sup> this is an isolated case where recurrence had occurred. This may be explained by the fact that this was originally an advanced unicystic ameloblastoma which therefore behaved in a more aggressive manner similar to conventional ameloblastoma.

## REFERENCES

- 1 Sist T C, Greene G W. Traumatic neuroma of the oral cavity. *Oral Surg* 1981;51/4:394-402.
- 2 Robinson L, Martinez M G. Unicystic ameloblastoma. A prognostically distinct entity. *Cancer* 1977; 40:2278-2285.
- 3 Gardner D G. A pathologist's approach to the treatment of ameloblastoma. *J Maxillo Fac Surg* 1984;42:161-165.