

# NEONATAL PROXIMAL FEMORAL EPIPHYSIOLYSIS (NPFE): A CASE REPORT

KULDIP SINGH DHILLON

## SUMMARY

*Neonatal epiphyseal separation of the head of femur is a rare obstetrical injury. This is confused with the more common proximal femoral metaphyseal fracture, dislocation of hip or even an infection. Such a case is reported in this paper. Management was conservative, with abduction splint for three weeks and the outcome was satisfactory.*

## INTRODUCTION

Disruption of the proximal femoral epiphysis in the neonate is a rare injury, and requires to be differentiated from congenital dislocation of hip, osteomyelitis of proximal femur and fracture of the proximal femoral metaphysis. The proximal femoral epiphysis in the neonate is not visible in an X-ray. Therefore, diagnosis of its disruption is not easy. Radiological changes do occur in the proximal metaphysis; but by the time they occur, diagnosis is missed, and treatment delayed. The present case reveals such a situation and merits reporting.

## CASE REPORT

A two-day-old Indian female neonate was referred to University Hospital Kuala Lumpur, from a maternity home with a diagnosis of suspected fracture of the proximal femur. The neonate was the second of a twin, a product of difficult breech delivery with internal podalic version for a transverse lie with cord prolapse. One day after delivery, the left thigh was observed to be swollen, and the neonate did not move the left lower limb. On examination at the hospital, the neonate was noted to be afebrile, but irritable. The left upper thigh was grossly swollen, and the limb held in flexion, abduction and external rotation. There was tenderness over the upper thigh, the skin felt warmer and movements at the left hip were grossly limited. There was in addition 'pseudo-paralysis' of the whole of the left lower limb. In view of the pain, tests for hip dislocation were not carried out. Haematological investigations were normal. X-rays of the hips showed slight lateralisation of the proximal end of the left femur (Fig. 1). Acetabulum appeared normal, and no obvious fracture was seen. Diagnosis was not clear, though the possibility of an infection and/or a dislocation was entertained.

For the first two days, the limbs were put in Byrant's Traction with both hips in 90° flexion.

The baby would not tolerate this. Therefore, the lower limbs were put in an abduction splint for three weeks. Antibiotics were given. Periodic examination

---

Kuldip Singh Dhillon, FRCS  
Department of Orthopaedic Surgery  
Faculty of Medicine  
University of Malaya  
Kuala Lumpur, Malaysia

---

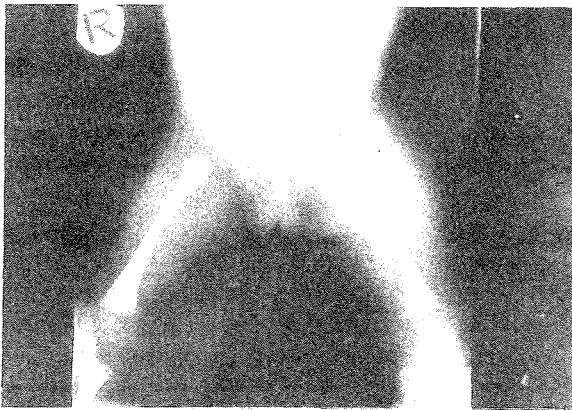

Fig. 1 On admission A/P view both hips showing slight lateralization of proximal end of (L) femur.

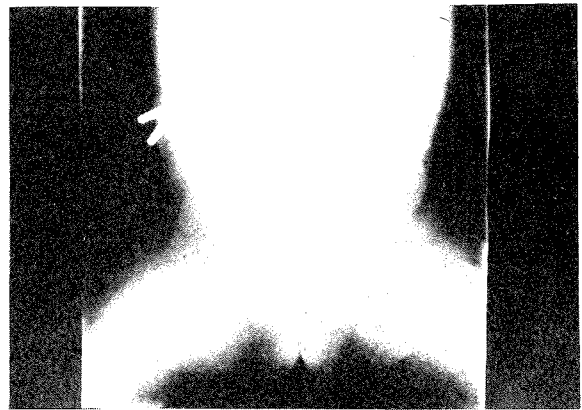


Fig. 2 A/P both hips five weeks later showing exuberant callus formation around the proximal femoral metaphysis.

only showed the palpable bony swelling over the anterior proximal thigh. The neonate showed gradual improvement over the next two weeks. About this time, X-rays showed some metaphyseal callus, and the possibility of disruption of the proximal femoral epiphysis became apparent. This was the most likely diagnosis, rather than an infection, in view of the external rotation deformity of the hip and the gross swelling. An arthrogram of the left hip would have been very helpful, but was not done.

Since the baby was now moving the limb painlessly, the abduction splint was changed to double-diapers, and the baby discharged from hospital. Follow-up examination five weeks later showed that the baby could move both lower limbs, painlessly. Hip movement were nearly full, except for slight limitation of abduction in flexion. X-rays showed exuberant callus formation around the proximal femoral metaphysis (Fig. 2). Long-term follow-up of the child is planned.

## DISCUSSION

Most reported proximal femoral epiphysiolyis occurred during traumatic deliveries that involved breech or footling presentation.<sup>1</sup> The mechanism of injury is usually hyperextension, abduction and rotation of the limb during strong traction. The case reported here was a breech presentation, with internal podalic version. The exact details of delivery could not be obtained.

Clinical picture of the condition is fairly characteristic. Swelling is constant in the inguinal crease, gluteal area and proximal thigh. The limb is an external rotation, flexion and abduction at the hip. Pain and crepitus is elicited with attempted movement of the hip. Pseudo-paralysis of the limb is a constant feature, and this disappears as the fracture becomes pain-free. Septic arthritis and osteomyelitis of proximal femur should be considered, especially as neonates often do not show the kind of response to infection as the older child does. X-rays show lateral displacement of the proximal end of the metaphysis, but this is difficult to interpret. Characteristic callus formation around proximal metaphysis confirms diagnosis, usually two weeks after onset. Diagnosis, however, should be made earlier, so that any deformity at the hip, usually a varus or posterior tilt could be reduced. Arthrograms, if done, will show a well located capital femoral cartilage (head with greater trochanter) and leakage of dye below the medial capsule. In a recent fracture, motion studies during an arthrogram will show independent movement of the proximal and distal segment.

Ogden *et al.*,<sup>2</sup> in a recent study, have shown experimentally that separation occurred at or below the zone of cartilagenous hypertrophy of the physis as a typical type I growth mechanism injury. They also observed that the periosteal sleeve was intact posteriorly and disrupted anteriorly, allowing

the proximal metaphysis to 'button-hole' through the tear. The posterior attachment of periosteum to physical periphery can be taken advantage of during traction and reduction, and will provide a certain amount of intrinsic stability.

The best method of treatment is far from established. Various forms of immobilisation, for example Double Diapers, Frejka Abduction Splint, Hip Spica, Traction and even no treatment has been used in treatment of cases reported. Bryant's traction with hips in 90° flexion and knees slightly flexed would be a good initial method. The position will usually correct this varus displacement. Once the infant becomes pain-free, an abduction pillow splint or Pavlik Harness could be used for about four weeks.

Long-term follow-up studies up to skeletal maturity are not available however some of the complications reported in the literature include coxa vara, hypertropic bone formation and early epiphyseal fusion. Ischaemic necrosis as seen in epiphyseal fracture separation in older children has not been described. The anatomy of the fracture relative to blood supply makes it unlikely, since the

fracture line is primarily extracapsular and away from the main blood supply which will be proximal to the injury and should be relatively undisturbed. It can be said that once a diagnosis is made, treatment is really conservative and excellent results can be obtained.

## ACKNOWLEDGEMENT

Thanks is extended to Professor N. Subramanian, Head, Department of Orthopaedic Surgery, for his guidance; the Director, University Hospital, for permission to publish this case; to Medical Illustration Unit for the photographs, and to Ms Sharmini Devi R. and Miss Khamsiah Sulaiman for typing this manuscript.

## REFERENCES

- <sup>1</sup> Theodorou S D, Ierodiconou M N, Mitsou A. Obstetrical fracture - separation of the upper femoral epiphysis. *Acta Orthop Scand* 1982; 53: 239.
- <sup>2</sup> Ogden J A, Lee K E, Rudicel S A, Pelker R R. Proximal femoral epiphysiolysis in the neonate. *J Pediatr Orthop* 1984; 4: 285-292.