

# A CASE OF LINGUAL THYROID WITH HYPOTHYROIDISM

P. KANDASAMI  
V.K. MATHEWS

## SUMMARY

*Cases of lingual thyroid are rare. The Johns Hopkins Hospital, New York, reported three cases of lingual thyroid in 800,000 admissions. We report here a case of lingual thyroid associated with hypothyroidism. The embryology, clinical features and principals of management are discussed.*

## CASE REPORT

A 23-year-old female sought treatment at the outpatients department, General Hospital, Kuantan for a sore throat. She was noted to have a swelling at the back of her tongue and was referred to the surgical clinic.

There was no history of difficulty in swallowing. On examination, she was found to be short-statured (128 cm) and underweight (31 kg) (Fig. 1). She was hirsute and had coarse dry skin. Her facial features were coarse and her tongue was large. Secondary sexual characters were poorly developed;

the breasts were small and she had sparse axillary and pubic hair. Her external genitalia appeared normal.

There was a globular swelling over the base of the tongue measuring 2 cm in diameter (Fig. 2). The thyroid gland was not palpable in its normal position. X-rays of the neck revealed no abnormality. Radiological bone age was less than 18 years.

---

P. Kandasami,  
MBBS (Bom), FRCS (Ire), FRCS (Glasg), FRCS (Edin)  
Consultant Surgeon

V.K. Mathews, MBBS (Mal), MRCP (UK)  
Consultant Paediatrician  
General Hospital Kuantan  
Pahang, Malaysia

---

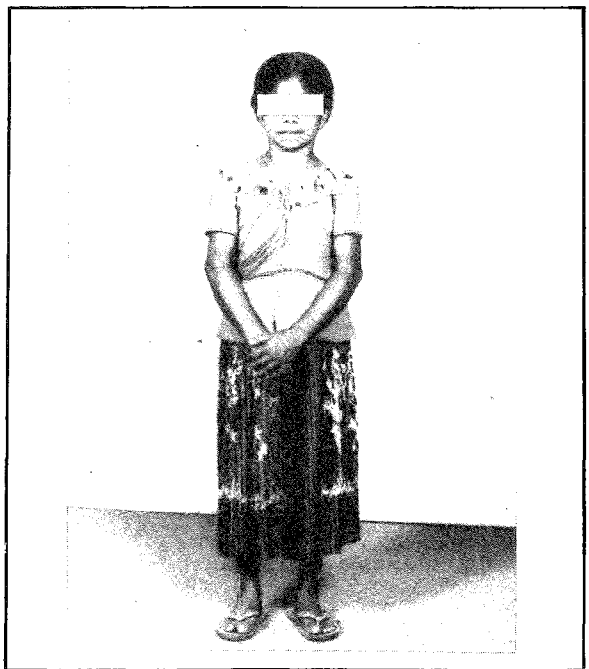

Fig. 1 The patient, 23-years-old showing height of 128 cm and weighing 31 kg.

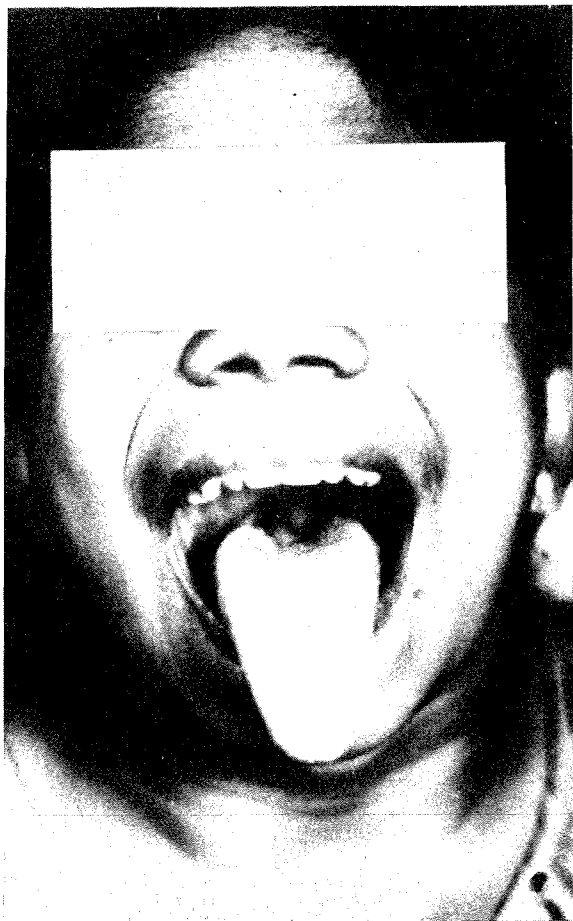


Fig. 2 The globular mass seen at the base of the tongue.

A thyroid scan demonstrated activity over the posterior third of the tongue with no pick-up over the normal thyroid area. Results of thyroid function studies were as follows: RIA  $T_4$  concentration – 34 nmol/l (reference range 54 – 142); RIA Free  $T_4$  concentration – 68 pmol/l (reference range 0–23); RIA hTSH concentration – 60 u.i.u./ml (reference range 0 – 70). The patient was diagnosed as having a lingual thyroid with hypothyroidism. She was commenced on replacement thyroxine therapy.

## DISCUSSION

The thyroid gland begins during the third week of embryological development as an ectodermal

thickening in the midline of the pharynx floor, between the tuberculum par and the copula. Later, this thickening becomes a diverticulum that grows inferiorly into the underlying mesenchyme and is called the thyroglossal duct. The duct becomes a solid cord of cells. The thyroid gland develops as a result of epithelial proliferation and descends into the lower neck. Lingual thyroid formation is a result of incomplete descent. The mass of tissue is found at the foramen caecum as a globular swelling.

Patients with lingual thyroid glands often exhibit thyroid dysfunction. It is estimated that 70% of patients with such glands do not have other functional thyroid tissue. In addition, these patients may develop complications like dysphagia, dysphonia, respiratory obstruction and haemorrhage. Glands causing obstructive symptoms may either be surgically excised or reduced in size, using radioactive  $I_{131}$  in cytoreductive doses. Unfortunately, both procedures tend to result in hypothyroidism requiring replacement therapy.

Autotransplantation of excised lingual thyroid tissue has been successfully attempted. In fact it has been recommended in order to avoid the development of hypothyroidism.<sup>1</sup> Development of thyroid carcinoma in functioning ectopic thyroid tissue is very rare, and therefore is not an indication for removal of such tissue.<sup>2,3</sup> Our patient showed evidence of hypothyroidism with no other complications. Management therefore consisted merely of replacement therapy.

## REFERENCES

- 1 Jones P. Autotransplantation in lingual ectopia of the thyroid gland. *Arch Dis Child* 1961; 36: 164-170.
- 2 Katz A D, Zager W J. The lingual thyroid: its diagnosis and treatment. *Arch Surg* 1971; 102: 582-585.
- 3 Ward G E, Cantrell J R, Allan W B. The surgical treatment of lingual thyroid. *Annals Surg* 1954; 139 (5): 536-544.