

# LARGE TYPE I CHOLEDOCHAL CYST IN ADULTS: A CASE REPORT

M. M. SUDHAKAR KRISHNAN  
N. T. A. COUPER

## INTRODUCTION

Choledochal cyst in adults is a rare clinical entity and there has been only a few reports in the literature.<sup>1</sup> We present a case of a large type I choledochal cyst in a 31-year-old woman and emphasise the means of preoperative diagnosis.

## CASE HISTORY

A 31-year-old Malay woman was transferred to the University Hospital, Kuala Lumpur on 7 October 1982 from another hospital, where she was being treated for pulmonary tuberculosis. Four weeks prior to her transfer, she was noted to be jaundiced, and had low grade fever and upper abdominal pain. On abdominal examination, a smooth mass size of 18 x 15 cms was noted in the right upper quadrant below an enlarged liver, which was 3 cms below the right costal margin in the mid-clavicular line. There was no evidence of ascites. Chest examination was normal. Laboratory investigations were as follows: Blood Hb 9.9 g/l, PCV 30%, WBC, TC 9600 cells/mm<sup>3</sup>, ESR 92 mm/hr, Urea 3/mmol/l, Na<sup>+</sup> 139 mmol/l, K<sup>+</sup> 3.7 mmol/l, CL 101 mmol/l, sr. creatinine 55 μmol/l. The total bilirubin 457 μmol/l,

conjugated bilirubin 382 μmol/l, alkaline phosphatase > 350 iu/l, aspartate transaminase > 300 iu/l, alanine transaminase 80 iu/l. Total protein 75 g/l, albumin 35 g/l, prothrombin time 100%. Sputum AFB was negative and on culture no mycobacterium was isolated.

The ultrasound examination (Fig. 1) made at the referring hospital, showed two anechogenic regions of almost equal size, one caused by the right and left main hepatic ducts in continuity with multiple dilated intrahepatic radicles. Immediately caudal to these was a much larger anechogenic mass which filled much of the right side of the abdomen. The main differential diagnosis for this appearance would be between a choledochal cyst and a massively dilated gallbladder. Failure to demonstrate a common bile duct, or any mass that could obstruct it, favours the former diagnosis.

A Barium meal examination showed the duodenum pushed medially by a large smooth retro-duodenal mass. Percutaneous transhepatic cholangiogram (Fig. 2) showed massively dilated tortuous intrahepatic bile ducts. Contrast medium entered a very large space, partly by diffusion, partly by gravity, and this space corresponded with that seen on ultrasound, suggestive of a large choledochal cyst. A <sup>99</sup>Tc<sup>m</sup>-diethyl-IDA hepatobiliary imaging also showed the presence of a large choledochal cyst.

At operation a large type I choledochal cyst measuring 20 x 18 cms was seen (Fig. 3). The liver

---

M. M. Sudhakar Krishnan, MS, FRCS, FRCS  
Department of Surgery  
N. T. A. Couper, BA, MBBCh, DCH, FRCr  
Department of Radiology  
University Hospital  
Kuala Lumpur  
Malaysia

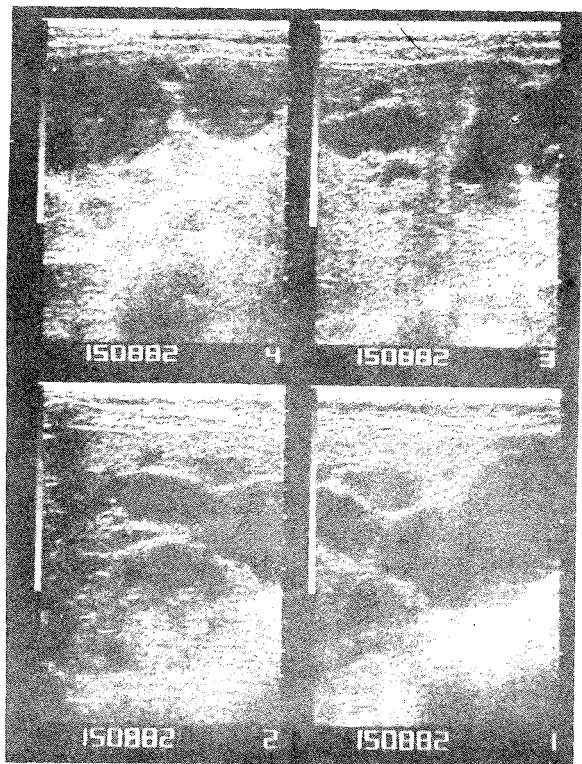


Fig. 1 Freeze frames from a real time ultra sound examination; the slices are longitudinal with the patient's head to the left and in the right paramedian plane, showing a large choledochal cyst and dilated intra-hepatic bile duct dilatation.

was tense and congested. The gallbladder was moderately distended and contained no stones. The gallbladder and choledochal cyst were excised. The posterior wall of the cyst was partially excised leaving the outer fibrous wall to avoid injury to the portal vein and hepatic artery.<sup>2</sup> Postoperative recovery was smooth and she was discharged on 7 November 1982. On a follow-up review carried out on 20 July 1983, she was found to be well and asymptomatic and her liver function test were normal.

## DISCUSSION

Choledochal cyst was first described by Douglas in 1852.<sup>3</sup> Choledochal cyst is a cystic dilatation of the bile duct commonly seen in younger age

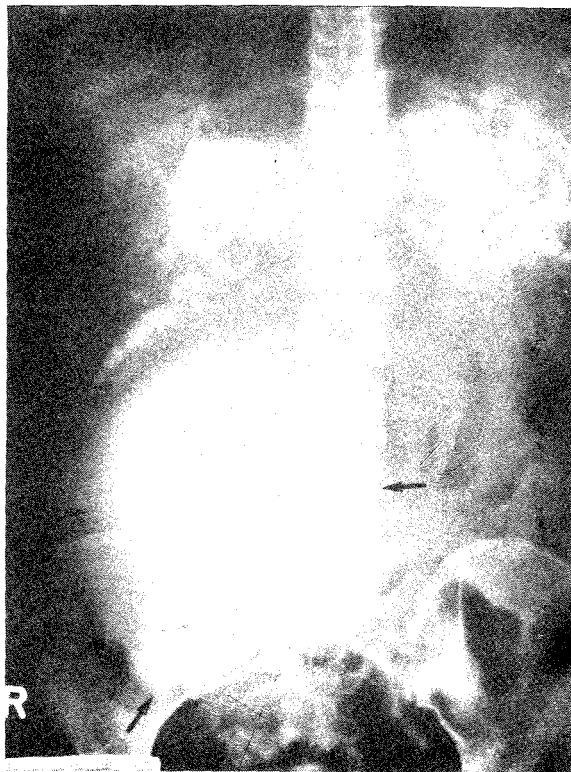

Fig. 2 Percutaneous transhepatic cholangiography showing a large choledochal cyst.

groups. Of late this condition has been reported in adults.<sup>1,4,5,6,7</sup> Classification of Alonso-Lej *et al.*,<sup>8</sup> has since been modified by Kunio Kimura *et al.*,<sup>9</sup> into type I which is dilatation of the common bile duct, type II a lateral out-pouching or diverticulum of common bile duct, type III a choledochocoele of the terminal part of common bile duct in the duodenum and type IV where cystic dilatation of the intra and extra hepatic biliary tract is encountered. Of these type I comprise 80 – 90% of all choledochal cyst.<sup>1</sup>

The often mentioned clinical triad of jaundice, mass and pain is seen only in about 20% of patients.<sup>7</sup> The clinical course is invariably of gradual onset and transient symptoms, and over 25% of the cases are seen in patients over 10 years.<sup>1,7</sup>

Cause of choledochal cyst has been attributed by some to an anomalous ductal union like that of the

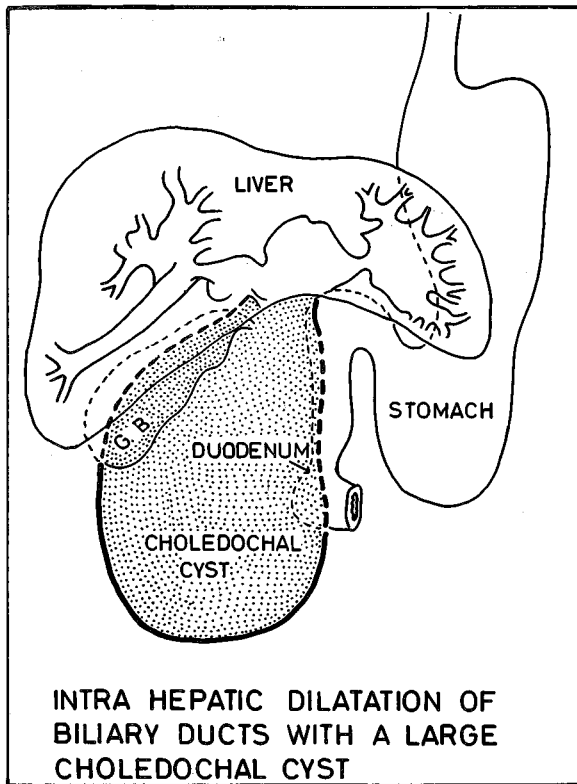


Fig. 3 Diagrammatic representation of the operative findings of a large type I choledochal cyst.

embryonic hepatico-pancreatic duct persisting into adult life without separation of the pancreatic and common bile ducts during development.<sup>8,10</sup> This results in a loss of the sphincter mechanism at the pancreatico-biliary junction, permitting the reflux of pancreatic juice into the bile ducts, leading to cholangitis and dilatation of the bile ducts later. Whereas congenital choledochocoele is believed to have a different aetiology.<sup>8</sup>

The onset of non-invasive techniques of ultrasound, C. T. Scan and <sup>99</sup>Tc<sup>m</sup>-diethyl-IDA (EHIDA) hepatobiliary imaging has made considerable strides in the preoperative diagnosis of this condition. In our patient diagnosis of a large choledochal cyst was made on ultrasound and confirmed by percutaneous transhepatic cholangiography (PTC). It was not possible during percutaneous transhepatic cholangiography to aspirate bile through a Chiba (Fr. 22) needle, and commonly as little contrast

medium as possible is introduced to make the diagnosis. A marked increase in pressure within an obstructed, potentially infected biliary tree may cause septicaemia. In this case it was necessary to introduce 50 ml of a high density medium (Conray 420-sodium iothalamate 420 mgm of iodine per millilitre) and to allow time (40 minutes) for diffusion into the cyst. It is of interest that neither ultrasound nor cholangiogram revealed the gallbladder, presumably as it was compressed against the underside of the liver.

The treatment of choledochal cyst is surgical. Drainage procedures have now been replaced by excision of the cyst and adequate drainage like hepatico-jejunostomy with Roux-en-Y anastomosis.<sup>6</sup> Surgical modifications as Lilly's technique<sup>2</sup> have reduced risk of injury to the portal vein.

A mere drainage procedure invariably results in blockage and required a second operation.<sup>11</sup> The high incidence of anastomotic stricture in patients following surgery is attributed to anastomosing a cyst wall which has no epithelial lining. Complications of an untreated choledochal cyst are cholangitis, biliary cirrhosis, pancreatitis, haemobilia, traumatic rupture, portal vein thrombosis and carcinomatous change in the cyst wall.<sup>12</sup> The incidence of malignant change in the cyst wall is about twenty times greater than in the general population.<sup>1</sup>

## REFERENCES

- <sup>1</sup>Shiloni E, Durst A I, Lebensart P, Freund U. Type I - Choledochal cyst in adults. *Isr J Med Sci* 1983; 19: 209-211.
- <sup>2</sup>Lilly J R. Total excision of choledochal cyst. *Surg Gynecol Obstet* 1978; 146: 254-56.
- <sup>3</sup>Douglas A H. Case of dilatation of the common bile duct. *Monthly J Med Sci* 1852; 14: 77.
- <sup>4</sup>Joseph W L, Fonkalsrud E W, Longouise W P Jr. Cystic dilatation of common bile duct in adults. *Arch Surg* 1965; 91: 468-473.
- <sup>5</sup>Shields A B. Congenital cystic dilatation of the common bile duct. *Am J Surg* 1964; 108: 142-149.

- <sup>6</sup>Powell C S, Sawyers J L, Reynolds V E. Management of adult choledochal cyst. *Ann Surg* 1981; 193: 666-674.
- <sup>7</sup>Somasundaram K, Tan K C, Wong T J. Personal communication, 1983.
- <sup>8</sup>Alonso-Lej F, Rever W B Jr, Pessangno D J. Congenital choledochal cyst with a report of two and an analysis of 94 cases. *Int Abst & Surg* 1959; 108: 7-30.
- <sup>9</sup>Kimura K, Ohito M, Ono K, Tsuchiya Y, Saisho H, et al. Congenital cystic dilatation of the common bile duct. Relationship to anomalous pancreaticobiliary ductal union. *Am J Roent genol* 1977; 128: 571-577.
- <sup>10</sup>Babbitt D P, Starshak R J, Clenett A R. Choledochal cyst; a concept of etiology. *Am J Roent genol* 1973; 119: 57-62.
- <sup>11</sup>Trout H H, Longmire W P. Long term follow-up study of patients with congenital cystic dilatation of the common bile duct. *Am J Surg* 1972; 121: 68-81.
- <sup>12</sup>Todani T, Tabuchi K, Watanabe Y, Kobayashi T. Carcinoma arising in the wall of congenital bile duct cyst. *Cancer* 1979; 44: 1134-1141.