

# OCULAR TOXOPLASMOSIS IN MALAYSIA

LIM V. K. E.

TAN P. L.

## SUMMARY

31 cases of ocular toxoplasmosis were seen at the Ophthalmology Clinic, Universiti Kebangsaan Malaysia, Kuala Lumpur during a one-and-a-half year period. All these cases were diagnosed as congenital ocular toxoplasmosis. As this condition appears not to be uncommon in Malaysia, greater effort should be made towards its prevention especially among pregnant women.

## INTRODUCTION

Toxoplasmosis is a common cause of posterior uveitis. Between 25% to 70% of all uveitis has been attributed to toxoplasmosis.<sup>1,2,3</sup> Ocular toxoplasmosis may be congenital or acquired, but acquired ocular toxoplasmosis is extremely rare.<sup>4</sup> The diagnosis of ocular toxoplasmosis is at the present time largely presumptive. It is based on a combination of typical clinical findings and serological evidence of a toxoplasma infection. Isolation of the parasite is not practical as it would involve enucleation of the eye. We have reviewed the cases of ocular toxoplasmosis seen at the Ophthalmology Clinic, Universiti Kebangsaan Malaysia, Kuala Lumpur over a period of one-and-a-half years.

## MATERIALS AND METHODS

All cases of ocular toxoplasmosis seen between 1.1.1981 and 30.6.1982 form the basis of this study.

Ocular toxoplasmosis was diagnosed based on the following criteria: (a) typical clinical findings, (b) a positive serological titre of 1/64 or greater, and (c) exclusion of other common causes of retinochoroiditis like syphilis, tuberculosis and fungal infections. The serological test performed was an immunofluorescence technique using reagents purchased from Behringwerke, West Germany and carried out according to the manufacturer's instructions. Positive and negative controls were set up for all tests. On diagnosis of active ocular toxoplasmosis, patients were started on anti-toxoplasma treatment consisting of a combination of pyrimethamine 25 mg tds and sulphadiazine 1 G qid (average doses). Prednisolone was also given to these patients. The purpose of giving prednisolone was to suppress the retinal inflammation. While on treatment the TWBC and platelet counts were monitored. All patients were requested to attend a follow-up clinic.

## RESULTS

A total of 31 cases of ocular toxoplasmosis were recorded. They comprised 19 males and 12 females. There were 15 Malays, 8 Chinese and 8 Indians. Their ages ranged from 14 to 68 years.

25 patients were from the Kuala Lumpur — Selangor areas, 3 were from Pahang and one each from Negri Sembilan, Perak and Kelantan. A history of keeping cats as pets was obtained only in 4 patients though all patients admitted to coming into contact with cats at sometime or another.

The most common complaint recorded was blurring of vision which occurred in all 31 patients. 3 patients also complained of visual field defects of the central scotoma type. Floaters occurred in 2 patients and 1 patient complained of pain in the eyeball. Of the non-ocular symptoms, intermittent headache was the commonest, occurring in 7 patients. There was no history of fever or other

---

Lim V. K. E., MB BS (Malaya), MSc (London), MRCPPath  
Department of Microbiology,  
Universiti Kebangsaan Malaysia,  
P. O. Box 2418, Kuala Lumpur.

Tan P. L., MB BS (Lucknow), D O (London), FRCS  
Department of Ophthalmology,  
Universiti Kebangsaan Malaysia,  
P. O. Box 2418, Kuala Lumpur.

---

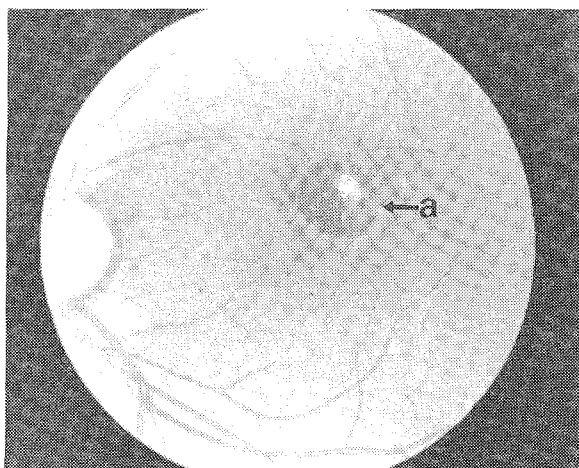


Fig. 1 Fundus of a patient with chronic ocular toxoplasmosis showing a well defined and pigmented macular scar (a).

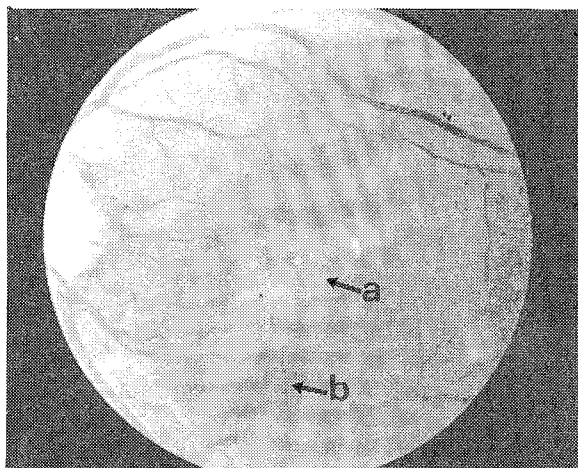


Fig. 2 Acute recurrence of congenital toxoplasmosis. Fundus examination showed an acute chorioretinal focus (a) with an adjacent old scar (b).

symptoms suggestive of acute systemic toxoplasmosis in all 31 patients.

The disease was found to be unilateral in 16 patients and bilateral in 15. Visual acuity was diminished in all 31 patients. There were no patients with clinical evidence of acute systemic toxoplasmosis. 19 patients had clinical findings suggestive of chronic ocular toxoplasmosis. This usually consists of a well-defined, round or ovoid, pigmented macular scar (Fig. 1). This was in certain cases associated with areas of haemorrhage. 12 patients presented with ocular findings suggestive of an acute recurrence of congenital toxoplasmosis. This presented typically of a yellowish chorioretinal focus with a dense centre and oedematous edges. The vitreous was almost always altered. Quite often there was an adjacent old cicatricial focus (Fig. 2). Of the 12 patients with acute recurrences, 10 were in the 10-40 age group.

The serological findings of the 31 patients are summarised in Table I. 25 patients had titres of 1/256 or less, 5 had a titre of 1/512 and one patient had a titre of 1/1024.

Of the 31 patients, only 20 returned for follow-up. 12 patients showed some improvement based on fundal examination and improvement in visual acuity. There was no appreciable improvement in the other 8 patients.

## DISCUSSION

Toxoplasmosis is caused by *Toxoplasma gondii*,

TABLE I  
SEROLOGICAL FINDINGS OF 31 PATIENTS WITH  
OCULAR TOXOPLASMOSIS

Anti-toxoplasma antibody titre	Pattern of disease	
	Chronic	Acute recurrence
1/64	2	0
1/128	10	6
1/256	5	2
1/512	2	3
1/1024	0	1
TOTAL	19	12

a parasite which belongs to the class *Sporozoa*. Toxoplasmosis may be congenital or acquired. The infection occurs when man, an intermediate host, ingests oocysts from cats' faeces. Man may also acquire the infection at other stages of the development of the parasite in other intermediate hosts, as by ingestion of affected meat or through abrasions. Congenital toxoplasmosis is transmitted mainly during the first three months of pregnancy. The mother acquires an infection which is usually asymptomatic. The parasite appears to have a predilection for the retina in congenital toxoplasmosis. The exact reason for this is however unknown.

Ocular toxoplasmosis was first described in 1923 by Janku who demonstrated intracellular parasites in retinal sections.<sup>5</sup> In 1937, Wolf and Cowen identified toxoplasma in tissue sections of an eye of a child with chorio-retinitis.<sup>6</sup> In 1952, Wilder

published her classical paper of 53 cases of ocular toxoplasmosis based on the histopathological examination of tissue sections of enucleated eyes.<sup>7</sup> The first isolation of toxoplasma from an enucleated eye was reported by Jacobs, Fair and Bickerton in 1954.<sup>8</sup>

The incidence of congenital toxoplasmosis varies from country to country. It is 1:10,000 in the United States, 1:1,000 in France and as high as 1:500 in Norway.<sup>9</sup> The true incidence of congenital toxoplasmosis in Malaysia is not known, but serological surveys conducted in the Malaysian population has shown that toxoplasmosis is a common infection in this country.<sup>10</sup> The highest incidence occurs in Malays, followed by Indians and Chinese. The reasons for this difference are unknown. It is interesting to note that almost half the patients in this series are Malays. However, the numbers are too small and the population too selected to make any definitive conclusions. There are no children in this series. This is probably due to the fact that the Ophthalmology Clinic did not receive any referrals from the paediatricians.

19 patients in this series presented with the cicatricial stage of the disease which is the most common presentation of ocular toxoplasmosis. Acute recurrences of chronic congenital ocular toxoplasmosis was seen in 12 patients. This usually occurs below the age of 40, as is the case in this series, and the number of recurrent attacks may vary from 1 - 13.<sup>11</sup> The cause of the acute recurrent attack is not known but there are two prevailing hypotheses. It may be due to an allergic reaction due to the rupture of a toxoplasmic cyst and liberation of antigens. The other theory is that it represents an endogenous reinfection since the parasite may persist in the latent state in the retina for many years.

The majority of our patients had fairly low titres of anti-toxoplasma antibodies unlike that seen in acute systemic infections. This is consistent with what has been observed elsewhere.<sup>9</sup> The level of antibody required to be able to make a diagnosis of ocular toxoplasmosis has not been firmly established. While some would accept any positive titre as being significant, others insist on a level of at least 1/64 in order to admit a toxoplasmic origin.<sup>11</sup> A more accurate method would be to compare the level of antibody in aqueous humour with that in the serum<sup>12</sup> but this has its practical difficulties and was not attempted in this study.

The treatment of ocular toxoplasmosis at the present time is still less than satisfactory. There is no effective vaccine as yet. What is perhaps more important is the prevention of the illness especially among pregnant women since congenital toxoplasmosis carries both a high mortality as well as morbidity rates. Simple advice to pregnant women like the avoidance of half-cooked or uncooked meat, thorough hand-washing after gardening and avoidance of cats would help to prevent congenital toxoplasmosis. We have shown that congenital ocular toxoplasmosis is not an uncommon condition in Malaysia and it is hoped that there will be greater awareness among clinicians of this disease and that adequate steps may be taken to prevent it.

## REFERENCES

- <sup>1</sup> Perkins E S. Uveitis and toxoplasmosis. Little Brown. Boston. (1961).
- <sup>2</sup> O'Connor G R and Hogan M J. Recent developments in infectious diseases of the retina and the choroid. In: Sosby A. (ed) Modern trends in ophthalmology. Butterworth. London 1967, 75-90.
- <sup>3</sup> Cassady J V. Toxoplasmic retinochoroiditis. *Trans Am Ophthalmol Soc.* 1960; 58: 392-395.
- <sup>4</sup> Perkins E S. Ocular toxoplasmosis. *Br J Ophthalmol.* 1973, 57, 1-17.
- <sup>5</sup> Janku J. Pathogenesis and pathologic anatomy of coloboma of macula lutea in eye of normal dimensions and in microphthalmic eye, with parasites in retina. *Cas Lek Cesk,* 1923; 62: 1021-1027.
- <sup>6</sup> Wolf A and Cowen D. Granulomatous encephalomyelitis due to encephalitozoan (encephalitozoic encephalomyelitis): new protozoan disease of man. *Bull Neurology Inst NY.* 1937, 6: 306-371.
- <sup>7</sup> Wilder H C. Toxoplasmic choriretinitis in adults. *Arch Ophthalmol.* 1952, 48, 127-136.
- <sup>8</sup> Jacobs L, Fair J and Bickerton J. Adult ocular toxoplasmosis: report of a parasitologically proven case. *Arch Ophthalmol.* 1954, 52: 63-71.
- <sup>9</sup> Schlaegel Jr T F. Toxoplasmosis. In: Duane T D (ed) Clinical Ophthalmology, Harper Row, Philadelphia. 1981; 4: 1-17.
- <sup>10</sup> Thomas V, Sinniah B and Yap P L. Prevalence of antibodies including IgM to *Toxoplasma gondii* in Malaysians. *Southeast Asian J Trop Med Pub Health.* 1980, 11: 119-125.
- <sup>11</sup> Francois J. Congenital toxoplasmosis and its late recurrence. *Transac Asia Pacific Academy of Ophthalmology.* 1981; 8: 31-45.
- <sup>12</sup> Desmonts G. Definitive serological diagnosis of ocular toxoplasmosis. *Arch Ophthalmol.* 1966, 76: 839-851.