

# HYPOMELANOSIS OF ITO

CHOO KENG EE

## SUMMARY

*Two cases of Hypomelanosis of Ito are described; presenting with depigmented whorl-like, zig-zag, bizarre cutaneous manifestations associated with central nervous system disorders.*

## INTRODUCTION

Hypomelanosis of Ito is one of the neurocutaneous syndromes, first reported by Ito (1952).<sup>1</sup> It is hoped that this report will increase the awareness of this not uncommon entity. Since mental retardation and epilepsy are common, computerised tomography and EEG may help to manage the outcome in infants. Two cases are presented here, with annotations.

### CASE I

The patient was the only child of non-consanguineous healthy parents. An aunt died of fits at thirteen years of age. The antenatal history was normal. No medications were taken during pregnancy. Child was born full term, breech delivery with forceps for after coming head, in Kuala Trengganu General Hospital in November, 1979. Birth weight was 3.2 kg. Apgar score was 8; however, child developed fits a few hours later. The fits were treated and skin lesions were noted at birth. She was admitted at three months old for fever with recurrent fits. On examination, the child had bizarre distribution of hypopigmented areas of skin in whorls, streaks and patches over all the four limbs and trunk anteriorly and posteriorly. The face was spared. The child had poor head control and appeared floppy. All other systems were normal. A septic survey revealed nothing abnormal. Further investigations were refused. Fits were controlled with I.M. Paraldehyde. Nine days after discharge, the child got fits again, many

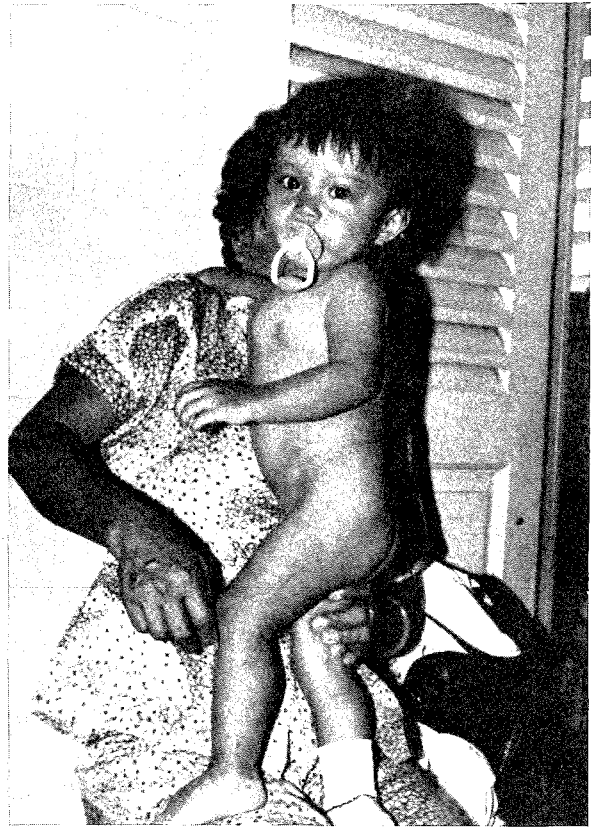

Fig. 1 Featuring the hypopigmented areas over left trunk, and left limbs.

times a day, and was treated at the Kelantan General Hospital.

At seven months old the child was admitted for fits and Bronchopneumonia. Hydrocephalus was noted this time, confirmed by skull x-rays. In the ward the child had several attacks of fits, controlled by Rivotril drip, I.V. Phenobarbitone and Sodium Valporate. The child had two further admissions for fits and bronchopneumonia. In the last admission, when she was one year old, the child was mentally retarded, with no head control, was unable to smile, sit or vocalise and had little response to visual and auditory stimuli. Patient defaulted treatment

---

Choo Keng Ee, MBBS (S'pore), MRCP (UK), A.M.  
Consultant Paediatrician, General Hospital,  
Kota Bharu, Kelantan.

---

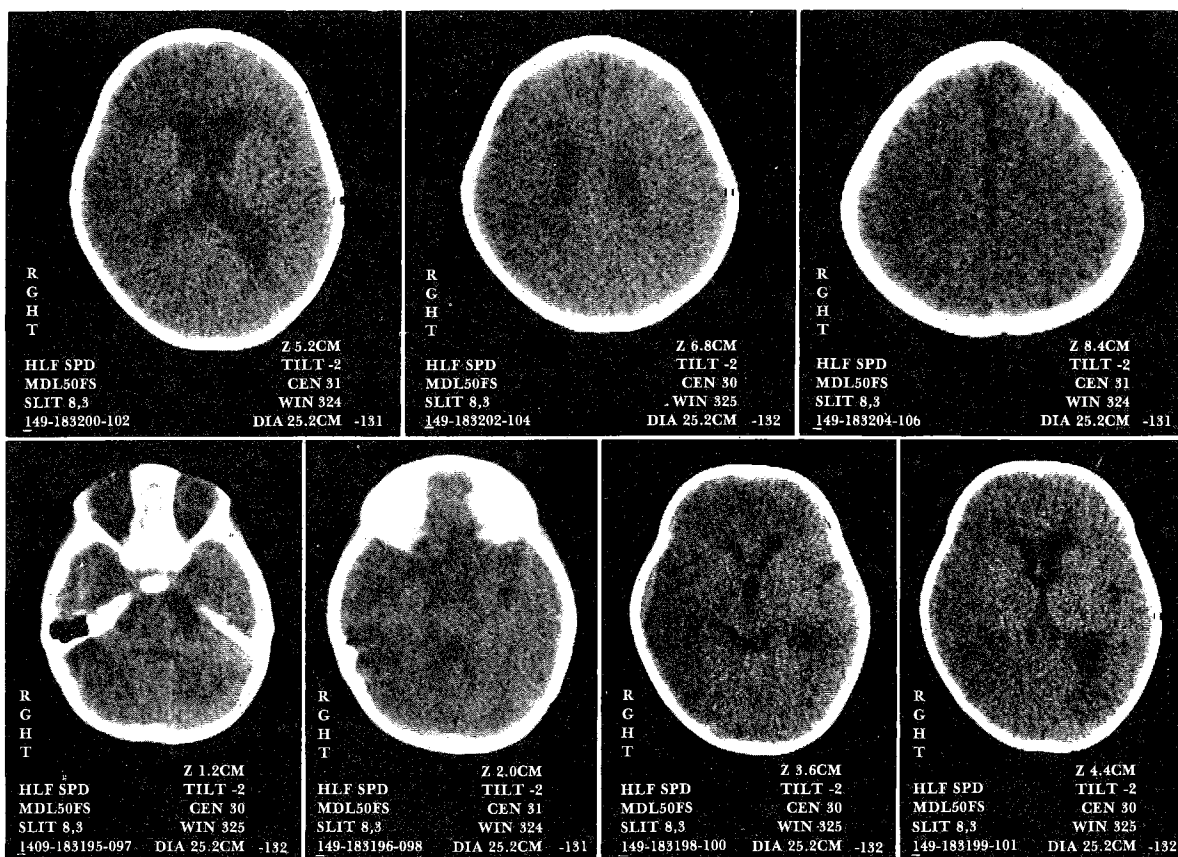


Fig. 2 Cat Brain Scan: Showing ventricular dilatation and cerebral global hypotrophy.

and died at home.

#### CASE II

The patient is the first child born to healthy non-sanguinous Chinese parents in Princess Alexandra Hospital, Sydney, Australia. There is no family history of retardation, fits or skin pigmentation. Her mother took oral contraceptives two months prior to pregnancy, and child was term and birth weight was 3.45kg. She was cyanosed at birth, and became pink with oxygen by mask. During post-natal checkup a pansystolic murmur was heard at left lower sternal edge. A clinical diagnosis of ventricular septal defect was made, and the child was treated with Digoxin. During infancy, she had frequent upper respiratory tract infections and showed features of failure to thrive. There was no history of fits. She was seen in Kota Bharu Hospital at fifteen months old, in 1982. Developmental milestones were delayed: she could sit at fourteen months, talked in monosyllables at seventeen months. She had hypopigmented whorls and

patches only on the left half of limbs and trunk: (Fig. 1). The right of limbs, trunk and vulva was relatively bigger than the left. She walked with a limp. Her left eye was small with enophthalmos. However, muscle tone and power were normal on both sides. Dentition was normal. Computerised tomography (Fig. 2a, 2b) reported there is moderate dilatation of the cisterns and sulci. The quadrigenuinal sinuses are larger than normal. The 4th, 3rd and both lateral ventricles are larger, the left being slightly larger than the right. The grey and white matter are within normal limits. The findings of generalised subarachnoidal space dilatation is compatible with moderate global atrophy. EEG findings show fairly symmetrical and moderate amplitude theta delta waves intermixed with fast activity. Periodic symmetrical theta waves at 5 — 6 Hz seen. No focal, generalised or temporal lobe spikes or spike wave activity seen. No 3 Hs spike wave activity or suppression waves noted. Impression: Normal EEG with no epileptic activity. Chromosomal studies were normal.

## DISCUSSION

Hypomelanosis of Ito presents as depigmented whorls, patches and streaks which may be bilateral (Case I) or unilateral (Case II). The skin lesions is believed to be genetically determined.<sup>2</sup> Mckusick, 1978<sup>3</sup> considered this an autosomal dominant entity, although in our two cases, there is no consanguinity of parents. Griffith *et al*,<sup>4</sup> however, have reported parental consanguinity twice. Donat *et al*,<sup>5</sup> reported severe left cerebral atrophy coinciding with right sided skin and nervous manifestations. This is not apparent in Case II. Case I presented with bilateral skin manifestations, recurrent seizures since birth and had severe mental retardation. Case II however, presented with unilateral skin manifestations but no fits, normal EEG, global cerebral atrophy and delayed milestones. She is closely followed up. Rubin,<sup>6</sup> believed this syndrome is due to neural crest development. In this disorder, there is reduction in melanocytes, histologically. This easily differentiates Hypermelanosis from Incontinentia Pigmenti (Bloch-Szhulburger Syndrome) because the abnormal side lesions are DEPIGMENTED, whereas the latter are HYPERPIGMENTED. Moreover other distinguishing features of Incontinentia Pigmenti may include patchy alopecia, eye conditions like retinal dysplasia, uveitis, keratitis, cataract and skeletal

abnormalities like hemivertebrae, extra rib and syndactyly.<sup>7</sup>

## ACKNOWLEDGEMENT

I wish to thank the Director General of the Ministry of Health for permission to publish, and Puan Kamariah and Puan Azizah for secretarial assistance.

## REFERENCES

- <sup>1</sup>Ito H. Studies on Melanin XI. Incontinentia pigmenti achromians. *Tohoku J Exp Med* 1952; 57-59.
- <sup>2</sup>David T J, Warin R P. Wasrdenburg's syndrome in siblings, both parents, and their grandmother. *Proc R Soc Med* 1972; 65, 601-2.
- <sup>3</sup>Mckusick V A. Mendelian inheritance in man. Catalogues of autosomal dominant, autosomal recessive, and X-linked phenotypes, fifth edition. Baltimore: Johns Hopkins University Press, 1978.
- <sup>4</sup>Griffith A, Payne C. Incontinentia pigmenti achromians. *Arch Dermatol* 1975; III, 751-2.
- <sup>5</sup>Donat J F, Walsworth D M, Turk L L. Letter: Focal Cerebral atrophy in incontinentia pigmenti achromians. *Am J Dis child* 1980, 134, 709-10.
- <sup>6</sup>Rubin M B, Incontinentia pigmenti achromians. Multiple cases within a family. *Arch Dermatol* 1972; 105, 424-5.
- <sup>7</sup>Smith D W, Recognisable patterns of human malformation, first edition. Philadelphia, W.B. Saunders Co. 1970.