

# ACTINOMYCOSIS OF THE SPINE : TWO CASE REPORTS

C. V. DAVID  
P. JAYALAKSHMI

## SUMMARY

*Two cases of Actinomycosis of the spine with paraparesis are reported. The characteristic radiological features involving both the vertebral bodies and the ribs are seen. Confirmation by means of histopathology and culture was necessary and both patients responded well to penicillin.*

## INTRODUCTION

Seventy-two cases have been reported since the organism was identified in 1891.<sup>1</sup> Actinomycosis involves the vertebra and ribs in less than one percent of patients.<sup>2</sup> This is an uncommon disease and the diagnosis can be difficult. It is important to distinguish the disease from tuberculous or pyogenic osteomyelitis. The mortality is high in the untreated case but patients respond well to long term penicillin therapy.

## CLINICAL RECORD

### Case I

In 1974, a 23 year old Malay man was first seen in another hospital with complaints of fever, cough, chest pain with multiple fleshy growths over the left anterior chest wall. Radiographs of the chest showed evidence of consolidation of the lingular lobe of the lung. During his two month stay in the hospital, these lesions became pustular with multiple discharging sinuses. The sinuses healed

spontaneously over a period of two months. A bronchogram done in 1975 was normal.

In 1976, there was recurrence of fever but this time there was swelling over the lumbosacral region with multiple discharging sinuses. During the next three years, he was seen many times but repeat cultures failed to reveal any specific infection. The lesions persisted and he was referred to the University Hospital, Kuala Lumpur in 1979.

On examination, he was very thin, afebrile and anaemic. There were healed sinuses over the left sternal border. The spine was stiff with no movement of the thoraco-lumbar spine. There were multiple sinuses over the lumbar and sacral region. The muscle power in the lower limbs was grade 4. There was no sensory deficit and the sphincteric function was normal.

Investigations revealed a haemoglobin of 9.5 g/dl, and a total leucocyte count of  $15,000 \times 10^9/l$ , with 80 percent neutrophils. The erythrocyte sedimentation rate was 82 mm in the first hour. Radiographs of the spine (Fig. 1 and 2) showed a paravertebral abscess with bone bridging anteriorly and laterally involving all the lumbar vertebrae. There were osteolytic lesions in the eighth to twelfth ribs. The chest radiograph showed pulmonary fibrosis in the (R) upper lobe with pleural thickening at the bases. Lipiodal sinograms showed the sinus to extend to the paravertebral lumbar spine. A biopsy of the sinus wall showed colonies of the actinomycosis (Fig. 4). *Actinomycosis israeli* was subsequently grown by culture.

The patient was treated with intravenous crystalline penicillin 4 million units 6 hourly for six weeks. The sinuses healed and the patient was fully ambulant within two weeks. He was discharged to continue penicillin therapy for another six months.

---

C.V. David, F.R.C.S. (Ed.), Lecturer,  
Department of Orthopaedic Surgery, Faculty of Medicine,  
University of Malaya, Kuala Lumpur 22-11.

P. Jayalakshmi, M.B.B.S., MPath., Lecturer,  
Department of Pathology, Faculty of Medicine,  
University of Malaya, Kuala Lumpur 22-11.

---

When he was last seen in November 1980, there was no evidence of the disease.

#### Case 2

The second patient, a 28 year old Malay woman, presented with continuous back pain that went on for six months. There was daily fever with chills and rigors. There was loss of weight with weakness of the lower limbs.

On examination, she was pale and thin. She was unable to walk because of pain and weakness. Spinal examination showed a paraspinal swelling extending from the seventh to the tenth thoracic vertebra. The muscle power in the lower limbs was grade four with brisk reflexes. The plantar reflex was downgoing.

Investigations revealed a haemoglobin on 7.9

g/dl with 79 percent neutrophils and a total leucocyte count of  $20,100 \times 10^9/l$ . The erythrocyte sedimentation rate was 140 mm in the first hour. Radiographs of the spine showed a paravertebral abscess from the seventh to the tenth thoracic vertebra (Fig. 3).

She underwent thoracotomy with drainage of the abscess. The diagnosis was confirmed by culture and histopathology. The patient was treated with intravenous penicillin and she was able to walk well three weeks after treatment was instituted.

#### DISCUSSION

Actinomycosis is a bacterial disease and hence responds to anti-bacterial drugs, such as penicillin and the tetracyclines. Prior to the use of penicillin, the prognosis for survival was poor and fifty of the

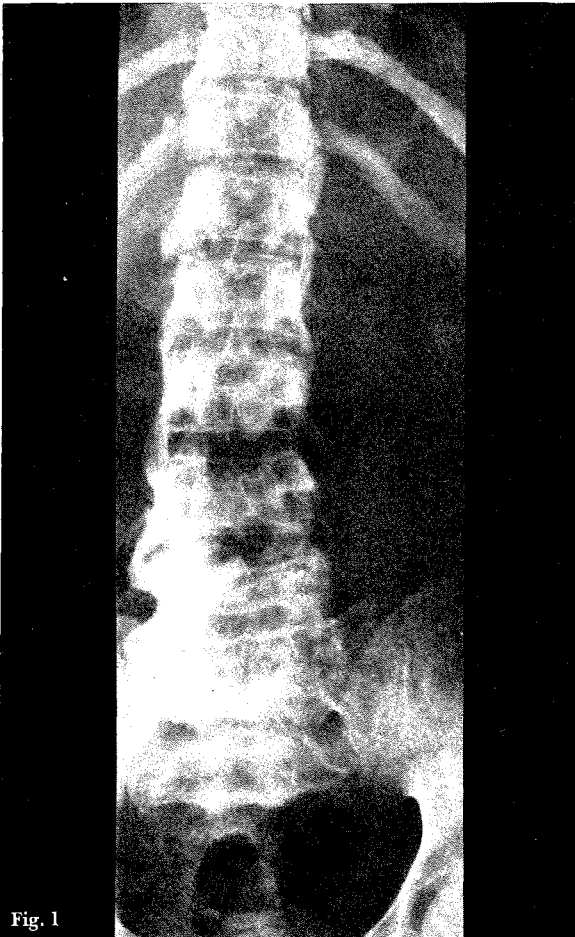


Fig. 1

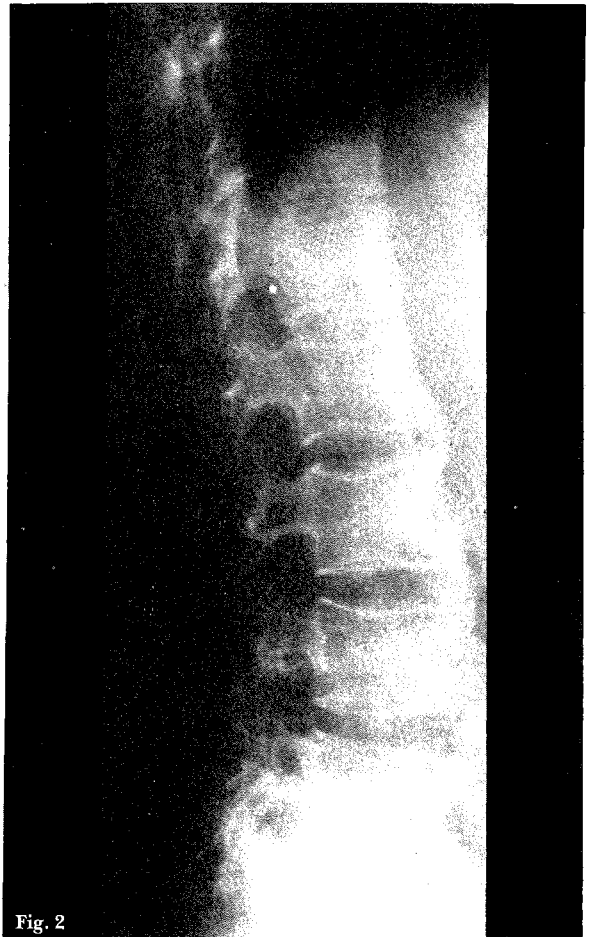

Fig. 2

Fig. 1 and 2 Antero-posterior and lateral radiographs of the thoraco-lumbar spine showing the paravertebral abscess, intervertebral fusion and erosions of the ribs. The disc spaces are normal.

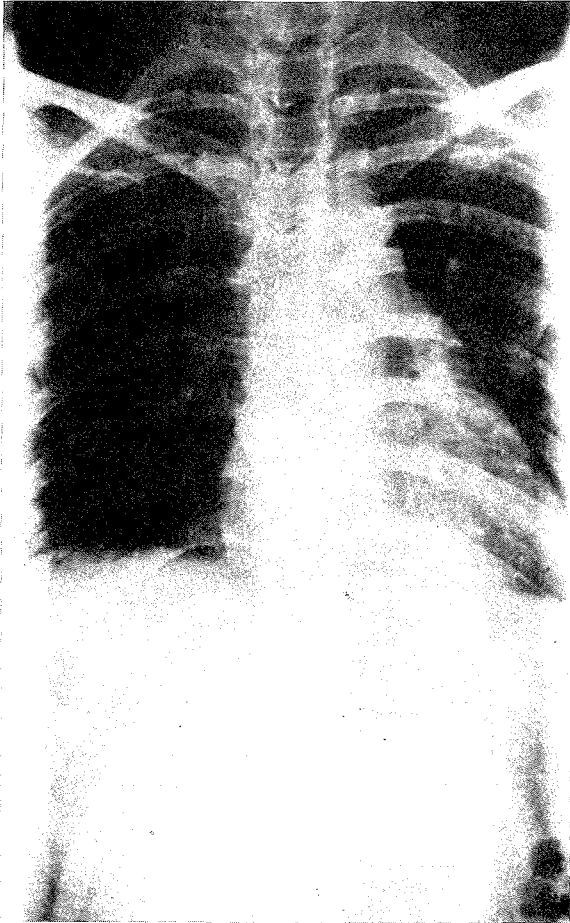


Fig. 3 Antero-posterior radiograph of the thoracic spine showing the paravertebral abscess from the seventh to the tenth vertebra with normal disc spaces.

seventy-two cases were diagnosed at post mortem.<sup>1,3</sup> Spinal actinomycosis is always secondary to an infection of contiguous tissue.<sup>4</sup> The diagnosis is often not made till a late stage and the first patient went on with short courses of various antibiotics for five years before the diagnosis was confirmed on histology and culture.

Unlike tuberculosis or pyogenic osteomyelitis, the disease rarely gives rise to destruction of the intervertebral discs.<sup>5</sup> There is destruction of the vertebral body with new bone formation early in the disease, resulting in a honeycomb appearance and often involvement of the pedicles, transverse processes and the ribs.<sup>6</sup> However, with treatment, there is increasing sclerosis with bone bridging and fusion.

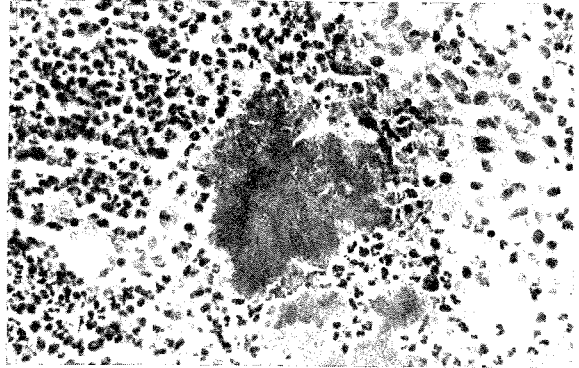


Fig. 4 Multiple abscesses consisting of colonies of Actinomycetes surrounded by numerous polymorphs, chronic inflammatory cells and multinucleated giant cells. (Magnification x 400).

Severe cord compression due to an epidural extension of the abscess may occur necessitating emergency decompression.<sup>1</sup> However, conservative treatment consisting of bed rest, antibiotic therapy with elective surgical debridement when needed are all that are usually necessary. Both our patients presented with paraparesis but there was complete recovery with penicillin therapy.

## REFERENCES

- <sup>1</sup> Kannagara D W, Tanaka T and Thadepalli H. Spinal epidural abscess due to Actinomycosis Israeli. A Case Report. *Neurology* 1981; 31 (2) : 202-204.
- <sup>2</sup> Sanford A H and Voelker M. Actinomycosis in the United States. *Archives of Surgery* 1925; 11 : 809.
- <sup>3</sup> Ernest J and Ratjen E. Actinomycosis of the Spine : Report of two cases. *Acta Orthop. Scand.* 1971; 42 : 35-44.
- <sup>4</sup> Cope V.Z. Actinomycosis of bone with special reference to infection of the vertebral column. *J. Bone Joint Surg.* 1951; 33 : 205-214.
- <sup>5</sup> Young W B. Actinomycosis with involvement of the vertebral column. Case report and review of the literature. *Clinical Radiology* 1960; 11, 175-182.
- <sup>6</sup> Pritchard D J. Granulomatous infections of bones and joints. *Orthop. Clin. of North America* 1975; 6 : 1029-1047.