

ENDOSCOPIC TRANSGASTRIC DRAINAGE OF PSEUDOPANCREATIC CYST

H. M. M. BAHARI

ISMAIL ABDULLAH

SUMMARY

There are many techniques of drainage of a pseudopancreatic cyst. We are describing a new method of drainage by an endoscopic transgastric route.

INTRODUCTION

Pseudopancreatic cyst is an uncommon but not a rare complication of acute pancreatitis and injury to the pancreas. Majority of the large pseudopancreatic cysts need drainage. The early method of drainage by marsupialisation is rarely practiced because of the high incidence of secondary infection, cutaneous digestion of skin of the abdominal wall and residual persistent fistula. Internal drainage by cystogastrostomy or cystojejunostomy depending on the location of the cyst, is the commonest method of treatment. Excision of pseudopancreatic cyst and ultrasonically guided aspiration have been carried out in selected cases.¹ We are reporting a case of cyst drained by endoscopic transgastric method and suggesting this as a new method of treatment which can be performed under local anaesthetic and does not require abdominal exploration.

MATERIALS AND METHOD

The following instruments were used: Olympus GIF-Q endoscope, Diathermy cutter - needle type (KD-IL), Coagulation electrode - ball point (CD-IL), Electrosurgical unit - model UES, Olympus Co, and Injector needle (NM-3K).

Endoscopic examination is carried out after spraying the throat with lignocaine and intravenous valium. The posterior wall of the stomach is

examined and the site of maximum convexity away from lesser and greater curvature is selected for drainage. The diathermic cutter is passed through the endoscope and the posterior gastric wall incised for about one cm in length. Bleeding points are coagulated with ball point coagulation electrode.

CASE REPORT

The patient, a 42 year old Indian male labourer was referred from a district hospital to General Hospital, Kuala Lumpur on 18th. February, 1982 with a diagnosis of acute pancreatitis. He complained of severe abdominal pain and vomiting for three weeks before admission. At the district hospital a diagnosis of acute pancreatitis was made and resuscitation was carried out. The symptoms persisted and the serum amylase was persistently elevated and he was referred after two weeks.

He had similar episode in 1980. He is a known chronic alcoholic.

On examination, his general condition was fair but toxic looking. His temperature was 38.8°C. Pulse rate was 110/min. and blood pressure 110/70 mmHg. The respiratory rate was 28/min. and he was dsypnoeic. There was bilateral ankle oedema. He was jaundiced. There were crepitations at bases of both lungs. The abdomen was distended and there was a tender fixed mass 9 x 12 cm in the epigastrium. Liver, spleen, and kidneys were not palpable. There was no ascites.

A diagnosis of acute pancreatitis with pseudopancreatic cyst was made. His heamoglobin was 7.4 gm/100 ml. Total white blood cells was 14,600 with different count of neutrophil 88% and lymphocytes 12%. Serum electrolyte estimation showed sodium 137 mmol/litre, potassium 2.1 mmol/litre, and chloride 100 mmol/litre. The blood urea and glucose were 9 and 5.7 mmol/litre respectively. The total plasma bilirubin was 28 mmol/litre with 70% of conjugated type. Serum alkaline phosphatase was 180 international unit/litre. Serum albumin was 46 gm/litre and globulin 19 gm/litre. Serum

H. M. M. Bahari, M.B.B.S., F.R.C.S.(E)

Ismail Abdullah, M.B.B.S., F.R.C.S.(E)

Department of Surgery,
Universiti Kebangsaan Malaysia,
Kuala Lumpur.

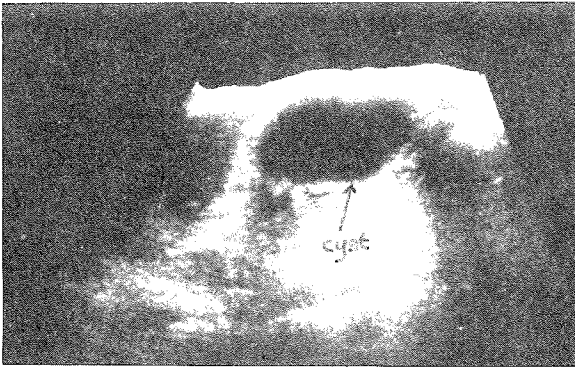


Fig. 1 First ultrasound showing cyst lesion about 9.6 cm diameter (pre-drainage).

amylase was 3,000 international units. Serum calcium and phosphate were 2.89 and 1.64 mmol/litre respectively. Blood gases investigation showed pH 7.4 mmol/litre, pO_2 10.5 k Pa and oxygen saturation of 97.1%.

Barium meal on 25th. February showed a retrogastric mass, displacing the stomach anteriorly. Ultrasound on 4th. March, 1982 showed cystic lesion about 9.6 cm diameter (Fig. 1).

Immediate resuscitation measures were commenced on admission. Anaemia was corrected by blood transfusion and he was put on intravenous antibiotic, claforan 2gm twelve hourly and flagyl 500mg six hourly. Following this; improvement was noted but there was still persistent swinging fever. The epigastric mass became non-tender. Repeated serum amylase estimations ranged from 1,200 — 6,240 international units.

It was decided to drain the cyst internally about three weeks after admission. On 9th, March 1982 at gastroscopy the posterior wall of stomach was seen to be bulging from a mass behind the stomach. Transgastric aspiration through the endoscope performed but only 0.5 cc clear fluid was obtained. The cyst was drained through the posterior wall of stomach endoscopically by the method described above. Ultrasound on the 11th. March, 1982 showed that the cyst had decreased in size (Fig. 2). Barium meal examination on 15th. March, 1982 showed the previous mass had reduced in size. There was no complication during the post drainage period. The patient's general condition improved and the jaundice disappeared. The epigastric mass disappeared and there was no significant tenderness on the abdomen. The serum amylase level gradually came down to 300 international units.

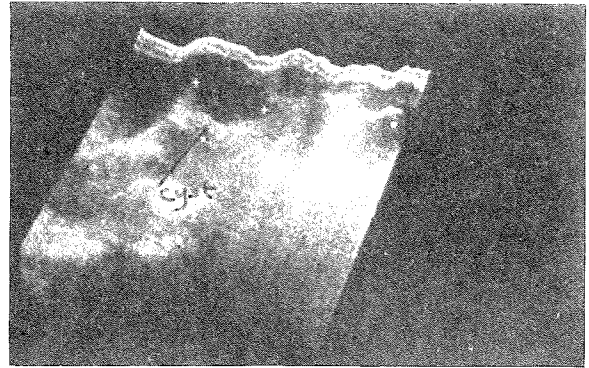


Fig. 2 Second ultrasound showing cyst decreased in size. (post-drainage).

After drainage, the temperature remained persistently elevated and there was diffuse bilateral pulmonary crepitation. A diagnosis of bronchopneumonia was made and confirmed radiologically. Sputum culture revealed pseudomonas sensitive to amikacin; and this antibiotic was given in addition to claforan and flagyl which the patient was already receiving. He developed multiple metastatic abscesses on lower limbs, and incision and drainage were carried out. On 3rd. April, 1982 he had sudden cardiorespiratory arrest. He did not respond to resuscitation and succumbed the same day. Blood culture showed pseudomonas sensitive to amikacin.

COMMENTS

There are several methods which are used for drainage of pseudopancreatic cyst. The use of ultrasound has increased the accuracy in diagnosis and the ease of monitoring the size of the cyst and thus the view on treatment of pseudocyst has changed. Transcutaneous drainage with a guided needle or tube is a relatively new method and useful in sick patients. To the above method we add another new technique i.e. endoscopic transgastric drainage of pseudocyst. This method is useful in patients where the pseudocyst is large and situated behind the stomach.

The patient died about one month after drainage due to pseudomonas pneumonia and septicemia which did not respond to antibiotic therapy. There was no clinical evidence of leakage. Permission for autopsy was not granted.

REFERENCE

- 1 Trevor Sandy J, Taylor R H, Ralph M, Christensen *et al* (1981) Pancreatic Pseudocyst — Changing concepts in management. *Am. J. Surg.* 141, 574-576.