

PARAQUAT POISONING: A CLINICAL AND EPIDEMIOLOGICAL REVIEW OF 30 CASES

CHAN K.W.
CHEONG. IZHAM K.S.

SUMMARY

There is evidence to show that paraquat poisoning is alarmingly common in Malaysia. This paper reviews 30 cases of paraquat poisoning seen at the General Hospital, Kuala Lumpur from 1978 to 1979 inclusive. Preventive measures and management are discussed. It is felt that tighter legislation to control its use in agriculture should be implemented now.

INTRODUCTION

Paraquat is a very potent herbicide widely used in Malaysia for agricultural purposes. It is easily available to the public and as such it has become one of the commonest modes of poisoning, both accidental and intentional. Various reports^{1,2,3} indicate that the incidence of paraquat poisoning in this country has become unacceptable. Mortality is very high and ingestion of even a small quantity leads to death.

This paper reviews the epidemiological and clinical aspects of 30 cases of paraquat poisoning seen over a 2-year period from January, 1978 to December, 1979, at the General Hospital, Kuala Lumpur. Preventive measures and management are discussed. All those cases gave a history of

paraquat ingestion or a positive test for paraquat in the urine, ¹ blood or gastric aspirate.

PATIENTS

Race, age and sex

Indians formed the largest group, accounting for 20 cases (66.6 percent). Both Indian male and female appeared to be equally at risk. There were 4 female Malays and 6 Chinese (Fig. 1).

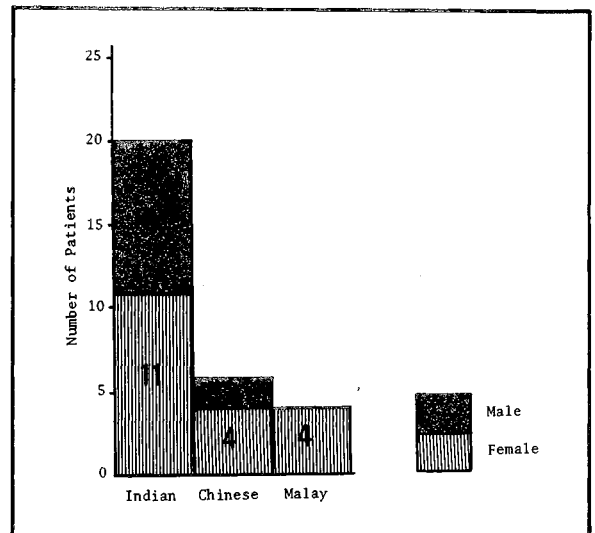


Fig. 1 Distribution by race and sex of 30 cases of paraquat poisoning seen at the General Hospital, Kuala Lumpur.

The age range of the patients was from 15 to 65 years. Most of the patients were in the age group 15 - 29 years. The mean age for the female was 26 years. Male cases were generally older with a mean age of 32 years (Fig. 2).

Chan K W, MBBS (Malaya) MRCP (UK)
Lecturer, Department of Medicine,
Cheong Izhah K S, MBBS (Malaya), MRCP (UK)
Lecturer, Department of Medicine,
Faculty of Medicine,
Universiti Kebangsaan Malaysia,
Kuala Lumpur.

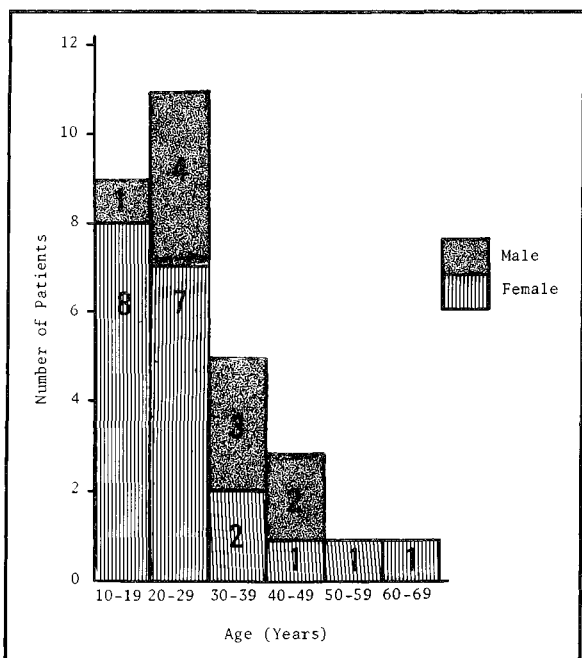


Fig. 2 Distribution by age and sex of 30 cases of paraquat poisoning seen at the General Hospital, Kuala Lumpur.

Geographical Distribution

There were 6 cases in the densely populated Federal Territory of Kuala Lumpur and they came from estates in Sungei Buluh and Gombak (Fig. 3). The remainder were from the numerous estates scattered throughout Selangor and adjacent states.

Suicidal and accidental poisoning

Nine cases (30 percent) were accidental and 21 cases (70 percent) were suicidal. In accidental poisoning, the patients consumed the paraquat left in unlabelled bottles or cups. Four patients mistook it for coffee and 1 for beer. In suicidal poisoning the precipitating factors were as follows: 5 cases of quarrel, 3 cases of depressive illness, 3 cases of abdominal pain and 1 case of post-partum psychosis. The remaining 9 cases of suicidal poisoning either kept silent when questioned or were too moribund to answer.

Amount of paraquat ingested

The amount of paraquat ingested can only be approximated. It varied from a 'teaspoon' to 'a glass' which is roughly equivalent to 1 g to 30 g paraquat.

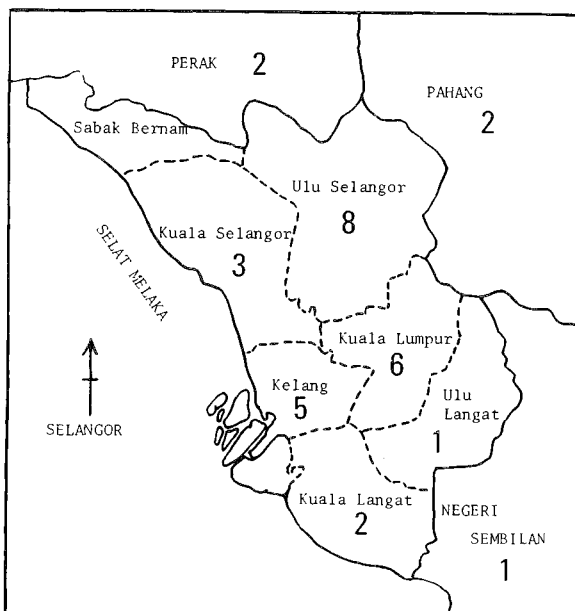


Fig. 3 Geographical distribution of 30 cases of paraquat poisoning seen at the General Hospital, Kuala Lumpur.

The commonest descriptive phrase used was 'a mouthful'.

CLINICAL FEATURES

Out of the 30 patients in this study, vomiting occurred in 24 cases about 15 minutes after ingestion of the paraquat. Dyspnoea was noted in 19 cases and was followed by a rapidly progressive downhill course. Burning sensation and pain in the throat and epigastrium occurred soon after ingestion in 18 cases but mouth ulcerations were obvious only after 12 - 24 hours. Oliguria (18 cases) and jaundice (16 cases) were noted after 1 - 3 days of poisoning. Other clinical features included, dysphagia (12 cases), cyanosis (7 cases), drowsiness (6 cases), diarrhoea (5 cases), and haemetemesis (2 cases). Of the less common clinical features, convulsions were present in 2 severe poisonings resulting in death within 24 hours. One case developed subcutaneous emphysema.

INVESTIGATIONS

Neutrophilic leucocytosis was common. Renal and liver dysfunction were noted 1 to 3 days after poisoning and were characterised by raised blood urea, serum creatinine, serum bilirubin and

transaminases. The blood gases analysis (17 cases) showed metabolic acidosis, low PaO₂ (PaO₂ < 10 kPa) and low PaCO₂ (PaCO₂ < 4.8 kPa). PaCO₂ was elevated terminally. A restrictive ventilatory defect was demonstrated in 2 patients. Chest X-ray in 17 patients showed acute pulmonary oedema and granular pulmonary opacities appearing as early as the third day.

TREATMENT AND OUTCOME

The various types of treatment given were gastric lavage (18 cases), hydrocortisone (11 cases), forced diuresis (6 cases), haemodialysis (6 cases), paraquat absorbents (4 cases), peritoneal dialysis (2 cases) and haemoperfusion (1 case). Treatment was started as early as 30 minutes to as late as 7 days after poisoning. Fifteen cases (50 percent) received treatment more than 6 hours after poisoning. It should be noted that generally treatment was delayed and not vigorous enough.

There were 27 deaths and 3 survivors. The 27 deaths occurred from 5 hours to 22 days after ingestion with a mean survival time of 5 days. Twenty-two patients (81 percent) died within 7 days of poisoning. Generally survival time was proportional to the amount of paraquat ingested. Early deaths were due to severe shock from wide spread tissue damage and resuscitation measures were often futile. Late deaths (patients surviving more than 7 days) were due to respiratory failure from proliferative alveolitis, bronchiolitis and extensive pulmonary fibrosis. All 3 patients who survived ingested small amounts of paraquat accidentally and were given immediate treatment. One of the survivors had residual left upper lobe fibrosis radiologically at discharge 5 weeks after paraquat ingestion.

DISCUSSION

Paraquat is a bipyridyl herbicide that was first available commercially in 1963. It has the unique property of being completely inactivated by clay in the soil and hence there is no residual soil pollution. Presently there are 28 commercial preparations of paraquat liquid concentrate available in Malaysia and Gramoxone which comes as reddish brown concentrate accounts for 80 percent of the total sale. Paraquat granules and aerosol are not available in Malaysia.

Paraquat is poorly absorbed from the gastrointestinal tract (6-10% of ingested dose) and up to

90 percent is rapidly excreted by the kidneys within 2 days. Systemic toxicity in man is caused by the formation of superoxide and peroxide ions which produce widespread cellular damage particularly to the lungs causing pulmonary oedema, haemorrhage and proliferative bronchiolitis and alveolitis as a terminal event. Other injuries include acute tubular necrosis, centrilobular necrosis of the liver, focal toxic myocarditis, adrenal cortical necrosis and cerebral oedema and haemorrhage.

Bullivant⁴ reported the first fatalities in man from paraquat poisoning. From 1964 to 1973, 24 cases of poisoning were reported in Malaysia by Fletcher.¹ Our paper reports 30 cases over only a 2-year period seen at the General Hospital, Kuala Lumpur and this may only be the 'tip of an iceberg' as many cases are managed in the peripheral hospitals. This alarming increase deserves our attention and preventive measures must be implemented to reduce this high incidence.

There is no substitute for the careful handling of paraquat. Attempts to alter the paraquat formulation by smell, colour, viscosity and emetic are really not useful in our context, as the majority of the paraquat poisoning is intentional and suicidal patients are not likely to be deterred by changes in formulation. We feel that stringent and carefully enforced legislation regarding the use of paraquat would be most likely to succeed. Paraquat concentrate should be made available for agricultural purposes only and not for domestic uses. Agricultural workers should wear gloves while handling paraquat and mask when using the spray.

Examining the geographical distribution, it is easy to understand why Indian patients formed the predominant racial group since they are the main work-force in estates where paraquat is used extensively. Therefore strict supervision must be exercised over its use in estates and estate labourers must not decant the concentrate for domestic uses. It is noteworthy that Malay males were not involved in paraquat poisoning in this study, the probable reason being that poisoning in general is not a favoured method of suicide in Malay males. In suicidal poisoning the common precipitating factors in females were quarrel and intolerable abdominal pain, and in males, depression because of unemployment. The quarrel in females was generally trivial and often followed a reprimand from the husband or mother.

The dangerous habit of decanting paraquat into

unlabelled common household bottles should be made illegal by legislation as paraquat is often mistaken for Coca-Cola, root-beer or coffee. In England, enforcement of these legislations has resulted in fewer cases and we feel that Malaysia would benefit from similar measures. A national register on paraquat poisoning would be useful and the overall situation should be carefully reassessed.

The clinical features of paraquat poisoning are well recognised. However 2 observations are made from this study: 1) In any case of unknown poisoning, paraquat must be suspected when the patient has painful mouth ulcers, acute renal failure and liver dysfunction. 2) Dyspnoea is an ominous sign followed by a rapidly progressive downhill course.

Management of paraquat poisoning has been dealt with previously by various authors.^{1,3,5,6} Despite its notorious reputation, paraquat poisoning is not invariably fatal as testified in 3 of our cases and in a recent regional report.⁷ However treatment must be immediate and intensive, and is aimed primarily at minimising paraquat absorption from the gastrointestinal tract and eliminating paraquat that has already been absorbed. Attempts to modify the cellular toxicity of paraquat have been disappointing.

Immediate removal of ingested paraquat from the gastrointestinal tract is most essential. As a first aid measure, vomiting must be induced if the patient is not already vomiting. Stimulation of the pharyngeal wall using a spoon is an effective method. At the hospital of first contact, gastric lavage via a nasogastric tube should be performed followed by giving up to a litre of absorbent suspension (30% Fuller's earth or 7% bentonite) plus 50 g magnesium sulphate. The subsequent dosage is 250 - 500 ml of absorbent suspension every 2 hours for the first 24 hours and then every 4 hours for the next 24 - 48 hours; magnesium sulphate is given as required to ensure an adequate throughput of absorbent. Fuller's earth 'locks' the paraquat into an inert nonabsorbable Fuller's earth-paraquat complex which is then eliminated from the gut by magnesium sulphate.

The dithionite test for urinary paraquat¹ is helpful and it is sufficiently accurate that gastrointestinal absorption is not significant if the test is negative in the first 2 days following paraquat ingestion. Paraquat is preferentially concentrated in the lungs and early attempts to effect removal of

absorbed paraquat from the blood is necessary. Forced diuresis, haemodialysis and haemoperfusion effectively accelerate paraquat excretion and combined use is preferable. Forced diuresis for 24 - 48 hours is done via a central venous pressure line using mannitol and saline, and careful monitoring of fluid and electrolytes status on a daily basis is important. If acute renal failure or acute pulmonary oedema is present, forced diuresis is contraindicated. Haemodialysis and haemoperfusion effectively remove paraquat from the blood; unfortunately once tissue bound, attempts to modify its cellular toxicity have not been inspiring. Newer aspects of therapy have been reported by Fairshter⁸ involving the use of haemodialysis with ultra filtration, d-propranolol, hypoxic breathing mixtures and superoxide dismutase. Lately plasmapheresis has been used with varying degrees of success.⁹

ACKNOWLEDGEMENT

We are grateful to Dr. Abdul Majid bin Tun Dr. Abdul Aziz and Dr. Abu Bakar Suleiman for permission to use their patients, and Miss Poh Siew Kuan for typing the manuscript.

REFERENCES

- ¹ Fletcher K (1974). Paraquat poisoning, *In* Ballantyne B. (ed) : Forensic Toxicology, Bristol, 86-98.
- ² Ng T S, Thong K W (1978). Paraquat poisoning, *Med. J. Malaysia*. 32, 278-281.
- ³ Chan K W, Chong S M, Zulkifli A (1980). Paraquat poisoning — A report of 3 cases, *Med. J. National University of Malaysia*. 2, 41-49.
- ⁴ Bullivant C M (1966). Accidental poisoning by paraquat: A report of two cases in man, *Br. Med. J.* 1, 1272-1273.
- ⁵ Editorial (1971). Paraquat poisoning, *Lancet*. 2, 1018-1019.
- ⁶ Fairshter R D (1978). Paraquat poisoning: An update, *West J. Med.* 128, 56-58.
- ⁷ Fock K M, Chan H C, Khoo T K (1980). Paraquat poisoning is not always fatal, *Singapore Med. J.* 5, 703-707.
- ⁸ Fairshter R D, Rosen S M, Smith W R, *et al.* (1976). Paraquat poisoning: New aspects of therapy, *Q.J. Med.* 45, 551-565.
- ⁹ Dearneley D P, Martin M F R (1978). Plasmapheresis for paraquat poisoning, *Lancet*. 1, 162.