

ULTRASOUND AND ABDOMINAL MASSES

AHMAD KAMAL BIN MD ALIF

INTRODUCTION

It is approximately 30 years since ultrasound was first introduced into the field of medicine, and thanks to the progress of medical electronics, it is now one of the most useful imaging techniques. By using the property of ultrasound as waves, ultrasound is emitted into the living body and the returning echoes or waves are detected. This diagnostic information is displayed on a cathode-ray tube as an image for diagnosis.

The common frequency range used in diagnostic ultrasound is 1 to 10 megahertz. For abdominal examination, the usual frequency used is 2.5 megahertz. In the pulsed-echo technique, ultrasound waves are emitted as pulsed waves by the transducer into the patient. The returning waves or echoes which are reflected from the interface between different organs or between different tissues within an organ are displayed on the cathode-ray tube as two-dimensional image, and as the grey-scale image on the television screen.

However, not all organs are available for imaging by ultrasound. Organs containing air, such as lungs and the digestive tract, cannot be scanned. The other limitation of ultrasound is the brain which is protected by the skull bones which attenuate the ultrasound waves by absorption and scatter.

Ahmad Kamal Bin Md Alif
M.B.B.S. (Malaya), D.M.R.D. (London)
F.F.R.R.C.S. (Ireland), F.R.C.R. (London)
Radiology Department,
Universiti Kebangsaan Malaysia,
Kuala Lumpur.

ADVANTAGES OF ULTRASOUND

At the present moment, ultrasound as used for medical imaging is safe. Its other advantages can be listed as follows:-

1. Non-invasive.
2. Well tolerated by patients - no elaborate preparation required.
3. Not time consuming.
4. Diagnosis can be made at the time of examination.
5. Images can be recorded and reproduced easily.
6. Extra information can be obtained, e.g. lesions or diseases in soft tissues. This is not possible with conventional radiography.
7. Serial scanning shows progress of lesion.

The ultrasound pictures as displayed by both 'A' and 'B' scans contain useful information from which a reasonable, if not accurate, conclusion and diagnosis can be made. Hence, the existence of disease in an organ or tissues, its location, size and spread of lesion, as well as its nature (solid or cystic), can be deduced. Further, comparison with previous scans may show progress of a lesion.

LOCAL EXPERIENCE

Until recently, the Faculty of Medicine, Universiti Kebangsaan Malaysia, was the only centre in Malaysia with an ultrasound imaging facility. It is therefore not surprising why it became the referral centre for the country.

The reason why this useful imaging tool is not available in other major centres in the country is

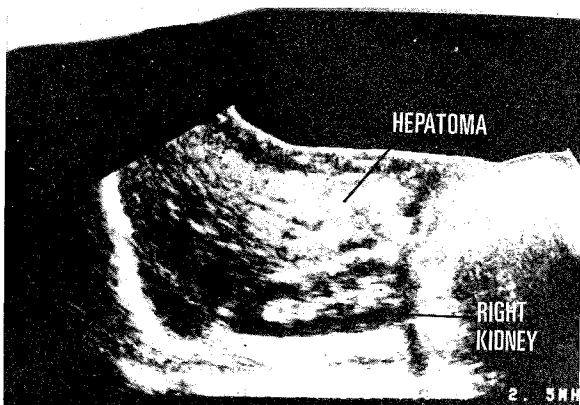


Fig. 1 Longitudinal scan of the liver showing hepatoma of the right lobe.

basically due to lack of trained personnel. This again reflects on the shortage of radiologists in the country.

The ultrasound unit used in our department is the NE Disonograph 4200 scanner with a frequency range of 1.5 Megahertz to 10 Megahertz. (We have since acquired another unit, Philips Sonodiagnost B 52, with both realtime and contact compound facilities). My experience over the past 2 years involved mainly scanning of the abdomen and pelvis. Apart from the normal obstetrics cases (usually for biparietal diameters and placental scans), we get referrals from the surgical, medical and paediatric wards for palpable masses in the abdomen and pelvis.

Some examples of lesions involving the various organs over the 2-year period are discussed.

LIVER

Among the upper abdominal masses referred to the ultrasound unit, the liver masses form the largest group.

The hepatomas show high echo patterns, except in areas where necrosis has taken place, in which case the scans show low-level echoes. Majority of the tumours occur in the right lobe. Fig. 1 shows a typical right lobe hepatoma scan.

The ultrasound picks up hepatomas easily and a diagnosis can be fairly accurate. This examination also localises the lesion for biopsy. Liver tumours in childhood, such as hepatoblastoma, have also been

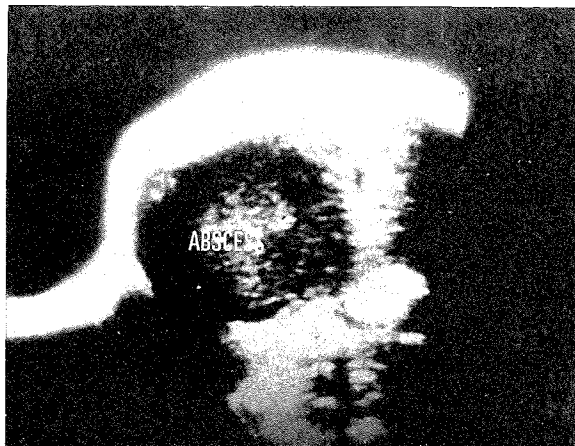


Fig. 2 Transverse section of the liver showing a large right lobe abscess.

detected.

The liver abscesses show up as low level echoes, and occasionally mixed pattern is seen where the abscesses are surrounded by thick walls and containing debris. In my series, liver abscesses are common among the Indian race and less common among the other two major races in Malaysia, namely the Malay and Chinese ethnic groups. Most liver abscesses are seen in the right lobe and a typical scan is shown in Fig. 2. Small abscesses treated with flagyl can be followed up to show regression of the lesion.

Cirrhosis of liver shows up as areas of high density echoes interspersed with some areas of normal liver. In some cases there is associated presence of ascites, (Fig. 3).

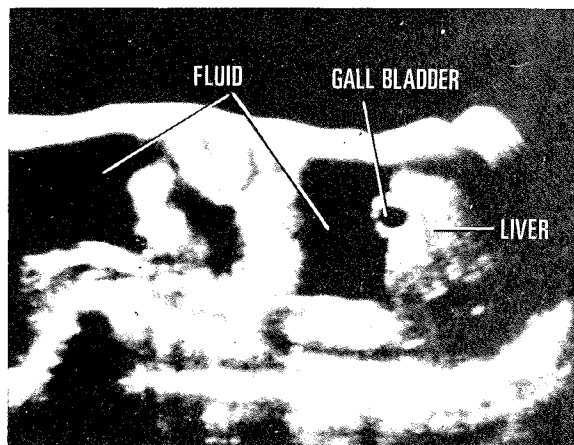


Fig. 3 Longitudinal scan showing ascites and a cirrhotic liver.

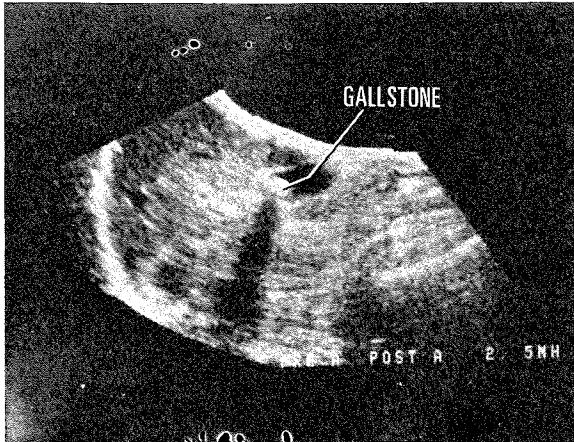


Fig. 4 Longitudinal scan of the liver and gallbladder which contains a stone. Note the acoustic shadow distal to the stone.

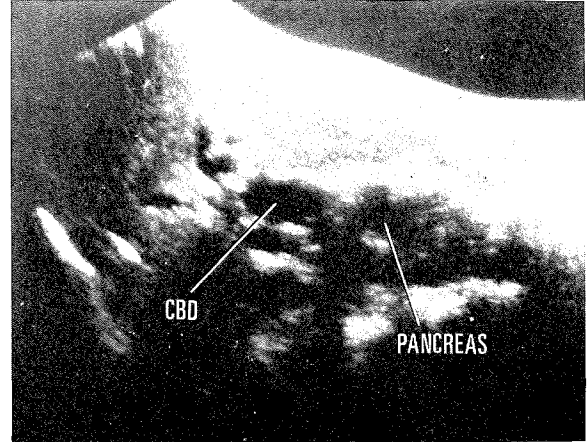


Fig. 5 Longitudinal scan showing dilated intrahepatic ducts and common bile duct (CBD), due to carcinoma of the head of pancreas.

Secondary deposits in the liver from known primary sites are also detected on the ultrasound scans and this plays a significant part in the staging of a carcinoma.

Ultrasound also helps in distinguishing obstructive from non-obstructive jaundice. A quick scan may reveal dilated intrahepatic as well as common bile ducts in carcinoma of the biliary tract or head of pancreas.

GALL BLADDER

The gallbladder is routinely scanned for lesions such as gallstones. The left lateral decubitus position is useful in scanning of the gallbladder. The gallbladder commonly dilates in carcinoma of the head of pancreas with obstruction of the biliary tract. Fig. 4 shows a gallstone on the ultrasound scan.

PANCREAS

The pancreas is routinely scanned in jaundiced cases. Acute pancreatitis shows predominance of high level echoes. Calcifications may be detected in chronic pancreatitis. Occasionally a dilated pancreatic duct can be shown.

Carcinoma of the head of pancreas generally shows presence of low-level echoes on the 'A' scan. Mixed echo pattern may be seen in the presence of chronic pancreatitis. The head of the pancreas in all cases shows enlargement. Fig. 5 shows an advanced carcinoma of the head of pancreas.

Pseudocyst of the pancreas shows up on the scan as a transonic mass closely related to the pancreas.

BILIARY DUCTS

The problem of jaundice in infancy is well known. However, choledochal cyst is easily picked up on ultrasound scanning and no radiological examination is usually necessary. A typical choledochal cyst seen on an ultrasound scan is shown in Fig. 6.

Stones and carcinoma of the common bile duct, glands in the porta hepatis, and malignancy involving the Ampulla of Vater generally show dilated ducts on ultrasound scanning. Majority of these patients require either percutaneous transhepatic cholangiogram or E.R.C.P. examination before a definite diagnosis is made.

KIDNEYS AND ADRENALS

Renal masses form the next largest group. Ultrasound is very useful in imaging kidneys not shown on intravenous urograms. Thus, hydronephrosis, polycystic kidneys and carcinomas can be shown. The two commonest lesions detected on ultrasound are benign cysts and carcinoma. Majority of these cases already have intravenous urograms. Fig. 7. and Fig. 8 show scans of renal cyst and carcinoma, respectively.

We have also seen childhood tumours such as nephroblastoma and neuroblastoma.

The Kuala Lumpur General Hospital is also the

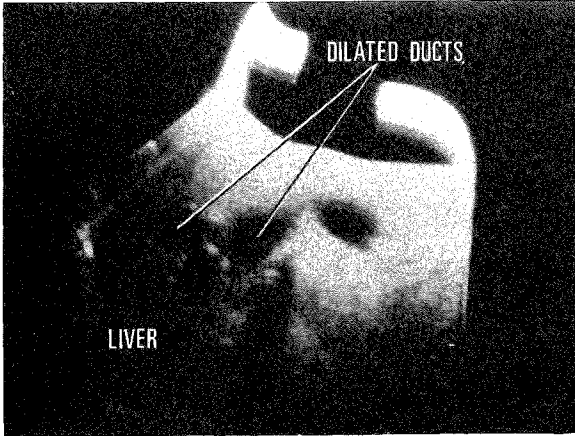


Fig. 6 Longitudinal scan showing dilated biliary ducts in choledochal cyst.

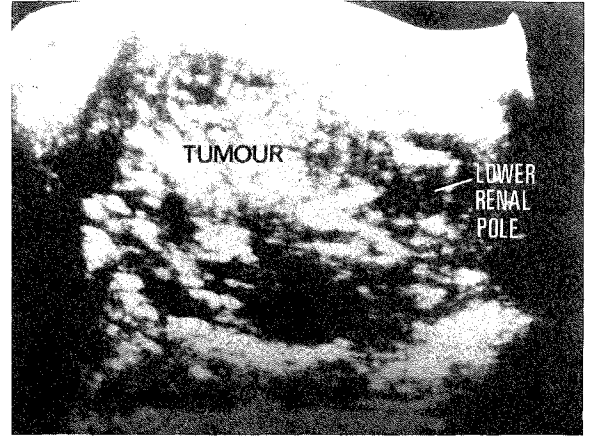


Fig. 8 Prone longitudinal scan showing bizarre pattern of an advanced renal carcinoma.

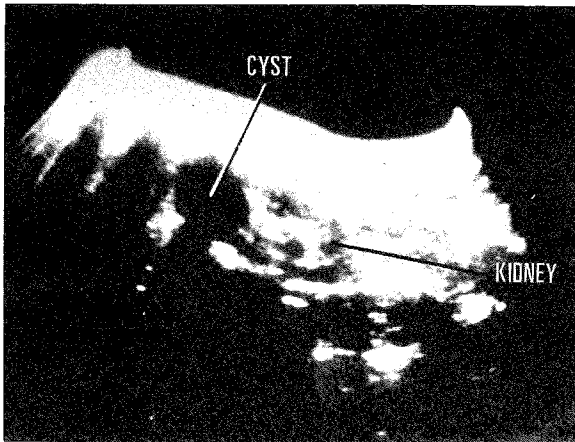


Fig. 7 Prone longitudinal scan showing a cyst at the upper pole of a kidney.

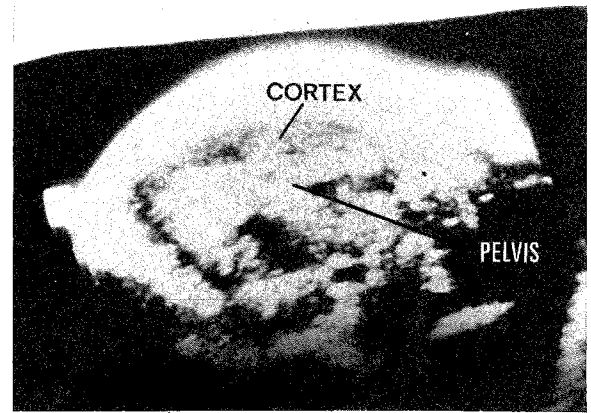


Fig. 9 Transverse section across a transplanted kidney. Note the high cortical echoes suggesting rejection.

centre for renal transplantation and post-operative management includes ultrasound of the transplanted kidneys. Subsequent ultrasound scans are done on those who develop rejection which on ultrasound may show high-level echoes in the renal cortical areas. Fig. 9 shows rejection in a transplanted kidney.

Perinephric abscesses have also been shown on ultrasound. One particular patient had a perinephric abscess communicating with a psoas abscess from tuberculosis, (Fig. 10).

AORTA

Aneurysmal dilatation of the abdominal aorta clinically present as a pulsatile mass, and apart from confirming the diagnosis, the effective lumen of the

vessel as well as the amount of thrombus present, can be shown on ultrasound. Dissecting aneurysms have also been detected as shown in Fig. 11.

In my experience, it is difficult to assess involvement of the renal arteries.

ENLARGED NODES

Enlarged abdominal lymph nodes by lymphomas or secondary deposits such as carcinoma of the rectum and seminomas can be picked up by the ultrasound scans, (Fig. 12). A patient who had a Wilm's tumour removed three years previously came back to the renal unit with gradual enlargement of the abdomen and ultrasound scans showed involvement of the abdominal nodes.

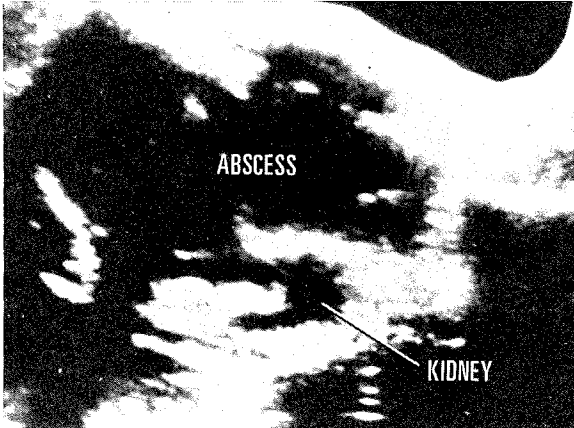


Fig. 10 Prone longitudinal scan showing a psoas abscess communicating with a perinephric abscess.

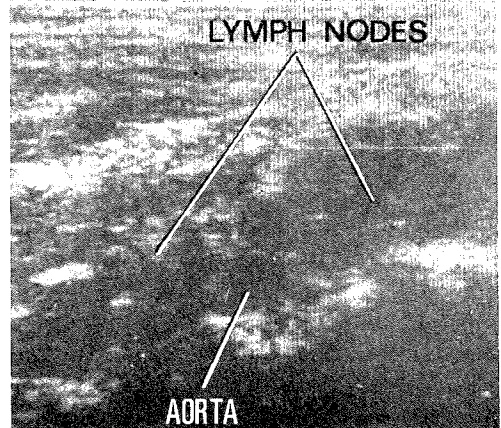


Fig. 12 Longitudinal scan of the abdominal aorta showing enlarged para-aortic nodes from involvement by seminoma.

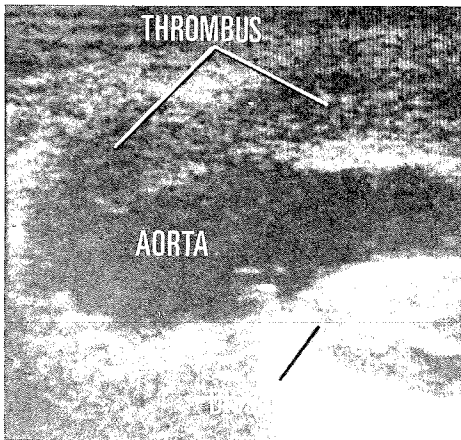


Fig. 11 Longitudinal scan showing aneurysm of the abdominal aorta with associated dissection and thrombus.

TERATODERMOID TUMOUR

This was seen in a young girl who complained of an epigastric mass. Apart from this she was asymptomatic. Ultrasound showed a cystic mass containing areas of calcification and closely adherent to the pancreatic tail, shown in Fig. 13.

OVARIAN AND UTERINE MASSES

Apart from the normal pregnancy cases referred for placental scans and biparietal diameter measurements, we come across such cases as molar pregnancies (Fig.14), unsuspected multiple pregnancies, ovarian cysts and uterine tumours. All these lesions are easily picked up on ultrasound,

because they are more accessible and because of absence of interfering echoes by bowel gases. A full bladder is necessary so as to displace these structures more superficially and it also offers an added advantage of the bladder being used as an acoustic window through which the ultrasound passes uninterrupted.

CONCLUSION

The range of cases that I have shown as detected by ultrasound is by no means complete. Like any other speciality, the accuracy in ultrasound diagnosis can only come with experience, and in this respect I must thank my other clinical colleagues for referring the cases and giving me the feedback which is very necessary to a diagnostician.

It is hoped that ultrasound, combined with the other imaging techniques of Computerized Tomography and Radioisotope Scans, will in future be available to most, if not all, major diagnostic centres.

I do not think conventional radiography will be totally displaced with the availability of the above facilities. But used in combination, I have no doubt that our basic aim, which is to get as near to the diagnosis as possible, will be realised in a more systematic and economical manner - both in terms of time and money, than has been the case without these sophisticated but very necessary equipment.

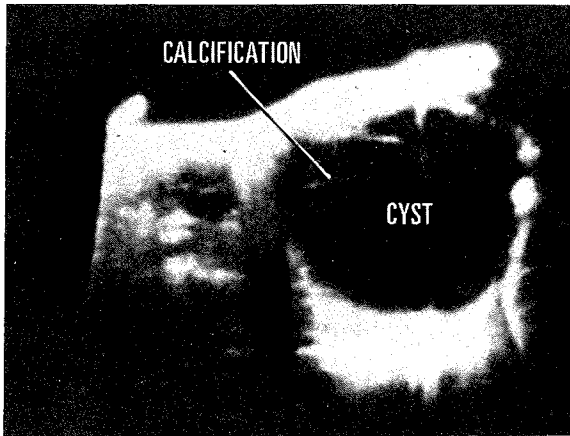


Fig. 13 Longitudinal scan across a dermoid cyst containing areas of calcification.

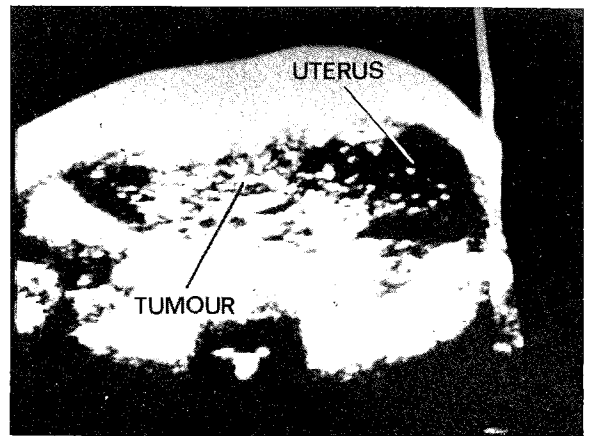


Fig. 14 Longitudinal scan across a uterus showing the typical "snow-storm" appearance of choriocarcinoma.

ACKNOWLEDGEMENTS

I would like to thank Cik Ramizah bte Che Rose for typing out the manuscripts, and Encik Alias bin

Manaf of the Medical Illustration Department, UKM, for preparing the prints.