

# TWO DIMENSIONAL ECHOCARDIOGRAPHY — A NEW TECHNIQUE IN CLINICAL PRACTICE

M.A.SIDEK NONTAK

## INTRODUCTION

With the advent of 2 dimensional echocardiography (2D echo), non-invasive cardiac diagnosis has been made more refined and reliable, especially when combined with the M mode echocardiographic presentation of the heart. For the last decade M mode echocardiography (M mode echo) has been the mainstay of non-invasive cardiac diagnosis, but M mode echo presents certain limitations, namely it shows only an ice-pick view of the heart and many structures such as the pulmonary valve, and tricuspid valve and the interatria septa are difficult to see. Other limitations include seeing the heart in an unfamiliar anatomy, although this can be overcome with training. On the other hand 2D echo offers an anatomy of the heart that is more familiar to the practising cardiologist and the greater visual impact of the heart's image makes diagnosis and measurements of certain parameters of the heart reliable and easier than M mode echo. It has therefore been the opinion of many cardiologists that 2D echo is superior to the conventional M mode echo, though the two methods should be viewed as complimentary to each other (Kotler *et al*, 1980). 2D echo operates on the same principle as M mode echo, but the sound beams are made to travel back and forth through an angle ranging from 30° to 80° depending on the machines available. The returning sound waves are picked up by the transducer and shows the heart in real time two dimensional images. It is not the purpose of this paper to present the technical details of ultrasound machines involved which are amply given in the literature, and to which some references are given here (Bom *et al*, 1973; von Ramm and Thurstone, 1976).

## METHOD

The patient is positioned and prepared as for an M mode study, with the electrocardiographic leads on and patient's identification data properly made. A generous amount of coupling gel is necessary to reduce artifactual shadows. The transducer is best held like a javelin with the edges of the little finger and palm of the hand level with the transducer face. The pressure applied and the position could then be easily controlled, thus preventing excessive pressure on the chest wall and slipping of the transducer to other positions.

The first views to be obtained are the parasternal views. The transducer is held perpendicular to the chest wall in the third or fourth leg parasternal intercostal space, the scan plane being aligned with the cardiac long axis. The long axis is the axis that transverses the heart from the aorta to the apex and any view parallel to this is the parasternal long axis view. Angling of the transducer towards the aorta and the apex should be made in order that scan plan shifts to cover most of the long axis, from ascending aorta to the apex. This view should show the anterior and posterior leaflets of the mitral valve in the centre of the scanning field. By image orientation standards (Henry *et al*, 1980) the aorta is seen to the right of the operator, and the apex to the left. From top to bottom, the chest wall shadows, the right ventricular cavity, the interventricular septum, the left ventricular cavity, the posterior left ventricular wall and the pericardium are seen in that order, as illustrated in Fig. 1a & b.

The transducer is then rotated 90 degrees to obtain the parasternal short axis view. The scan plane should be at the level of the mitral valve and show the mitral valve opening and closing like a fish mouth in the centre of the image (Fig.2). Tilting the transducer upwards towards the right shoulder shows the aorta, the right and left atria and the

---

M.A. Sidek Nontak, MB, AM, MRCPI, MRCP,  
Associate Professor  
Department of Medicine,  
University of Malaysia,  
Kuala Lumpur, Malaysia.

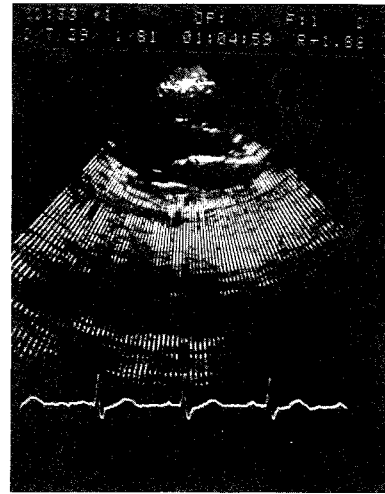
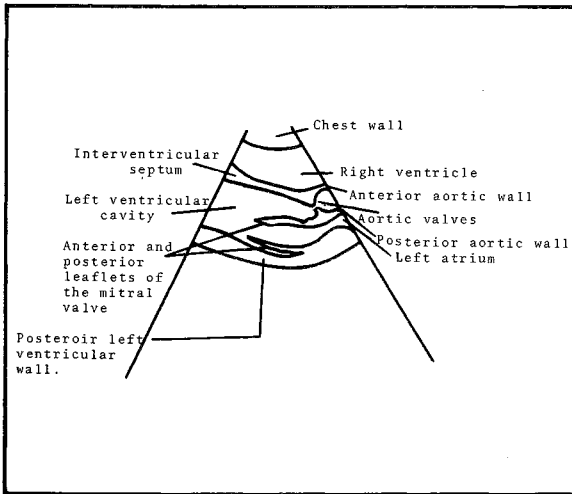


Fig. 1a & b: Parasternal long axis view of the heart.

interatrial septum. With slight counterclockwise rotation, the tricuspid valve, right ventricular outflow tract, pulmonary valve and main pulmonary artery are visualised. Tilting towards the apex moves the scan plane down to the level of the papillary muscles and the apex of the heart.

and left ventricle, the interventricular septum, the tricuspid and mitral valve, the right and left atrium with the interatrial septum in between. In order to obtain the apical long axis view, counterclockwise rotation of the transducer is made. This view gives a better image of the apical regions of the left ventricle.

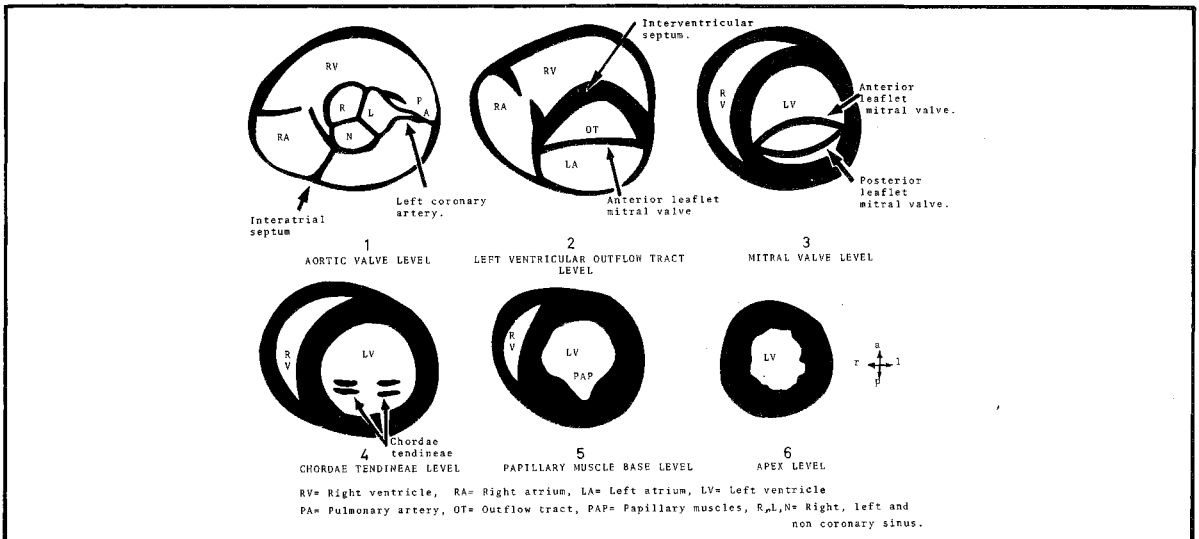


Fig. 2. Short axis views

The next view to be obtained is the apical four chamber view. The subject is turned well to the left and the position of the apex beat determined. The transducer is placed over the apex, with the scan plane parallel to the sternum. The view obtained is the apical four chamber view and shows the right

Two other useful views are from the suprasternal and subcostal approach. The neck must be extended fully by placing a pillow behind it in the suprasternal view. The transducer is placed in the suprasternal notch with its axis directed towards the mitral valve and the plane of the scan aligned to the

aortic arch, roughly perpendicular to the chest wall. This view will show the arch of the aorta, the main branches can be seen clearly at times, coming off the aorta. For the subcostal view place the subject supine preferably with a pillow behind the back so as to create a gentle arch forwards. The transducer is positioned below the costal margin and its axis directed towards the left ventricle. A four chamber view is obtained with the scan plane parallel to the sternum. Proper rotation will give the short axis view. With the axis to the mid of the thoracic spine and with more medial angulation, the hepatic veins, inferior vena cavae and right atrium can be viewed.

Utilising these views properly allows good 2 dimensional visualisation of the heart and diagnosis can be rapidly made, especially if M mode echo is used simultaneously to give a combined effect. 2 dimensional echocardiography is useful in most cardiac diagnosis eg. rheumatic and valvular heart diseases, ischaemic heart diseases, cardiomyopathies, intracardiac tumours, infective endocarditis, pericardial diseases or congenital heart diseases (Kotler *et al*, 1980).

## RHEUMATIC AND VALVULAR HEART DISEASES

2D echo could be used to assess valvular defects, most useful of which is for mitral stenosis. The value of M mode echo is well established in making a diagnosis of mitral stenosis and differentiating it from other causes of a mid diastolic apical murmur such as that due to atrial myxoma. However M mode echo cannot reliably estimate the severity of mitral stenosis when compared with catheterization and surgical findings. However more investigators now feel that 2D echo can reliably estimate the severity of the mitral stenosis, obviating the need for invasive studies (Martin *et al*, 1979). In 2D echo, the stenosed valve can be seen to open with difficulty giving a slit-like opening and the valve shadows are denser.

Mitral incompetence however is more difficult to define, but some causes of mitral incompetence murmur such as prolapsed mitral valve, ruptured chordae tendinae, cleft mitral valve could be easily identified. In mitral prolapse one can discern the valves moving inwards towards the left atrium

during systole, and in ruptured chordae the valve leaflets affected can be seen to show a jagged recoil indicating its lack of proper support to the chordae (Fig. 3)

The M mode appearance of aortic stenosis is shown as thickened echoes and lack of separation of the aortic cusps. With 2D echo, the thickened valves can be seen in the parasternal long axis view and its lack of separation seen in the short axis view, where the valves appear like a letter Y or the inverted "Mercedes Benz sign", so-called because it resembles the "Mercedes Benz" logo. However quantitative analysis of the degree of stenosis is not as reliable as for mitral stenosis (DeMaria *et al*, 1978). For aortic incompetence, evidence of hyperdynamic movements of the heart can be observed, and specific causes of aortic regurgitation such as infective endocarditis or prolapse identified.

The pulmonary and the tricuspid valve can be more easily identified with 2D echo than M mode echo as those with practical knowledge of echocardiography can testify. Lesions of the pulmonary and tricuspid valves such as valvular stenosis can be seen as showing very dense echoes coming from those regions.

## ISCHAEMIC HEART DISEASE

The value of M mode echo in Ishaemic heart disease (I.H.D.) is limited by its inability to see the heart as a whole. In I.H.D. there can be regional dysfunction, with some areas functioning much better than with others. M mode echo picks and sees only one view, thus leaving out the others. 2D echo is better as regional dysfunction can be identified. Thus a grossly dilated and hypokinetic heart can be identified at once and aneurysms at appropriate places viewed (Fig. 4).

Attempts have also been made to quantify myocardial infarction and its effect on the left ventricle (Rogers *et al*, 1978) and so far reports have been very encouraging. Reports have also been made of the ability to see main stem disease of the left coronary through 2D echo, though the other peripheral coronary arteries cannot be discerned (Weyman *et al*, 1975).

There is growing evidence that 2D echo can be useful in identifying IHD, especially when used in

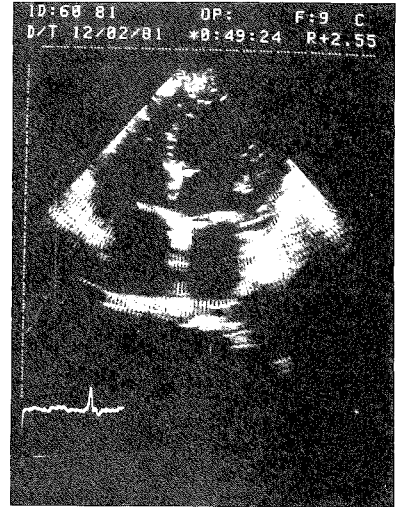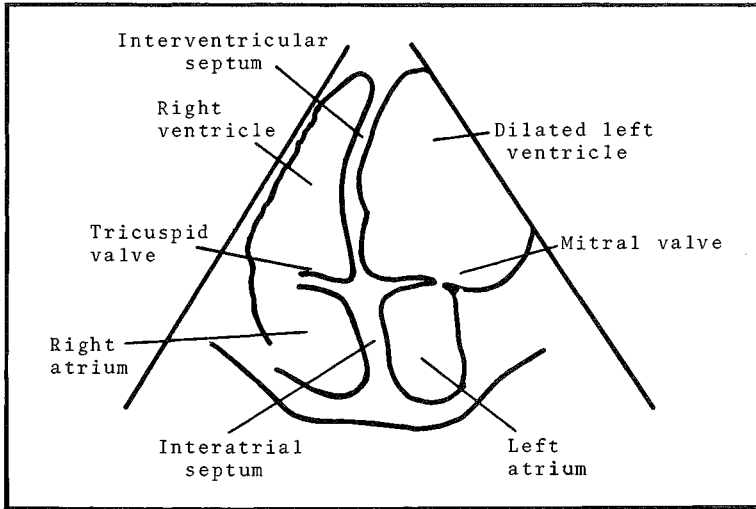


Fig. 3a & b: Apical 4-chamber view of the heart showing a grossly dilated left ventricle.

conjunction with exercise testing i.e. exercise echocardiography (Wann, *et al*, 1979) or with radioactive scanning of the heart.

### CARDIOMYOPATHIES

2D echo is useful in picking up and quantifying the hypertrophic cardiomyopathies, both before operation and after operation, to assess the effects of surgery on the hypertrophied septum. Although M mode echo can reliably make a diagnosis of hypertrophic cardiomyopathy from the grossly hypertrophied interventricular septum, the anterior systolic motion of the anterior mitral valve leaflet and other features, one can see the defects to a much greater extent with 2D echo. Confirmation of the diagnosis is thus rapidly made and is therefore useful as a tool to screen relatives of the patient.

For the congestive cardiomyopathies, the image seen is one of global enlargement and hypokinesia, but needs to be differentiated from other causes of enlargement and hypokinesia such as I.H.D. which can be easily done from history, clinical features, electrocardiogram, exercise testing or if need be by coronary angiograms. However 2D echo can reliably estimate the effects of treatment on certain congestive cardiomyopathies such as alcoholic cardiomyopathy where improvement may be seen with alcoholic abstinence.

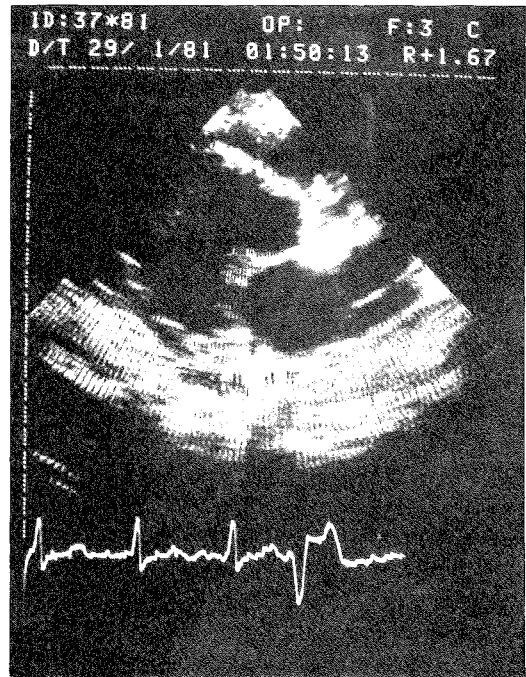


Fig. 4: Parasternal long axis view of the heart showing flail mitral valve (for orientation see Fig. 1). All photographs are produced many times from original to the text and the quality is thus compromised.

### INTRACARDIAC TUMOURS

M mode echocardiography is a reliable method of diagnosing intracardiac masses such as atrial or

ventricular myxomas. 2D echo offers better definition of the shape, size and site of the tumour and can be used repeatedly to assess the effects of treatment. Echocardiography offers better advantage than even angiography in assessing intracardiac tumours as introduction of catheters and contrast media may dislodge the tumour particles and cause embolism.

### INFECTIVE ENDOCARDITIS

Infective endocarditis may result in large masses on or around the valve leaflets which can be detected by M mode echo as shaggy lines along valvular openings and closing. However M mode diagnosis is not very reliable as only the bigger masses can be picked up and the location of the masses can influence the intensity and consistency of the shadows. 2D echo however is better than M mode as they show the masses, their site and size, and the effects they have on the valvular apparatus. Once recognized, the effective mode of treatment is surgical removal of the valve involved as very rarely these vegetations are cured by medical treatment alone. However recognition of vegetative masses by echocardiography is not foolproof and more investigators are stressing the importance of reducing artifactual shadows to improve specificity. Moreover absence of vegetative masses on echocardiography cannot rule out infective endocarditis.

### PERICARDIAL LESIONS

Pericardial effusions could be reliably picked up by M mode echo and can be recognized as an echo free area in between the epicardium and the pericardium. In 2D echo the heart can be seen contracting vigorously surrounded by an echo free surface in between the epicardium and the pericardium. Although exact estimation of the size of the effusion could be difficult an approximate volume could still be derived from the 2D echo. Furthermore 2D images can pick out echo free areas that could have been missed by M mode echo.

Other pericardial lesions such as chronic pericarditis can be seen as echodense areas surrounding the heart.

### CONGENITAL HEART DISEASES

Atrial septal defects can be reliably shown by 2D

echo in the apical 4 chamber view and the short axis parasternal views. These are seen as echo free areas or 'defects' within the continuity of the interatrial septum and for better specificity this incontinuity should be recorded in more than one view. Small defects could still be missed.

For ventricular septal defect, 2D echo could pick up only the larger ones at the membranous part as muscular defects are difficult to visualise.

2D echo is an important method of recognizing Ebstein anomaly where one of the leaflets of the tricuspid valve is lower in position than normally and present a characteristic picture on the 2D echo. Fallots tetralogy showing the overriding aorta can be seen as well as transposition of the great vessels in which the aorta is anterior to the pulmonary artery.

Using contrast echocardiography in which a bolus of saline or other contrast media is injected rapidly into a peripheral vein, the contrast can be picked up by the echoes as they appear as tiny bubbles in the heart's chambers. By this technique, one is able to see the bubbles moving from the right to the left side of the heart in Right to Left shunts. Furthermore in atrial septal defects one can see right to left movement of the contrast in a sizeable number of defects as some blood passes from right to left even though the major shunt is a left to right shunt. However in others a contrast free area occurs in the right atrium due to blood flowing from left to right creating a negative contrast shadow. This technique has been recently described by Weyman *et al*, 1979.

### CONCLUSION

The usefulness of 2D echocardiography practically covers all aspects of clinical cardiology. It is superior to M mode echo per se as it allows a 2 dimensional imaging of the heart showing it as an anatomical structure which the physician can readily comprehend. Furthermore these images are reproducible and can be repeated many times with minimal discomfort to the patient. In certain instances diagnosis and quantification of abnormalities could do away with more expensive and risky investigations. This especially applies to mitral stenosis and mitral restenosis after a successful vulvotomy, to intracardiac tumours,

pericardial effusions and certain cardiomyopathies and congenital heart diseases. With intensive research presently going on to produce more sophisticated equipment giving better resolution of images, this list could expand, making 2D echo an exciting field of development. The usefulness of 2D is better enhanced if the cardiologist is aware of its pitfalls and should be able to use minimal gain for imaging so as not to introduce artifacts. Some machines furthermore have built in artifacts and these should not be confused with that of lesions of the heart. The 2D echo examination in experienced hands is a valuable adjunct to the diagnosis of the cardiac patient.

#### ACKNOWLEDGEMENTS

I would like to thank Dr. C.J. Roger, Consultant Cardiologist, Monklands General Hospital, Glasgow for kindly allowing me to study echocardiographically patients (some of whose pictures are shown in this paper) under her care and Miss S.K. Poh for secretarial assistance.

#### REFERENCES

- Bom, N., Lancee, C.T., van Zwieten G., *et al*, (1973) Multiscan Echocardiography 1. Technical description, *Circulation*, 48, 1066-1074.
- DeMaria, A.N., Joye, J.A., Bommer, W., *et al*, (1978) Sensitivity and specificity of cross sectional echocardiography in the diagnosis and quantification of valvular aortic stenosis (abstr.), *Circulation*, 57, 58, Suppl II:II-907.
- Henry, W.L., DeMaria, A.N., Gramiak, R., *et al*, (1980) Report of the American Society of Echocardiography Committee on nomenclature and standards in two-dimensional echocardiography, *Circulation*, 62, 212-217.
- Kotler, M.N., Mintz, G.S., Segal, B.L., *et al*, (1980) Clinical uses of two dimensional echocardiography, *Am. J. Cardiol.*, 45, 1061-1082.
- Martin, R.P. Rakowski, H. Kleiman, J.H. *et al.*, (1979) Reliability and reproducibility of two-dimensional echocardiographic measurement of the stenotic mitral valve orifice area, *Am. J. Cardiol.*, 43, 560 - 568.
- Rogers, E.W., Weyman, A.E., Feigenbaum, H., *et al.*, (1978) Predicting survival after myocardial infarction by cross sectional echo (abstr.) *Circulation*, 57, 58 Suppl II:II-907.
- Von Ramm, O.T. and Thurstone, F.L., (1976) Cardiac imaging using a phased - array ultrasound system 1. System design, *Circulation*, 53, 258-262.
- Wann, L.S., Faris, J.V., Childress, R.H., *et al*, (1979) Exercise cross-sectional echocardiography in ischaemic heart disease, *Circulation*, 60, 1300-1308.
- Weyman, A.E., Feigenbaum, H., Dillon, J.C., *et al*, (1975). Non invasive visualisation of the left main coronary artery by cross sectional echocardiography, *Circulation*, 54, 169-174.
- Weyman, A.E., Wann, L.D., Caldwell, R.L., *et al*, (1979) Negative contrast echocardiography: a new technique for detecting left to right shunts, *Circulation*, 59, 498-505.