

EXTENSIVE CRESCENT FORMATION IN IDIOPATHIC MEMBRANOUS GLOMERULONEPHRITIS - A CASE REPORT

CHEONG I.K.S.

CHONG S.M.

N.SINGH

ABU BAKAR SULEIMAN

SUMMARY

We report this 21 years old Indian male with the nephrotic syndrome due to membranous nephropathy who later developed numerous epithelial crescents leading to a rapid loss of renal function. The pathogenesis of the crescentic transformation in this type of glomerulopathy is discussed.

INTRODUCTION

Idiopathic membranous glomerulonephropathy is a well defined clinical and pathological entity (Gluck *et al*, 1973). It is postulated to be an immune-complex disease. There seems to be some variation in the life expectancy in this group of patients, nonetheless most agree that slow progression to renal failure is usual. Evolution of membranous nephropathy to a rapidly progressive crescentic glomerulonephritis is extremely rare. Isolated cases have been documented by Klassen *et al*, (1974), Nicholson *et al* (1975) and Moorthy *et al* (1976).

Cheong I.K.S. MBBS(Mal) MRCP(UK)
Department of Medicine,
Universiti Kebangsaan Malaysia,
Kuala Lumpur.

Chong S.M. MBBS(Mal) DCP(London)
Department of Pathology,
Universiti Kebangsaan Malaysia,
Kuala Lumpur.

N. Singh MBBS (Mysore)
Department of Nephrology,
General Hospital, Kuala Lumpur.

Abu Bakar Suleiman M.Med.(S'pore)FRACP
Consultant Nephrologist,
General Hospital, Kuala Lumpur.

We report here such a case with what initially appeared to be a typical membranous nephropathy, pursued a rather rapid course to renal failure, with development of numerous crescents.

CASE REPORT

A 21 years old Indian male was referred with the nephrotic syndrome. He presented 3 years previously with facial and ankle swelling. Despite treatment with prednisolone and cyclophosphamide for one year his proteinuria and oedema persisted. He did not give any history of haematuria, oliguria, recurrent sore-throat, skin rashes, arthritis, alopecia or taking of drugs. He did not receive any treatment for hypertension. There was no family history of diabetes or renal diseases. He worked in a factory packaging plastic bottles prior to his illness. He denies being exposed to any toxic substances. Three months prior to his referral his ankle swelling became worse.

On examination his general condition was satisfactory. He was normotensive (130/80 mmHg) and except for oedema of his ankles there were no other significant findings. Investigations showed a haemoglobin concentration of 13.0 g/dl; total white cell count of $7.8 \times 10^9/L$ (neutrophil 64%, lymphocyte 35%, eosinophil 1%); serum cholestrol of 11.1 umol/L; serum protein of 44g/L (albumin 28g/L); serum creatinine of 150 umol/L. His 24 hours urinary protein excretion was 15.6g. Urinary microscopy showed occasional granular casts. There were no red blood cells. Test for syphilis, HBsAg, LE cells and anti-nuclear antibodies were negative. Serum complement levels were not available. His chest x-ray was normal.

The first renal biopsy specimen (Fig. 1) examined by light microscopy contained only 4 glomeruli of which 1 was sclerosed. The remaining 3 glomeruli revealed what appeared to be typical membranous nephropathy. The glomeruli were normocellular with no significant increase in mesangial matrix. The capillary loops were uniformly thickened with numerous epimembranous 'spikes' on silver stain, the over-all appearance corresponding to a stage II membranous lesion in the system of Ehrenreich and Churg (1968). The surrounding parenchyma was generally well preserved with small foci of tubular atrophy and lymphocytic interstitial infiltrates.

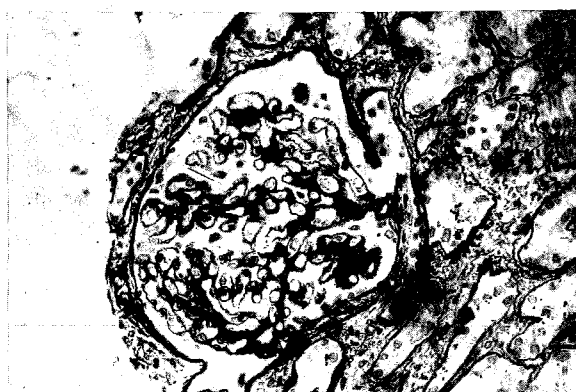

Fig. 1 A glomerulus from the first biopsy showing moderately advanced membranous nephropathy. It is normocellular with uniformly thickened capillary walls showing typical epi-membranous 'spikes' (arrow). Silver methanamine x 400.

Following discharge from hospital, aldomet was prescribed when hypertension developed and frusemide was given for oedema. His renal function deteriorated rapidly over the next 6 months even though he maintained a normal urine output. There was no evidence of a recent infection. His serum creatinine was 1220 $\mu\text{mol/L}$. His serum C_3 was 60 mg/dl and C_4 was 46.9 mg/dl. Anti-glomerular basement membrane antibodies (anti-GBM antibodies) could not be measured.

A second biopsy was performed. The specimen contained 9 glomeruli of which 2 were sclerosed. The viable glomeruli showed membranous changes similar to the first biopsy except that there were more marked thickening of the capillary walls and segmental proliferation with matrical increase were

present in some of the glomerular capillary tufts. In addition fresh cellular epithelial crescents were seen in 4 glomeruli obliterating the Bowman's space (Fig. 2). Fibrin was not demonstrated. The interstitium showed focal areas of fibrosis and tubular atrophy with lymphocytic infiltrates. No eosinophils were seen. The vessels had moderately severe hypertensive changes. Immunofluorescence revealed intense staining for IgG and C_3 along the capillary wall in a coarse granular pattern.

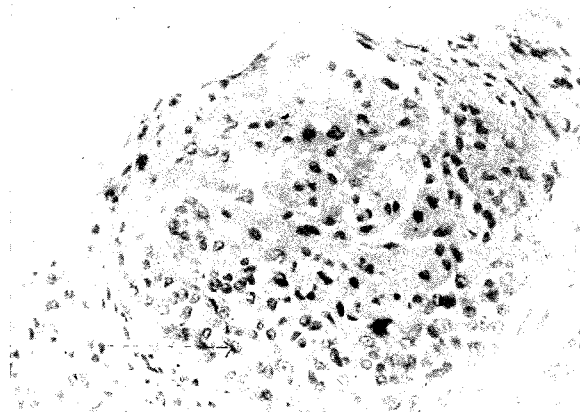


Fig. 2 A glomerulus from the second biopsy showing moderately advanced membranous nephropathy. There is uniform capillary wall thickening, mild segmented proliferation and matrical increase. The Bowman's space is filled with a large epithelial crescent (arrow). H & E x 400.

The patient was treated with intravenous methylprednisolone. Unfortunately his renal function did not improve. He is presently on recurrent haemodialysis while awaiting renal transplantation.

COMMENTS

Idiopathic membranous nephropathy is the commonest cause of nephrotic syndrome in adults as reported by Heptinstall (1974). Although spontaneous remission can occur, slow progression to terminal renal failure is the usual course which is often due to a combination of glomerulosclerosis and arteriosclerosis. At times superimposed renal vein thrombosis may be responsible. An occasional crescent is commonly seen in the kidney of end-stage membranous nephropathy but extensive crescent formation followed by a rapidly progressive clinical course as is seen in this patient is rare.

The association of extensive crescent formation and idiopathic membranous nephropathy is unknown. It may represent an exacerbation of the primary glomerulopathy or the malignant end of the spectrum of membranous nephropathy. Alternatively it may have been superimposed on an underlying quiescent glomerular lesion by an additional insult such as infection or malignancies (Whitworth *et al.*, 1976). The presence of mild proliferation in the second biopsy, as emphasized by Cameron (1979), should raise the possibility of underlying systemic lupus erythematoses although there was no evidence both clinically and serologically in this patient.

The pathogenesis of crescentic transformation in idiopathic membranous nephropathy is unclear. It is possible that damage to the basement membrane by immune-complex deposition may render the glomerulus more susceptible to additional injuries by other agents. Fibrin may easily leak into the Bowman's space thus stimulating epithelial crescent formation. Alternatively Klassen *et al.*, (1974) proposed that the deposits may initiate release of normal or altered endogenous basement membrane material into circulation thus leading to formation of anti-GBM antibodies and subsequent development of anti-GBM glomerulonephritis which is characterised by extensive crescent formation. Anti-GBM antibodies have been detected in such cases by Klassen *et al.* (1974) and Moorthy *et al.* (1976) but this is not universal (Nicholson *et al.*, (1975). Hill *et al.* (1978) reported the recurrence of a similar glomerulopathy in a transplanted kidney suggesting that crescents are an integral part of the basic disease process.

REFERENCES

- Cameron, J.S. (1979) Pathogenesis of membranous nephropathy, *Kidney Int.* 15, 88.
- Ehrenreich, T. and Churg, J. (1968) Pathology of membranous nephropathy, *Pathol. Annu.*, 3, 145.
- Gluck, M.C., Gallo, G., Lowenstein J. *et al.*, (1973) Membranous glomerulonephritis. Evolution of clinical and pathological features, *Ann. intern. med.* 78, 1.
- Heptinstall, R.H. (1974) Pathology of the kidney, 2nd edition, Boston, Little Brown. pg 393.
- Hill, G.S., Robertson, T., Grossman, R. *et al.* (1978) An unusual variant of membranous nephropathy with abundant crescent formation and recurrence in the transplanted kidney, *Clin. Nephrol.* 10, 114.
- Klassen, J., Elwood, C., Grossberg, A.L. (1974) Evolution of membranous nephropathy into anti-glomerular basement membrane glomerulonephritis, *New Engl. J. Med.* 290, 1340.
- Moorthy, A.V. Zimmerman, S.W., Burkholder, P.M. *et al.* (1976) Association of crescentic glomerulonephritis with membranous glomerulonephropathy: a report of three cases, *Clin. Nephrol.* 6, 319.
- Nicholson, G.D., Amin, U.F., Alleyne, G.A.O. (1975) Membranous glomerulonephropathy with crescents, *Clin. Nephrol.* 5, 198.
- Whitworth, J.A., Morel-Maroger, L., Mignon, F. *et al.* (1976) The significance of extracapillary proliferation: clinicopathological review of 60 patients, *Nephron* 16, 1.