

THE CURRENT MANAGEMENT OF EXTERNAL FISTULAS

S. HARI RAJAH

M. BALASEGARAM

INTRODUCTION

It was demonstrated (Edmunds, *et al.*, 1960, Sheldon, *et al.*, 1971, Monod Broca, 1977, Blackett, *et al.* 1978) that fistulas arising from the gastro intestinal tract are associated with prolonged morbidity and a high mortality. The mortality in 1960 was in the range of 60%. With the introduction of parenteral nutrition on a long term basis (Dudrek 1968) and improvements in the techniques of local management (Gross and Irving, 1977) there has been a marked improvement in results, the mortality being reduced to 10 - 20 %.

In this paper, we take the opportunity to describe the management of 18 cases of external fistulas. Our definition of an external fistula is the external drainage of gastric, enteric, biliary, pancreatic or urinary contents for 48 hours or more.

We believe that the problems associated with the treatment of external fistulas are very much similar to those associated with the management of entero cutaneous fistulas.

MATERIAL AND METHODS

During the period April 1978 to February 1979 a total of 18 cases of external fistulas were

Dr. S. Hari Rajah BSc. M.B.B.S., F.R.A.C.S.
Surgeon Unit II,
General Hospital,
Penang.

Prof. M. Balasegaram, M.B., A.M., F.R.C.S.,
F.R.C.S.E., F.R.A.C.S., F.A.C.S., F.I.C.S.
Head of Dept. of Surgery,
General Hospital,
Kuala Lumpur.

treated in the Department of Surgery, General Hospital, Kuala Lumpur. These included 4 cases of established external fistulas referred from various states of Malaysia. 16 cases were treated conservatively. They consisted of 12 males and 4 females their age ranging from 15 to 80 yrs. They included 2 of the referred cases and 14 cases of external fistulas that developed post-operatively between 2 to 18 days of surgery in our department. Table I shows the type of operation performed and the site of fistula. In Table II we have listed the age, sex, type of external fistula, number of fistulas, cause, time of diagnosis and day of the closure following conservative treatment.

DIAGNOSIS

Our definition was followed as the criteria for diagnosis. Fistulograms from external opening were helpful in demarking abscess cavities. Barium contrast studies pointed the internal opening. It is our experience that the combination of these two investigations are best in a difficult situation. Once the diagnosis was established, the localisation and causative factors were ascertained, all patients were managed on the following regime.

MANAGEMENT

1. Correction of Fluid and Electrolytes.

The high output from gastro-intestinal fistulas caused fluid loss resulting in dehydration while the high electrolyte contents of the biliary and pancreatic fistulas caused electrolyte depletion. An aggressive policy of resuscitation is followed in our department and both fluid loss and electrolyte depletion is corrected. This was done with balanced electrolyte solution (Hartmanns),

TABLE I
THE TYPE OF OPERATION AND SITE OF EXTERNAL
FISTULA AS SEEN IN SURGICAL UNIT I GENERAL
HOSPITAL, KUALA LUMPUR.

	Type of Operation	Site of Fistula	Number
A. Surgery involving oesophagus	Stricture oesophagus — colonic interposition	Cervical anastomosis	1
B. Surgery on stomach, small intestine	Bilroth II gastrectomy	Duodenal stump end fistula	2
	Lysis of adhesions — liver abscess	Lateral duodenal fistula	1
	Typhoid perforation — suturing	Ileum	1
	Crohns disease — laparotomy	Ileum	1
C. Surgery involving appendix, colon, rectum.	Acute appendicitis — appendicectomy	Caecum	1
	Perforated appendicitis — appendicectomy	Caecum	1
	Appendicular mass — appendicectomy	Caecum	1
	(R) Hemicolectomy	Anastomosis	1
	anterior resection	Anastomosis	1
D. Surgery not involving the gut	Traumatic liver rupture — simple suturing	(L) lobe liver	1
	Traumatic liver rupture	(R) lobe liver	1
	Cholecystectomy — simple suturing	Gall bladder fossa	2
	Traumatic pancreatic rupture — distal pancreatectomy	Remnant pancreas	2
	perinephric abscess — incision and drainage	Ascending Colon	1
Total No. of fistulas			18

Darrows solution, normal saline and 5% dextrose with supplements of potassium when indicated. The blood urea and serum electrolytes was monitored daily.

II. Local Management

Local management was carried out in the following sequence:

(i) Antiseptic cleansing of fistula

- (ii) Gauze drying of skin
- (iii) Application of stoma adhesive wafers or wafers with flanges as indicated.
- (iv) Application of collection bags over the stoma adhesive for the accurate measurement of fluid loss.
- (v) Skin excoriations was treated with orohesive powder followed by the application of stoma adhesive wafers.



Fig. 1. Application of a large piece of wafer surrounding the entero-cutaneous fistula to prevent skin excoriation.

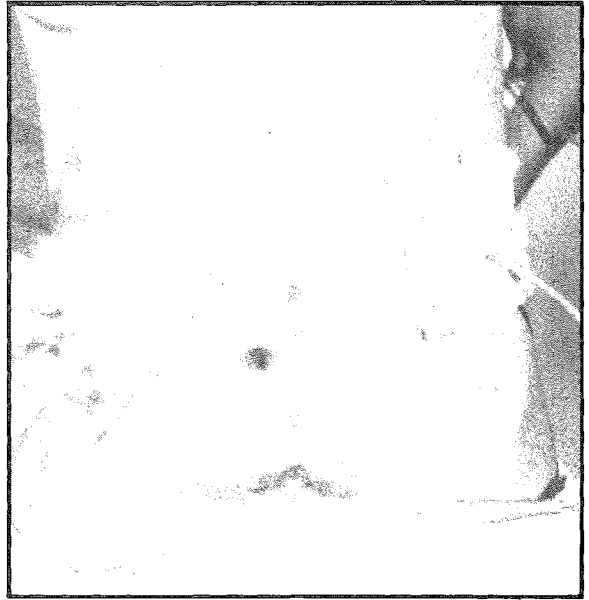

Fig. 2. Application of a wafer and stoma-adhesive / bag for collection of the discharging fluid from an entero-cutaneous fistula.

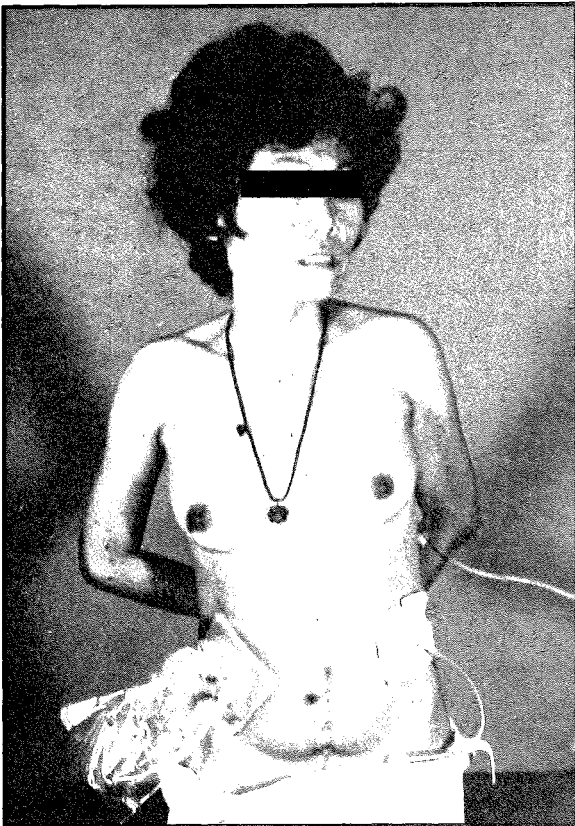

Fig. 3. The use of a stoma-adhesive and bag for collection of discharging fluid from an entero-cutaneous fistula.

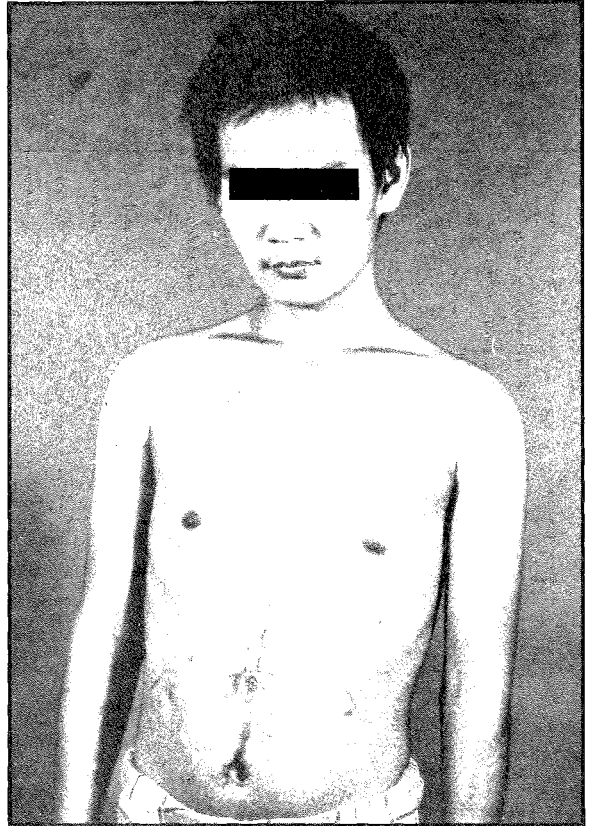


Fig. 4. Healing pancreatic fistula wound following regular use of wafer / stoma-adhesive appliance.

TABLE II
FISTULA CASES TREATED MEDICALLY

Patient	Age	Sex	Type of Fistula	No. Fistula	Cause of Fistula	Time of Diagnosis	Days for Closure
1.	46	Male	Lateral duodenal	1	Lysis of adhesions	10 P.O.D	35
2.	51	Male	Duodenal stump	1	Carcinoma stomach	11 P.O.D	13
3.	57	Female	Duodenal stump	1	Carcinoma stomach	6 P.O.D.	23
4.	49	Male	Biliary	1	Cholelithiasis	3 P.O.D.	17
5.	30	Male	Biliary	1	Liver rupture, D.I.V.C.	2 P.O.D.	90
6.	17	Male	Pancreatic	1	Traumatic pancreatic rupture	5 P.O.D.	55
7.	36	Male	Entero cutaneous	3	Typhoid perforation ileum	10 P.O.D.	34
8.	39	Male	Faecal	1	Appendicular mass	9 P.O.D.	58
9.	15	Male	Faecal	1	Acute appendicitis	7 P.O.D.	17
10.	15	Male	Faecal	1	Perforated appendicitis	18 P.O.D.	52
11.	40	Male	Faecal	3	Carcinoma rectosigmoid	10 P.O.D.	27
12.	18	Male	Biliary	1	Traumatic laceration liver, tear in portal vein, laceration (L) hepatic artery	4 P.O.D.	Failed to close.
13.	25	Female	Faecal	1	Appendicular abscess	2 P.O.D.	Failed to close
14.	80	Male	Entero cutaneous	2	Carcinoma caecum	3 P.O.D.	Patient expired.
15.	25	Female	Pancreatic	2	Traumatic pancreatitis D.I.V.C	6 P.O.D.	Patient expired.
16.	65	Female	Biliary	1	Carcinoma gall bladder	5 P.O.D	Patient expired.

III. Treatment of Sepsis

All abscesses when present were drained. The pus was sent for culture and sensitivity. Based on previous organism isolates and hospital organism studies our rationale of antibiotic use was to combine an amnioglycoside, cephalosporidine and anti-anaerobic agent till we receive the culture and sensitivity report, when the most appropriate antibiotic is then continued.

IV. Parenteral Nutrition

All our patients were given parenteral nutrition varying from 2,500 - 3,500 calories

per day by way of subclavian vein catheter into the superior vena cava. This requirement was on the basis of height, weight and body surface area. The daily requirement of protein was calculated at 1 - 1.5gm per kg. body weight. Thirty per cent of the total calorie requirement was provided with glucose. As our patients had a central venous catheter this amount was provided by combination of 5%, 10% and 50% dextrose. The rest of the calorie requirement was given with 10% soya bean extract (Intralipid). Potassium supplements of 5 m.mols per gramme nitrogen was also given together with high doses of vitamins including vitamin K. Low dose insulin was given when there was spillage of glucose in urine.

V. Correction of anaemia and hypoprotein-aemia

Anaemia was corrected to a haemoglobin of 12 gm%. Patients with serum albumin below 3 gms% were given transfusions of 20 % human albumin solutions.

RESULTS

Eighteen patients with fistulas were treated in our department. Of these 16 cases were treated medically and 11 (61%) closed spontaneously between 13 - 90 days.

All the 3 cases of duodenal fistulas closed with medical treatment between 13 - 35 days. Only one of the 2 biliary fistulas following traumatic rupture liver closed spontaneously. This patient had septicaemia, disseminated intravascular coagulation and recovered after 90 days. The pancreatic fistula that developed following distal pancreatectomy for traumatic rupture healed in 55 days. One of the 2 cases of biliary fistula following cholecystectomy healed in 17 days. All the ileal, caecal and colonic fistulas treated medically healed spontaneously between 17 - 58 days. All our fistulas that healed with medical treatment closed by 58 days except for the biliary fistula following the right lobe of liver rupture mentioned above.

Four cases were treated surgically. These included 2 cases which were referred to us for surgery and 2 cases where medical treatment failed. All these fistulas closed successfully with the first operation. The first was an 18 year old male with prolonged biliary drainage following traumatic rupture of the liver, tear of the portal vein and rupture of the left branch of the hepatic artery. The clinical course suggested distal obstruction to bile flow. Based on this indication surgery was done and complete obstruction to the common bile duct was confirmed at laparotomy. Following left hepatic lobectomy and bilio enteric anastomosis the fistula closed.

The second patient was a 56 year old male with an entero-cutaneous fistula arising from the

ileum who was referred to us after total parenteral nutrition for 6 weeks had failed to close the fistula. A right hemicolectomy was done with the excision of the fistulous tract. This case was histologically diagnosed as a case of Crohn's disease. His post operative period was uneventful.

The third patient was a 26 year old male who was transferred to us with a fistula in the neck following colonic interposition surgery for corrosive stricture oesophagus.

The patient was fed through a Ryles tube passed beyond the failed anastomosis. He had 2 indications for surgery. There was an abscess cavity and mucocutaneous continuity of the fistula. The abscess was drained and excision of the fistula was done as a first stage. A plastic flap closure of the wound was done as a second stage.

The fourth case to be treated surgically was a 25 year old female who was referred to us with a faecal fistula in the right loin following an incision of a loin abscess. The fistula failed to close with medical treatment. At laparotomy a high retrocaecal appendix was found to be the cause. An appendicectomy and closure of the internal opening resulted in closure of the fistula.

Three of our cases expired during treatment. The first was an 80 year old male who presented with intestinal obstruction. At laparotomy a resectable growth of the caecum was found and an emergency right hemicolectomy was done. This patient was more than 65 years of age suffering from cancer. The fistula appeared on the 4th post operative day with complete breakdown of the wound. The site of the fistula was the ileum and daily output was more than 500ml.

The second case was a 25 year old female who was involved in a motor vehicle accident and was referred to us after 36 hours. On admission she was toxic and in shock. A laparotomy was done after resuscitation that showed traumatic pancreatitis. No resection was done. She developed disseminated intravascular coagulation and fistula formation and succumbed in spite of energetic treatment.

The last case was a 65 year old female who was admitted as a case of ascending cholangitis. Clinically she appeared as a case of empyema of gall bladder and the liver scan suggested micro-abscesses. A cholecystectomy was done but she developed post operative biliary discharge amounting to 400 - 500 ml of bile. She deteriorated in spite of our medical management. The histopathological report on the resected gall bladder showed the rare diagnosis of adeno carcinoma of gall bladder.

DISCUSSION

A total of 18 cases of external fistulas were treated in our department during a short period of 10 months. 15 cases were completely cured giving us a 84% total cure rate. This rates closely to that of 93% shown by (Dudrick, *et al* 1972) and 86% by (Kaminsky and Deitel 1975) but better than that of 60% demonstrated by (Blackett and Hall, 1978).

Three of our cases died giving us a mortality of 16%. The first of these had all the adverse prognostic factors as suggested by Monod-Broca, (1977). The delay in referring the case to us was a significant factor in the second case and disseminated intra vascular coagulation is associated with polytrauma and sepsis (Effeney, *et al* 1978). The last patient to expire during treatment presented with a rare condition of adeno carcinoma of gall bladder, besides suffering from gross sepsis and having 2 adverse prognostic factors.

We have had minimal side effects following parenteral nutrition. It is our experience that the best route for parenteral nutrition is the right subclavian catheter inserted blindly from below the mid clavicular point. All catheter insertions were done in the ward with absolute aseptic precautions and the puncture site sealed with an antiseptic dressing. Post insertion chest x-rays were done as routine to confirm catheter tip position before inaugurating parenteral nutrition. All parenteral nutritional solutions were carefully chosen from proprietary preparations rather than preparing them in our pharmacy. It is our experience that Intralipid (10% soya bean extract) is the most suitable fat preparation for our

patients. Although the calorie value was much less than the 20% solution, it never produced lipaemia and none of our patients had any pyrexial reactions. We used Vamin-Glucose (synthetic L amino acid solution) to provide the daily requirement of nitrogen. Although it is not superior to protein hydrolysate solution we found the electrolyte content adequate for our patients. Glucose is without doubt the best carbohydrate for parenteral nutrition (Holmes, 1977).

Our patients were monitored for spillage of sugar in urine and low dose of insulin was given if the urine sugar persisted for more than 48 hours. Local treatments has advanced through biological membranes, postural drainage, sump drainage, polythene stomal bags, karaya gum to stoma adhesive (SQUIBB) (Gelatin, pectin, sod. carboxy methylcellulose and poly-isobutylene). We find stoma adhesive both the wafer and powder (orohesive) most suitable for our patients. It was easy to apply even on obese abdominal contours with the large sheets useful in multiple fistulae. Skin excoriations healed well with the powder form. Collection bags were easily applied over the stoma adhesive for collection and correct monitoring of fistula drainage.

The indication for surgery in external fistulas is the presence of abscess cavity, evidence of distal obstruction, mucocutaneous continuity of the fistula and failure of total parenteral nutrition for a duration of six weeks. Only 4 cases were treated surgically and all four fistulas healed following surgery.

REFERENCES

- Blackett, R.L. and Hall, G.L. (1978) Post operative external small bowel fistulas. A study of consecutive cases of patients treated with intravenous hyperalimentation. *Br. J. Surg.* 65, 775-778.
- Dudrick, S.J., Wilmore, D.W., Vars, H.M. and Rhoads, J.E. (1968) Long term total parenteral nutrition with growth development and positive nitrogen balance. *Surg.* 64, 134-142.
- Dudrick, S.J., Macfadyen Jr, B.V., Van Buren, C.T. et al (1972) Parenteral Hyperalimentation - Metabolic problems and solutions. *Ann. Surg.* 176, 259-264.

- Edmunds Jr. H., Williams, G.M. and Welch, C.E. (1960) External fistulas arising from the gastro intestinal tract. *Ann. Surg.* 152, 445-571.
- Effeney, D.J., Blaisdell, F.W., McIntyre, K.E. and Graziano, C.J. (1978) The relationship between sepsis and disseminated intravascular coagulation. *J. Trauma* 18, 689-695.
- Gross, E. and Irving, M. (1977). Protection of skin around intestinal fistulas, *Br. J. Surg.* 64, 258-263.
- Hismal, H.S., Allard, J.R., Nadeau, J.E. et al. The importance of adequate nutrition in closure of small intestinal fistulas. *Br. J. Surg.* 61, 724-726.
- Holmes, J.T. (1977) Nutritional support of fistulas. *Br. J. Surg.* 64, 695-697.
- Irving, M. (1977) Local and Surgical Management of enterocutaneous fistulas *Br. J. Surg.* 64, 690-694.
- Kaminsky, V.M. and Deitel, M. (1975) Nutritional support in the management of external fistulas of alimentary tract. *Br. J. Surg.* 62, 100-103.
- MacFedyen Jr, B.V., Dudrick, S.J. and Ruberg R.L. (1973) Management of gastrointestinal fistulas with parenteral hyperalimentation. *Surg* 74, 101-105.
- Monod - Broca, P. (1977) Treatment of intestinal fistulas. *Br. J. Surg* 64, 685-689.
- Sheldon, G.E., Gardiner, B.N., Way, L.W. et al. 1971 Management of gastro intestinal fistulas. *Surg. Gynae and Obstet* 133, 385-389.