

RETAINED INTRAOCULAR FOREIGN BODIES AND VISUAL PROGNOSIS

TAN POOI LIEW

SUMMARY

3 cases of perforating injury with retention of intraocular foreign body are presented. Their clinical presentation, management and final visual results are discussed. Despite the generally poor prognosis associated with these injuries, some cases surprisingly have good visual results.

INTRODUCTION

FOREIGN bodies lodged in the eye following perforating injuries are serious ophthalmic emergencies. The retention of a foreign particle within the eye-ball may result in infection, sympathetic ophthalmitis, local irritative and chemical reaction apart from the mechanical damage caused at the time of the accident. The visual prognosis is extremely variable because of so many factors such as extent and site of injury, nature of foreign body, etc. Duke Elder has stated that when the foreign body is in the posterior segment of the globe and has been allowed to remain there, the end results in terms of vision are extraordinarily difficult to assess.

3 cases of perforating injury with retention of foreign body are presented. The minimum follow up has been for 18 months.

CASE NO. 1

A 21 yr old student Y.C.H. living in Banting was hammering a piece of machinery in his back yard on 19.4.78, when suddenly a foreign body hit his left eye resulting in rapid loss of vision.

Tan Pooi Liew, D.O. (Lon.); FRCS (Edin.)
Department of Ophthalmology,
Faculty of Medicine,
University Kebangsaan Malaysia,
Jalan Raja Muda,
Kuala Lumpur.

He sought treatment at the District Hospital in Klang, where he was subsequently referred to the Eye Clinic at Hospital Besar, Kuala Lumpur.

On examination, his left visual acuity was reduced to hand movements only. There was a 3mm perforating wound of the cornea, situated nasal to the centre of the pupil at 5 o'clock position. The lens was completely cataractous. An X-ray of his left orbit showed a dense opaque small foreign body in the posterior part of his eye. The patient underwent emergency surgery. First the corneal laceration was sutured up, with the help of the operating microscope. Then a giant electro-magnet was used in an attempt to remove the metallic foreign body. This was unsuccessful, and it was concluded that the foreign body was non-magnetic; hence the failure to remove it.

The patient's post-operative recovery was uneventful. The corneal wound healed satisfactorily. However his left visual acuity was still hand movements because of the traumatic cataract. The eye was comfortable and showed no evidence of siderosis (iron rusting).

About 2 months later on 8.6.78, the patient underwent a second operation for removal of his cataract. Needling and aspiration of his cataract was done. Again his post operative recovery was uneventful. With the removal of his cataract, the vitreous and retina could now be seen. The optic disc and retina appeared healthy (Fig.1). However, a small white refractile mass was seen floating in the vitreous at the 5 o'clock position (Fig.2). This was presumed to be the intra-ocular foreign body. There was no evidence of siderosis. About 1 month following the operation his left eye was refracted, and with a + 11.50 dioptre spherical lens he could see normally i.e. 6/6 vision. Later he was fitted with a contact lens to

his left eye. This patient has been reviewed at 3 monthly intervals. His left vision continues to be 6/6 with his contact lens up to 20 months after the injury.

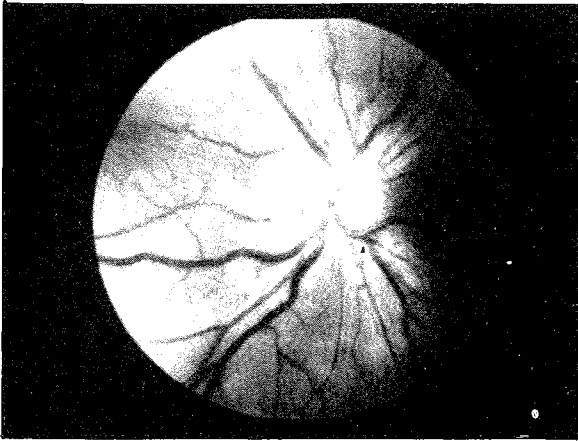


Fig. 1. Right fundus of Case no. 1 showing a healthy normal fundus.

CASE NO 2

This was a 23 yr. old Indian labourer T.T. who was first seen in the Eye Clinic on 3.5.78. He said that while hammering some equipment on that morning, something flew and hit his left eye. His left visual acuity was 6/24. There was a 3mm perforating corneal wound at 9.00 o'clock position. His lens was partially cataractous. The vitreous and retina could not be visualised. X-ray examination of the left orbit confirmed an intra-ocular small dense radio-opaque foreign body in the posterior eye ball.

The patient underwent surgery the next day. The corneal laceration was sutured. The Giant Electro-magnet was used in an attempt to remove the foreign body. Again as in the first case this was unsuccessful. The foreign body was presumed to be non-magnetic. Later a second attempt at removal also failed. Postoperatively the traumatic cataract increased in size and showed signs of causing secondary glaucoma. As a result, on 25.5.78, the patient underwent a second operation i.e. needling and aspiration of the cataract. His post-operative recovery was uneventful. Examination of the vitreous and retina showed no abnormal changes except a haemorrhagic area on the nasal retina. The

foreign body was not visualised, but was presumed to be retained in the ocular tissues. The best corrected vision in his aphakic left eye was 6/9.

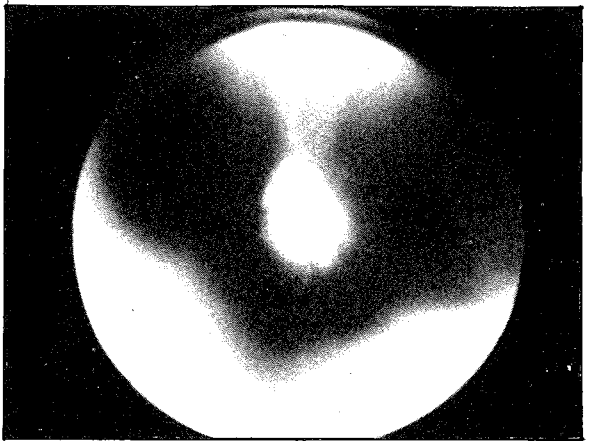


Fig. 2. Picture of the Vitreous in Case no. 1 showing a white refractile foreign body in it.

CASE NO 3

C.C.H., a 25 years old factory worker came to the Eye Clinic on 6.5.78 with a history that some thing had entered his left eye while he was hitting concrete the previous day.

On examination, his left visual acuity was only counting fingers. There was a self-sealing small perforating injury on his cornea at 10 o'clock at the periphery. The lens was also injured and had become completely cataractous. X-ray of his left orbit showed a faint radio-opaque foreign body in the posterior eye ball. Again, attempts to remove the foreign body with the Giant Electro-magnet failed. The foreign body was presumed to be a very small piece of stone. On 23.5.78, he underwent a needling and aspiration operation to remove the left traumatic cataract. His post-operative recovery was uneventful. The left pupil could only be maximally dilated to 4mm because of posterior synechiae. Examination of his vitreous and retina revealed them to be normal. The foreign body could not be seen, but presumed to be hidden in the periphery by the small pupil.

With contact lens, he could see 6/6 with his left eye. The patient has been followed up

regularly for the last 19 months. His left eye can see normally with contact lens, and continues to be comfortable.

DISCUSSION

"The retention of a foreign body within the eye is not a very common injury" (Duke Elder). Permanent retention as a result of inability to remove the foreign particle is even more uncommon. Roper Hall analysed 555 cases of intraocular foreign bodies, and found that in 60 patients (11 percent), the foreign body could not be removed. (M.J. Roper Hall).

Visual prognosis in retained intraocular foreign bodies is generally poor. (H.P. Adhikary and P. Taylor). This has been the experience of the author as well, but in spite of generally poor prognosis, a few cases end in favourable visual

results. These eyes should not be given up as lost and every attempt must be made to salvage them.

ACKNOWLEDGEMENT

I am grateful to Prof. Datuk Mohd Noor Marahakim for the help and encouragement given and to Puan Husna Idris for the secretarial help.

REFERENCES

- Adhikary, H.P. and Taylor P. (1976) Prognosis of Perforating Eye Injury, *Brit.J.Ophthalmol.* **60**, 737-739.
- Duke Elder, (1972). System of Ophthalmology Vol XIV Injuries Part I, 1st edition, London, Henry Kimpton, 477-649.
- Roper-Hall, M.J.(1954) Review of 555 cases of Intraocular Foreign Body with Special Reference to Prognosis, *Brit.J. Ophthalmol.* **38**, 65-99.