

PSEUDOMYXOMA PERITONEI — A CASE REPORT

C. C. HO

INTRODUCTION

Pseudomyxoma peritonei is a rare condition in which mucinous material is found free within the peritoneal cavity. This condition is associated with ovarian cysts, mucocele of appendix, urachal cysts and rarely mucous secreting carcinomas of the gastrointestinal tract (Jones, 1965). Werth was the first to describe the presence of gelatinous material in the peritoneal cavity in 1884. He ascribed his first case to a ruptured pseudomucinous cyst of an ovary. Fraenkel in 1901 reported this condition in a man which resulted from a ruptured appendicular mucocele. Weaver in 1937 reporting a series of 256 cases of mucoceles of the appendix, found peritoneal pseudomyxoma in only 0.11 per cent of these cases. This rare, interesting condition has yet to be reported in Malaysian literature though two cases of mucocele of appendix were reported by Hussein Salleh (1973).

Case Report

M.P. a 65 year old Indian man, presented with progressive abdominal distension and marked loss of weight over seven months. There was no history of abdominal pain, dyspepsia, jaundice or ankle edema. He was not a chronic alcoholic and had no change of bowel habits. Physical examination revealed an emaciated man weighing 36.6 kilograms (Fig. 1). There was no stigmata of liver failure.

Examination of the abdomen revealed very tense distension. Girth was 82 cm. Shifting dullness and fluid thrill could be elicited with some difficulty. Firm knobby masses measuring about 4 to 5 cm in diameter were palpable all over the abdomen. It was not possible to palpate the liver or spleen. In the left inguinal region was a firm oval mass, 2 by 3 cm, which could be reduced into the inguinal canal.

C.C. Ho
MBBS (Mal.)

Department of Medicine, University Hospital,
Kuala Lumpur,
Malaysia

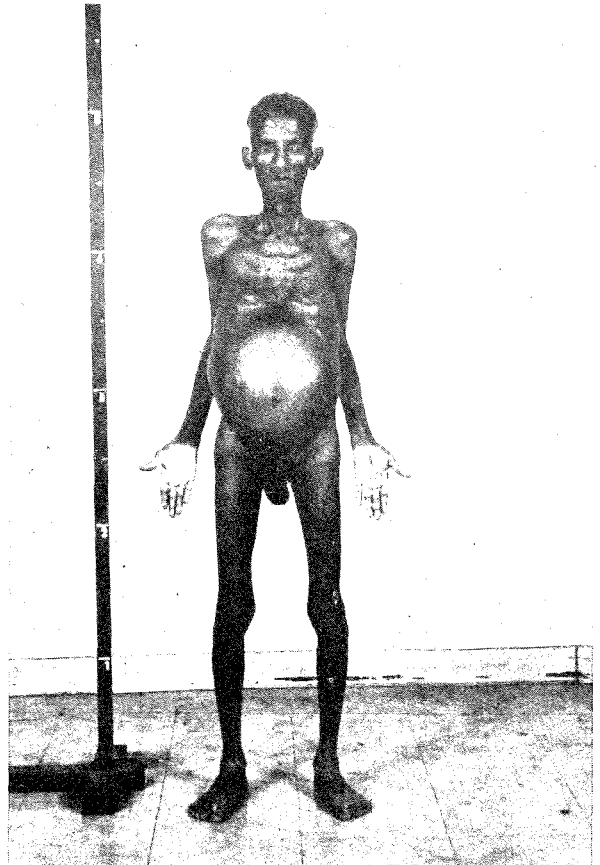


Fig. 1 Gross abdominal distension in the patient. Note his alertness and relative well-being.

Rectal examination and sigmoidoscopy were normal. Investigations showed a hemoglobin of 9.5 mg% with a normal white count. Liver function test showed that serum albumin was low (2.3 gm%) and alkaline phosphate was 110 iu/L, Alpha feto protein was negative. Abdominal x-rays revealed no calcification or fluid levels. Barium meal and follow-through showed the small bowel to be grossly distorted and displaced upwards. No intrinsic lesions were seen in the stomach or small bowel. Abdominal ultrasound showed diffuse abnormal mixed echoes arising from the whole abdominal cavity completely obliterating the outlines of the abdominal organs. A peritoneal tap obtained thick gelatinous straw-

coloured fluid. Subsequent peritoneal taps showed the presence of benign goblet cells in the peritoneal fluid. Pseudo-mucin stained with mucicarmine was positive. Culture for acid fast bacillus was negative. Biopsy of the left inguinal mass showed a well encapsulated cystic mass with abundant mucin and scattered fragments of benign mucin-producing epithelium. The mass was thought to be an inguinal herniation of pseudomyxoma peritonei.

At laparotomy a large encapsulated peritoneal cavity filled with 4.25 kg (3750 mls) of thick gelatinous brownish material was found.

All the peritoneal surfaces were studded with irregular fleshy nodules varying from 2 cm to 6 cm in diameter (Figure 2). (Histologic examinations of the wall of the nodules revealed only inspissated mucin with no cellular elements). Only part of the caecum was visible. The appendix and other viscera were not visualized completely. Mucinous material was evacuated and the peritoneal cavity was irrigated with 25 mg cyclophosphamide (Endoxan). Post-operative recovery was good and patient was sent on leave. Abdominal girth was 72 cm then. When re-admitted three weeks later, his abdominal girth had increased to 79 cm again. Repeat paracentesis yielded a total of 3650 mls of blood stained fluid with gelatinous material. Cyclophosphamide (50 mg) was instilled intraperitoneally. Re-examination of the gelatinous fluid revealed benign columnar mucous producing epithelial cells. The patient continued to be seen for abdominal distension which required paracentesis and instillation of cyclophosphamide every two to four weeks. He, however, remained ambulant and active throughout his illness and subsequent admissions.

DISCUSSION

Pseudomyxoma peritonei as a clinical entity is more frequently of ovarian origin than appendiceal. Rosenfield (1949) in his report of 4 cases of pseudomyxoma peritonei believed that though ovarian origin of this condition is more frequently noted, a normal appendix has never been reported or demonstrated in such a female patient. In at least 25 per cent of reported cases in which the condition occurred in a woman, it had a dual origin imparted to it because in those cases where the appendix was examined, a mucocele was found. This patient is a male and though his viscera could not be visualized com-

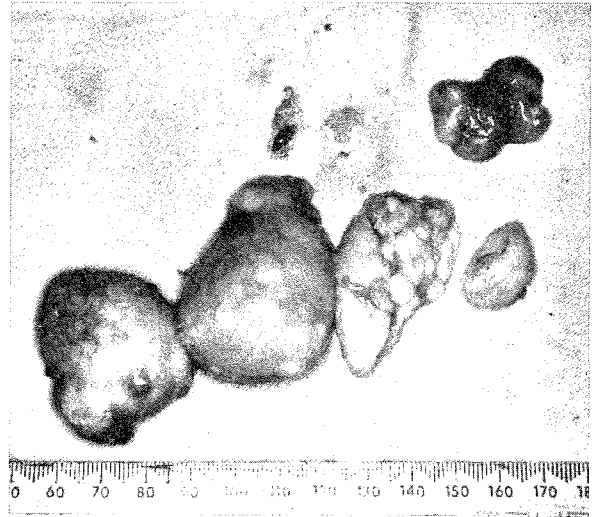


Fig 2 Several of the multiple "nodules" of inspissated mucin found all over the peritoneal cavity.

pletely at laparotomy, his condition is probably secondary to an appendiceal mucocele in view of the multiple benign mucous producing epithelium found in the gelatinous fluid and the negative finding of gastrointestinal malignancies on barium studies and sigmoidoscopy.

The pathogenesis of this condition has been the subject of dispute since its first description in 1884. The theories of today remain as conjectural as they were a century ago. In a male patient, pseudomyxoma peritonei is usually due to a ruptured mucocele of the appendix. It is generally agreed that the first phase in the development of a mucocele is obstruction of the appendix due to one or more attacks of inflammation, fecal concretions or rarely carcinoid tumours (Evans, 1959; Edlund, 1950). The lumen distal to the obstruction continues to secrete mucus into a closed space. An apparent increase in the mucus-secreting goblet cells with atrophy of the muscular layers occurs. When the mucocele ruptures, "seeding" of the peritoneum. Two theories have been expounded to explain the resultant pseudomyxomatous condition. Some authors believe that cells spilled from the mucocele could proliferate on the peritoneal surface and secrete mucin. Another school

proposed that the peritoneal lesions represent a reaction of the peritoneum to mucin, resulting in metaplasia to tall columnar epithelium. In rabbits, Grodinsky and Rubnitz (1941) were able to reproduce the conditions by producing and rupturing the mucoceles intraperitoneally. They also demonstrated that mucin minus the cellular elements (filtered by Seitz filter) did not result in peritoneal pseudomyxomas. This seemed to substantiate the theory that mucoid material was innocuous. Rubnitz, however, after further experimental work concluded that their initial theory was wrong and that it was the mucoid material, and not the cellular elements that was responsible for the condition.

Woodruff and McDonald (1940) considered pseudomyxomatous lesions as metastatic and that only "malignant" mucocele produced pseudomyxoma peritonei. Their criterion of malignancy was a papillary network of cells within a cyst which they called "adenocarcinoma Grade I". Other authors (Rosenfield, 1940; Hughes, 1967) could find no justification for this classification. Moreover, if one accepts metastasis as implying malignancy then only the two cases of Bernhardt and Young (1965) can be considered truly malignant (having metastasized to the anterior abdominal wall and axillary nodes).

The clinical diagnosis of peritoneal pseudomyxoma is not difficult though most cases were only diagnosed at laparotomy or post-mortem. A history of recurrent abdominal pains, slowly progressive distension of abdomen with indefinite contours and the small fluctuations and change of percussion note with change of position of the patient are characteristic of the condition. Our patient had all except the first feature and his diagnosis was confirmed on removal of the left inguinal hernial sac. Such a diagnosis made through a hernial operation has been the experience of Elliot (1957), Parsons and Thorbjarnarson (1970). The final diagnosis, being a gross anatomic one, is confirmed at laparotomy. The relative well being of patients with peritoneal pseudomyxoma despite the grossly distended abdomen as noted in this patient has been the observation of other authors (Elliot, 1957; Evans and Murphy, 1959, Bernhardt and Young, 1965). However, in advanced cases, hypoproteinemia and cachexia might occur.

Rarer presentations include polyuria (Edlund, 1950), hypoglycemia and splenic infarction (Rosenfield, 1949) and blood borne metastasis to the abdominal wall and axillary lymph nodes (Bernhardt and

Young, 1965).

The treatment of such patients is fraught with differences of opinion. While every author agrees that laparotomy and "bailing out" procedures should be undertaken, subsequent attempts at preventing reaccumulation have been differently executed. External radiotherapy has been used with variable results (Edlund, 1950; Evans, 1959, Grodinsky and Rubnitz, 1941, Elliot, 1957).

Pseudomyxoma peritonei may disappear following removal of the ruptured mucocele alone. However, the peritoneal masses may disappear even though the appendix, presumably the cause, is not removed. Grodinsky and Rubnitz (1941) suggested that in addition to appendectomy, large areas of the visceral and parietal peritoneum should be removed. The value of such extensive procedures is difficult to evaluate because of the scarce number of (early) cases for which they can be performed. Long *et al.* (1969) found that evacuation of mucin and instillation of alkylating agents conferred the best results in their patients. Thio-tepa, radioactive gold, nitrogen mustards have also been used with variable results (Byron, 1966, Long, 1969). This patient was subjected to laparotomy and evacuation of mucin. The advanced stage of this patient made further surgical procedures, even an appendectomy, hazardous. Initial washing of his peritoneal cavity with cyclophosphamide was undertaken. This failed to arrest the process. He was later subjected to repeated paracentesis and instillation of cyclophosphamide which seemed to control the process. Instillation of cytotoxics has been found to be superior to washing or irrigation with cytotoxics by Cole *et al.* in 1965.

SUMMARY

A case of pseudomyxoma peritonei is reported. Pathogenesis, clinical features and modes of treatment are discussed. This patient appears to have responded to laparotomy, paracentesis and instillation of cyclophosphamide intraperitoneally.

ACKNOWLEDGEMENT

I would like to thank Professor M. Somasundaram and Professor Loh Thiam Ghee for their invaluable advice and encouragement. My gratitude also goes to Puan Rohani for typing the manuscript.

REFERENCES

- Bernhardt, H. Young, J.M. (1965) Mucocele and pseudomyxoma peritonei of appendical origin, *Am. J. Surg.*, 109, 235-241.
- Byron, R.L., Yonemoto, R.H., King, R.M. *et al.* (1966) The management of pseudomyxoma peritonei secondary to ruptured mucocele of the appendix, *Surg. Gynec. Obstet.*, 22, 509-512.
- Cole, W.H., Roberts, S.S., Webb, R.S. *et al.* (1965) Dissemination cancer with special emphasis on vascular spread and implantation, *Ann. Surg.*, 161, 753-770.
- Edlund, Y. (1950) Mucocele of the Appendix and pseudomyxoma peritonei, *Acta. Chir. Scand.*, 100, 626-636.
- Elliot, C.E. (1957). Two cases of pseudomyxoma peritonei from mucocele of the appendix, *Brit. J. Surg.*, 45, 15-81.
- Evans, R.W., Murphy, A.F. (1959) Pseudomyxoma peritonei associated with an appendix obstructed by an argentaffinoma in a male, *Brit. J. Surg.*, 47, 166-172.
- Grodinsky, M., Rubnitz., A.S. (1941) Mucocele of the appendix and pseudomyxoma peritonei, *Surg. Gynec. Obstet.*, 73, 345-354.
- Hughes, J. (1967) Pseudomyxoma Peritonei, *Ann. Surg.*, 165, 73-76.
- Jones, D.H. (1965) Pseudomyxoma Peritonei, *Brit. J. Clin. Prac.*, 19, 675-679.
- Long, R.T., Spratt, J.S., Dowling, E. (1969) Pseudomyxoma Peritonei - New concepts in management with a report of seventeen patients, *Am. J. Surg.*, 117, 162-169.
- Parsons, J., Gray, G.F., Thorbjarnarson, B. (1970) Pseudomyxoma Peritonei, *Arch. Surg.*, 101, 545-549.
- Rosenfield, D.D. (1949) Peritoneal Pseudomyxoma - a report of four unusual cases, *Arch. Path.*, 48, 255-273.
- Salleh, H.M. (1973) Mucocele of the appendix, *Mal. Med. J.*, 28, 91-93.
- Weaver, C.H. (1937) Mucocele of appendix with pseudomucinous degeneration, *Am. J. Surg.*, 36, 523-526.
- Woodruff, R., McDonald, J.R. (1940) Benign and malignant cystic tumors of the appendix, *Surg. Gynec. Obstet.*, 71, 750-755.