

# EBSTEIN'S ANOMALY OF THE TRICUSPID VALVE: A REPORT OF 10 CASES

M. ANUAR+K.T. SINGHAM

## INTRODUCTION

THE finding of a tricuspid valve which has been displaced into and greatly reducing the size of the right ventricular cavity was first noted during an autopsy of a young man by the German physician, Wilhelm Ebstein in 1866. It was some eighty three years later, in 1949, that the first case was diagnosed antemortem by Tourniaire, Deyrieux and Tartulier in France. The diagnosis has been made with increasing frequency antemortem in the last twenty years.

We are reporting our clinical experience with 10 cases of Ebstein's disease diagnosed at the University Hospital, Kuala Lumpur.

## MATERIAL AND METHOD

This study includes all patients diagnosed to have Ebstein's anomaly at the University Hospital, Kuala Lumpur from 1967-1979. At least one 12-lead electrocardiogram, chest radiograph and cardiac catheterization were performed on all patients. Three patients had echocardiogram performed as well.

## RESULTS

### Sex and Age

There were 2 males and 8 females in this series; the youngest being 1 month and the eldest 44 years of age at diagnosis.

### Family history

There were no instances of familial Ebstein's anomaly in our series. Gueron *et al.* (1966)

reported two siblings with this condition and two years later Donegan *et al.* (1968) reported a 6 year old boy with a 29 year old maternal uncle suffering from Ebstein's anomaly. Simcha and Bonham-Carter (1971) noted 2 families in which more than one member were similarly affected. Watson (1974) in a collected series of 505 cases found a family with 2 sisters clinically diagnosed as having the condition. Richard Emanuel (1976) studied 120 first-degree relatives of 26 patients with Ebstein's anomaly and found no case in any of them.

### Associated lesions

Associated cardiovascular anomalies other than interatrial communications were not found in this series. Three patients had patent foramen ovale. In the assembled series of Hamish Watson 48% were found to have associated lesions, the most frequent being defects in the interatrial septum.

### Symptoms

All of our patients were symptomatic at the time of diagnosis. Effort dyspnoea and easy fatiguability were dominant symptoms in 7 patients. Orthopnoea was present in one patient. Two patients had transient syncopal attacks and palpitations with documented attacks of paroxysmal atrial tachycardia was found in another. Five of 10 patients were noted to have cyanosis prior to first examination.

## PHYSICAL FINDINGS

### Peripheral examination

Cyanosis was found in 5 patients. Two of the three children in this series were noted to have cyanosis soon after birth while the others developed cyanosis at 3 years of age. This is in keeping with the findings of larger series where cyanosis usually appears insidiously between 3 and 12 years of age (Simcha *et al.*, 1971). Four patients had clubbing of the finger tips.

Five of our patients were in atrial fibrillation at the time of first examination. Pulses were

---

M. Anuar, MBBS, MRCP (UK)

K.T. Singham, MBBS, M.Med., MRCP, FRACP

Department of Medicine, University Hospital, Kuala Lumpur, MALAYSIA.

Correspondence: Assoc. Prof. M. Anuar  
Department of Medicine  
Faculty of Medicine  
University of Malaya  
Kuala Lumpur, MALAYSIA.

---

generally small in volume. Three patients with pericardial effusions exhibited pulsus paradoxus. Blood pressure readings were normal. Elevated jugular venous pressure was noted in 7 patients. Contrary to what is generally believed however, only 1 of them demonstrated a large 'v' wave secondary to tricuspid regurgitation. No patient had large 'a' waves in the jugular veins. Rapid 'y' descent was noted in the three patients with pericardial effusion.

### Central examination

Cardiomegaly was noted in 9 patients. Cardiac pulsations were however much reduced in only 7 patients. In 3 patients active pulsations were noted in the second and third left parasternal spaces, this being subsequently found to be due to active pulsations of the right ventricular outflow tract. Diminished intensity of heart sounds was noted in only 4 of the 10 cases. A 3rd heart sound was heard in all but on patient. Only half of our patients exhibited a soft ejection systolic murmur in the left sternal edge. No patient had any diastolic murmur.

### Radiologic examination

Chest radiographs showed cardiomegaly in all nine who had clinically detectable enlargement of the heart (Fig. 1). The pulmonary vasculature appeared normal in 9 patients; however, marked oligemia was noted in one. Fluoroscopy was done in four patients and a consistent finding was generalised poor pulsation of the heart with the exception of the very active right ventricular outflow tract.

### Electrocardiography

The suggestively diagnostic pattern of complete right bundle branch block with abnormally low R and S waves over the right praecordium was not found in any of our patients. In keeping with the twenty proven cases assembled from the literature by Keith (1978) however, R and S waves measuring less than 7 mm in the right praecordial leads were noted in 9 of our cases. Abnormalities of the P waves consisting of either increases in amplitude and/or duration were seen in all 5 patients with sinus rhythm. Five patients had atrial fibrillation and one exhibited paroxysms of supraventricular tachycardia. The mean QRS axis ranged from  $+10^{\circ}$  to  $+150^{\circ}$ . None of our patients exhibited Wolff-Parkinson-

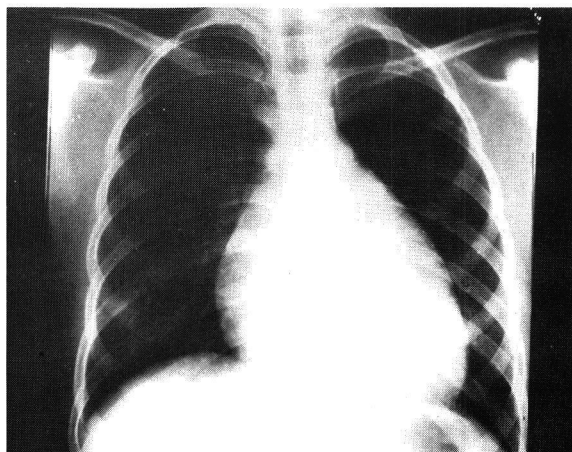


Fig. 1. Plain chest x-ray showing cardiomegaly with pulmonary oligemia.

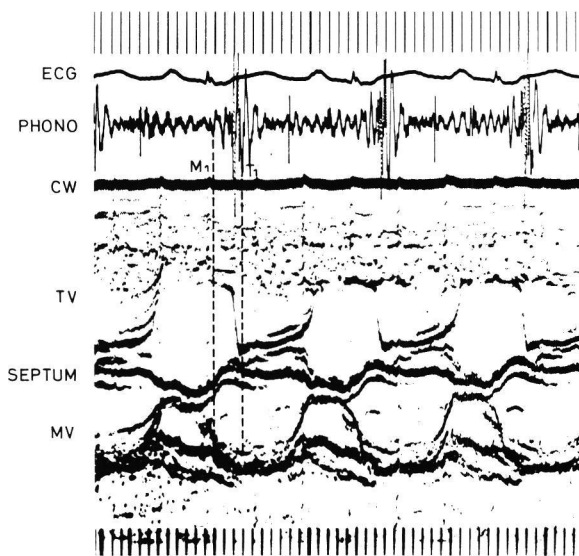


Fig. 2. Echocardiography showing a delayed closure of the tricuspid valve and a slow tricuspid valve closure rate;  $q_{T_1} = 40$  mSec;  $q_{T_1}^{T_1} = 160$  mSec;  $q_{T_1} - q_{M_1} = 120$  mSec. [ $M_1$  = mitral valve closure;  $T_1$  = tricuspid valve closure; TV = tricuspid valve; MV = mitral valve, CW = chest wall].

White syndrome, a feature found in about 10 per cent of patients with Ebstein's anomaly of the tricuspid valve.

### Echocardiography

Echocardiography was done in 3 patients. In two patients, delayed closure of the tricuspid valve was demonstrated (Fig. 2). This, and an abnormally anterior position of the anterior leaflet of the tricuspid valve during diastole (Lundstrom, 1973) have been deemed to be features consistently found in the echocardiograms of patients with this condition. In one patient a significant pericardial effusion was detected at echocardiography.

### Cardiac catheterization

All but one patient underwent right heart catheterization. In 8 patients the catheter was noted to be coiled up in the abnormally dilated right atrium. The right atrial mean pressure exceeded 15 mmHg in 5 patients. Probe patency of the foramen ovale was noted in 3 patients and arterial desaturation detected in 6 patients. A feature common to all patients catheterized was the difficulty encountered in entering the right ventricle followed by the showers of ventricular extrasystoles at the time of catheter manipulation in the ventricle. Electrode catheter recordings of simultaneous intracardiac electrocardiograms and pressures were done in 6 patients. Confirming Hernandez's experience (1958), this procedure detected the atrialised portion of the right ventricle in 5 patients (Fig. 3).

### Angiocardiography

Selective angiography was done in all 10 patients. In all cases a large right atrium occupying over half the cardiac shadow was demonstrated (Fig. 4). Also consistently found was the late emptying of the right atrium into the rudimentary right ventricle. The tricuspid valve was displaced laterally and to the left (fig. 4) and its relation to the annulus was shown as two notches at the inferior cardiac border.

### DISCUSSION

Ebstein's anomaly of the tricuspid valve is a relatively uncommon condition. If 61 centres in the cooperative study guided by Watson (1974)

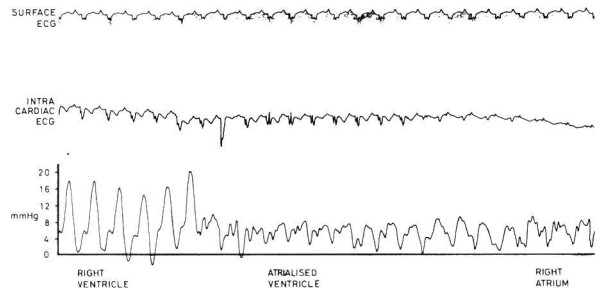


Fig. 3. Intracardiac electrocardiogram demonstrating the atrialised portion of the right ventricle.

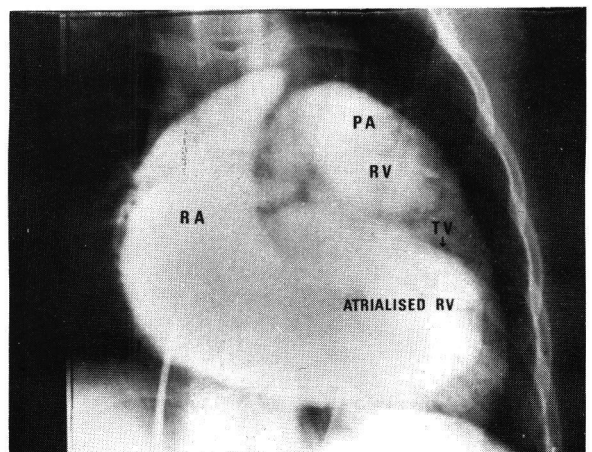


Fig. 4. Right atrial angiogram showing a very large right atrium with the tricuspid valve being displaced into the right ventricle [PA = pulmonary artery; RV = right ventricle; RA = right atrium].

only 17 collected more than 10 cases. The prognosis varies considerably; some patients live a completely normal life, the anomaly being an incidental finding at autopsy. The oldest patient recorded was 79 years old (Makons and Vander Veer, 1966), while at the other end of the spectrum, an infant died at 3 days of age from complications of the disease (Keith, 1978). The majority of deaths occur between the second and fourth decades of life. Six of our patients lived beyond 20 years of age while two were seen in infancy.

The sex ratio in our population of Ebstein's anomaly is probably not a true reflection of the sex incidence of this condition. In the cooperative study of Watson (1974), there were 258 males and 247 females, confirming the impression obtained from earlier smaller series that there is no difference in the sex incidence of this malformation (Vacca *et al.*, 1958 and Ganton & Blount, 1962).

There were no familial cases in our series and no obvious predisposing causes could be elicited in our patients. An interesting report of this latter aspect of the disease was made by Nora (1974) who noted that four of eight babies with congenital heart disease born to mothers exposed to lithium during pregnancy had Ebstein's disease. This is a sobering thought considering the number of young females in the reproductive age group who are on lithium carbonate therapy for manic depressive psychosis.

The clinical presentation of our patients are no different from those of previous series. Seven of the 10 patients presented with symptoms of effort dyspnoea of long standing. In the large series of Watson (1974) of the 35 cases under 1 year, 86% were in functional class III or IV by the New York Heart Association's classification. Seventy one per cent of those between one and twenty five years of age were in functional class I and II, while 60% of those over 25 years of age also had little or no disability.

No single physical sign or groups of signs are pathognomonic of this condition. While the presence of a large silent heart is frequently quoted as a usual finding, in 3 of our patients active pulsations were noted in the pulmonary area. These active pulsations transmitted from

the outflow tract of the right ventricle should not be misinterpreted as evidence of right ventricular hypertrophy. Although tricuspid regurgitation can be found in this disease, it is not invariable. A large 'v' wave in the jugular veins and an enlarged pulsatile liver, were noted in only 1 of our patients. Takayasu in 1978 reported 26 patients with Ebstein's anomaly, only 4 of whom had dominant tricuspid incompetence. Eight of their patients had dominant tricuspid stenosis while 14 were classified as mild cases.

Just as no physical sign is diagnostic, the common investigatory tools are seldom able to confirm the diagnosis of Ebstein's anomaly of the tricuspid valve. In many cases, the chest radiograph and electrocardiograph may suggest the diagnosis. However, cardiac catheterization and angiography are usually required to confirm it. While cardiac catheterization was at one time deemed very dangerous in this condition, recent experience suggest that it is not very much more hazardous to catheterize these patients than other sick patients with other congenital or acquired heart disease as is borne out by our experience. Clues to the diagnosis are the tendency for the catheter to coil in the grossly enlarged RA, difficulty in entering the abnormally positioned tricuspid valve and the showers of ventricular extrasystoles associated with the procedure. In Watson's series, no less than 100 of 363 patients undergoing catheterization experienced paroxysmal dysrhythmias. Intracavitary electrocardiography may provide convincing evidence of the presence of an abnormally positioned tricuspid valve associated with atrialisation of the right ventricle. Selective angiocardiology clearly identifies the displaced tricuspid valve.

In recent years, echocardiography has proven to be useful in this condition. Two of our 3 patients who underwent this examination demonstrated what are now considered to be specific echocardiographic signs of Ebstein's anomaly which are the ability to record the anterior tricuspid leaflet further to the left of the left sternal border; and abnormally prolonged interval between the closure points of the tricuspid valve and the mitral valve demonstrating delayed tricuspid valve closure (Farooki *et al.*, 1976).

Management of all our patients were entirely

conservative. Symptomatic patients were placed on digoxin and diuretics and any infections, especially chest infections, were aggressively treated. None of our patients required long term antiarrhythmic therapy.

Surgical treatment of this condition is presently limited to a few selected cases. Its role and the procedure of choice for its correction are not yet clearly defined. At present, surgery seems to be indicated in patients with intractable congestive heart failure and those with repeated, arrhythmias especially when they are difficult to control (Watson, 1974 and Keith, 1978).

The prognosis of this condition is variable. However, life expectancy is considerably reduced in patients with Ebstein's anomaly as a whole. Hansen (1977) in a long-term follow up of 22 patients identified cyanosis due to a right-to-left shunt through an atrial septal defect as the best guide to distinguish the group with a good from the one with a bad prognosis. Right sided heart failure and dyspnoea at rest, often associated with palpitations, praecordial pains and syncope are grave prognostic findings.

## SUMMARY

The clinical features, plain film radiological findings, electrocardiographic findings, echocardiographic changes, haemodynamics and angiographic features of 10 patients with Ebstein's anomaly of the tricuspid valve are described. The ages of the patients varied between 1 month to 44 years. There were 2 males and 8 females. Common symptoms were effort dyspnoea, palpitations and cyanosis. Cardiomegaly with an obvious third heart sound was present in majority of patients. Echocardiography showed an obvious delay in tricuspid valve closure and angiography demonstrated characteristic displacement of the tricuspid valve into the right ventricular cavity.

## REFERENCES

Bialostozky, D., Medravo, G.A., Munoz, L. and Fontreras, R. (1972) Vectocardiographic study and anatomic observations in 21 cases of Ebstein's malformation of the tricuspid valve. *Am. J. Cardiol.*, **30**, 354-361.  
Donegan, C.C., Jr., Moore, M.M., Wiley, T.M., Hernandez, F.A., Gree, J.R. JR. and Schiekler, G.K. (1968) Familial Ebstein's anomaly of the tricuspid valve. *Am. Heart J.*, **75**: 375-379.

Emanuel, R., O'Brien, K. and Ng, R. (1976) Ebstein's anomaly. Genetic study of 26 families, *Br. Heart J.*, **38**, 5-7.  
Farooki, Z.Q., Henry, J.G. and Green, E.W. (1976) Echocardiographic spectrum of Ebstein's anomaly of the tricuspid valve. *Circulation*, **53**(i), 63-68.  
Ganton, E. and Blount, S.G. Jr. (1967) The spectrum of Ebstein's anomaly. *Am. Heart J.*, **73**: 395-425.  
Guéron, M., Hursh, M., Stern, J., Cohen, W. and Sevy, M.J. (1966) Familial Ebstein's anomaly with emphasis on surgical treatment. *Am. J. Cardiol.*, **18**, 105-111.  
Hansen, J.F., Leth, A., Dorph, S. and Wennevoed, A. (1977) The prognosis in Ebstein's disease of the heart. *Acta Med. Scand.*, **201**, 331-335.  
Hernandez, F.A., Rochkind, R. and Cooper, H.R. (1958) The intracavitary electrocardiogram in the Diagnosis of Ebstein's anomaly. *Am. J. Cardiol.*, **1**, 181-190.  
Keith, J.D. (1978) Ebstein's disease. Heart diseases in infancy and childhood. 3rd Edition, MacMillan Publication Co. Inc. N.Y., pp 847-855.  
Lundstrom, N.R. (1973) Echocardiography in the diagnosis of Ebstein's anomaly of the tricuspid valve. *Circulation*, **47**, 597-605.  
Makons, N. and Vander Veer, J.B. (1966) Ebstein's anomaly and life expectancy. *Am. J. Cardiol.*, **18**, 100-104.  
Nora, J.J., Nora, A.H. and Toews, W.H. (1974) Lithium, Ebstein's anomaly and other congenital heart defects. *Lancet*, **2**, 594-595.  
Simcha, A. and Bonham-Carter, L.E. (1971) Ebstein's anomaly: clinical study of 32 patients in childhood. *Br. Heart J.*, **33**, 46-49.  
Takayasu, S., Obunai, Y., Konno, S. (1978) Clinical classification of Ebstein's anomaly. *Am. Heart J.*, **95**[2], 154-162.  
Vacca, J.B., Bussmann, D.W. and Mudd, J.G. (1958) Ebstein's anomaly: complete review of 108 cases. *Am. J. Cardiol.*, **2**, 210-226.  
Watson, H. (1974) Natural history of Ebstein's anomaly of tricuspid valve in childhood and adolescence. *Br. Heart J.*, **36**, 417-927.