

## EDITORIAL:

### ETERNAL VIGILANCE IS THE PRICE

In the 1960s smallpox was an endemic disease in some 50 to 60 countries, and was periodically introduced into other countries by travellers from endemic areas. In 1967 WHO launched the Intensified Smallpox Eradication Programme, and with the collaboration of national health authorities, smallpox was progressively eradicated from one country after another until the last case of naturally acquired smallpox anywhere in the world occurred in Somalia in October 1977. Eradication of this ancient scourge of mankind is one of the greatest accomplishments of preventive medicine and is a tribute to international collaboration for human well-being.

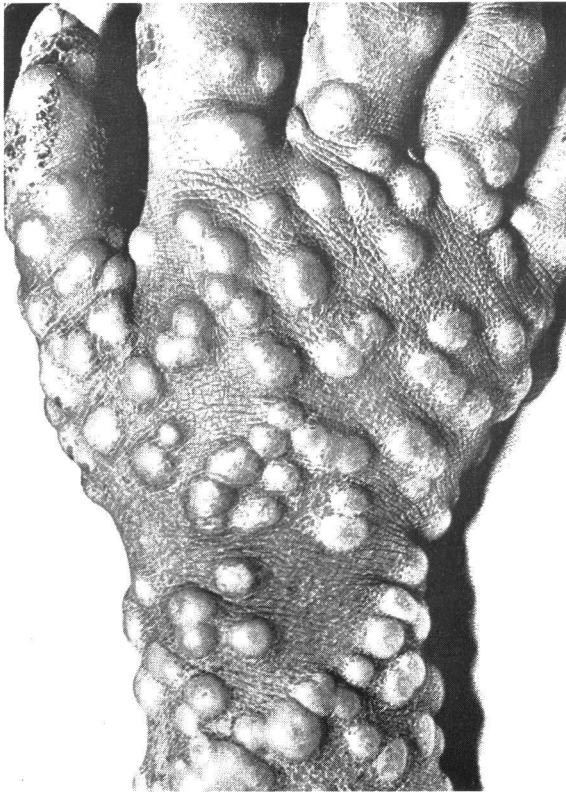
In spite of the confidence engendered by the fact that nowhere has smallpox recurred after a country was declared free of the disease (including such 'high risk' areas as Indonesia, India and Bangladesh, where the last cases occurred in January 1972, May 1975 and October 1975, respectively) the World Health Organization has established an 'insurance policy' to guard against any possible unexpected happening that may cause smallpox to recur. This has several components. Active surveillance is being maintained in Zaire, where a related virus normally circulating in wild animals occasionally causes sporadic smallpox-like disease (human monkeypox) in humans. The laboratories in the USA and the USSR that provided diagnostic facilities for WHO throughout the eradication campaign maintain their capabilities. Special measures have been taken to destroy stocks of variola virus in all but a very small number of laboratories, in order to minimize the risk of escape of the virus from the laboratory. WHO has established a large reserve stock of freeze-dried smallpox vaccine located in three strategic places (Geneva, New Delhi, Toronto), and many national governments have established their own reserves.

The last case of endemic smallpox occurred in Malaysia in the 1950's (Figure 1 and 2). Prior to that time specimens for smallpox diagnosis were not uncommonly sent to hospitals, medical schools, or the Institute for Medical Research. Following common virological practice, aliquots of

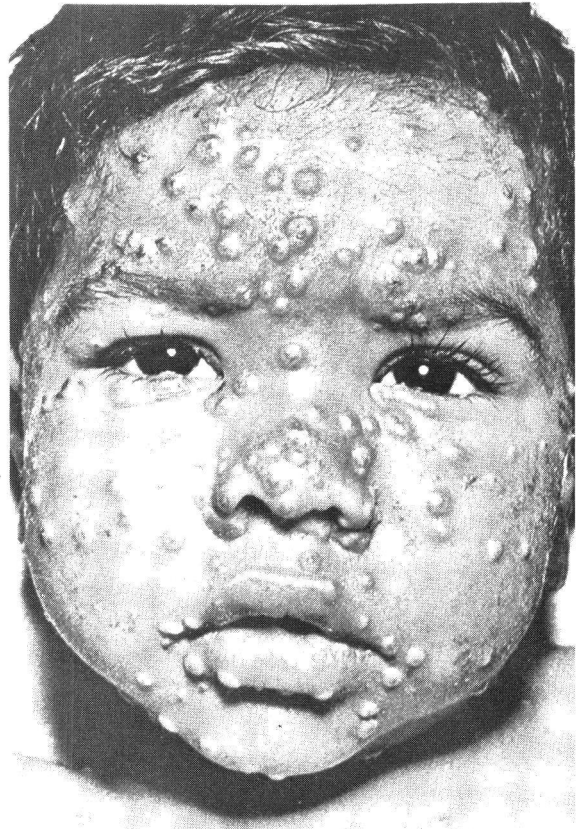

Fig. 1. A young boy with typical smallpox lesions on the face.

some of these samples or virus recovered from them might have been put in the deep-freeze units in such laboratories for future reference. Some of these specimens may remain there, long since forgotten. Such material could be dangerous, and might at some future time constitute a source for further cases of human smallpox. National health authorities have been concerned about this possibility and have already collaborated with WHO in a survey designed to identify laboratories that were retaining variola virus. However, we believe that it would be wise for the directors of all laboratories where smallpox diagnosis was ever conducted once more to examine their deep-freeze storage cabinets for any such forgotten material and incinerate any ampoules that may contain variola virus or are not properly labelled.



**Fig. 2. Typical smallpox lesions on the dorsum of the hand and wrist.**

The other way in which doctors in Malaysia can help with the global insurance against any possible recurrence of smallpox would be for them to be alert for any suspicious human case and obtain material for laboratory study, and to collect specimens from any wild animals found to have a pox-like infection. All such specimens should be sent to WHO, Geneva.

We believe that the world is now free of smallpox, forever, but the price of liberty is eternal vigilance, and against this disease it is the doctors who need to maintain this vigilance.