

# TEMPORARY CARDIAC PACING IN THE CORONARY CARE UNIT

W.H. NG, ZULKIFLI AHMAD & SAMUEL ONG

## INTRODUCTION

TEMPORARY cardiac pacing is an established method of therapy in the emergency control of life threatening arrhythmias or their precursors. Although indications vary, the primary aim is to restore regular rhythm and to improve the cardiac output. In situations where arrhythmias are due to drugs or electrolyte imbalance, temporary pacing may be life saving until the underlying pathology is corrected.

Heart blocks complicating acute myocardial infarction comprise up to 90% of all patients on short term pacing. Second degree atrio-ventricular (AV) block occurs in 2% — 10% and complete heart block in 1.8% — 8% of all patients with acute myocardial infarction (Hurwitz and Eliot, 1964; Meltzer and Kitchell, 1966; Julian *et al.*, 1964). While the incidence of advanced AV block is higher in inferior (27% — 33%) than anterior infarction (5% — 7%), the mortality is higher in anterior (75%) than inferior (20%) infarctions (Norris, 1969; Schlinger *et al.*, 1970).

More coronary care units providing continous electrocardiographic monitoring have been established in this country. This would increase the recognition of various arrhythmias that arise from myocardial infarction and other cardiac conditions. Temporary, and later, permanent cardiac pacing offered in the management of such patients can be expected to increase.

This report of 6 cases describes patients who had successful temporary cardiac pacing. They illustrate the types of cases seen in the Coronary

Care Unit, General Hospital, Kuala Lumpur. Indications for their pacing are discussed.

## CASE 1

C.W., a 51 years old Chinese labourer, was admitted one day after he developed chest pain. Physical examination was normal and electrocardiogram (ECG) showed a recent inferior infarction. Three days after admission he developed first degree heart block. The next day he became hypotensive (Blood pressure 80/60 mm. of mercury) and was in early cardiac failure. Electrocardiogram now showed second degree heart block (mobitz type II) with a ventricular rate of 42 — 50 per minute (Fig. 1). A temporary transvenous endocardial pacemaker was inserted and paced on demand at 80 per minute. The blood pressure improved and cardiac failure subsided. Patient was pacemaker dependent for the next four days. Rehabilitation was well tolerated and the pacemaker was removed one week later. The electrocardiogram on discharge showed no conduction defects.

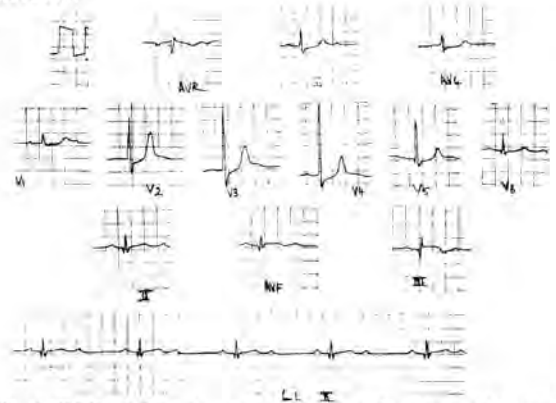


Fig. 1. ECG of Case 1: Acute inferior infarction with second degree (mobitz type II) AV Block

## Comments

Second degree heart block with bradycardia caused hypotension and early cardiac failure in this patient with an inferior infarction. Artificial pacing contributed in correcting these complications.

Department of Medicine, University Kebangsaan Malaysia.

W.H. NG, M.R.C.P. (U.K.)

Lecturer,

ZULKIFLI AHMAD, M.R.C.P. (U.K.)

Head & Associate Professor.

SAMUEL ONG, M.B.B.S. (MAL.)

Trainee Lecturer

### CASE 2

Y.K.T., a 35 years old Chinese teacher, was admitted four hours after he developed chest pain. Physical examination was unremarkable and electrocardiogram showed an acute inferior infarction. With no complications and recurrence of symptoms he was mobilised on the third day. On the fourth day first degree heart block was recorded which rapidly progressed to complete heart block with a ventricular rate of 40 — 50 per minute. Atropine given intravenously did not produce an appreciable increase in heart rate. A temporary transvenous endocardial pacemaker was inserted and paced on demand at 70 per minute. He remained pacemaker dependent for three days after which he reverted to sinus rhythm. The pacemaker was removed several days later with no recurrence of AV block.

### Comments

This patient with inferior infarction rapidly developed complete heart block on the fourth day. Bradycardia, not responsive to atropine, and his age were the indications for pacing. This provided a satisfactory heart rate while awaiting spontaneous recovery.

### CASE 3

B.M., a 53 years old Malay clerk, was admitted two hours after he developed severe chest pain. On admission he was in cardiogenic shock with a blood pressure of 80/50 mm. of mercury and in cardiac failure. Electrocardiogram showed acute inferior infarction and complete heart block with ventricular rate of 42 beats per minute (Fig. 2). A temporary transvenous endocardial pacemaker was inserted and paced on demand at 80 per minute. Immediate blood pressure response was noticed and stabilised at 130/80 mm. of mercury. Cardiac failure subsided over the following days. He remained pacemaker dependent for the next four days and mobilization was commenced on the fifth day. The pacemaker was left in situ for five days after that before removal with no further recurrence of heart block.

### Comments

Complete heart block arising from acute inferior infarction produced cardiogenic shock and cardiac failure in this patient. Correction of the bradycardia by artificial pacing directly contributed to his subsequent clinical improvement.

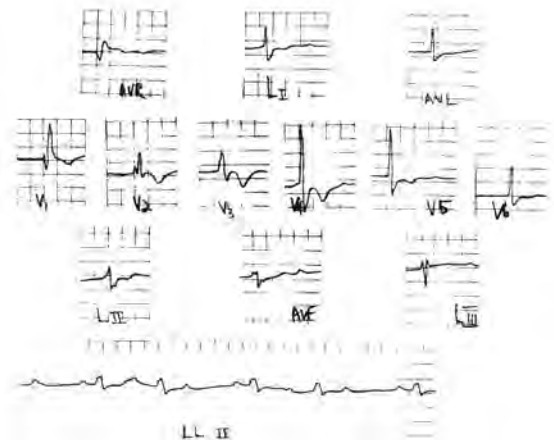


Fig. 2. ECG of Case 3: Acute inferior infarction with complete Heart Block.

### CASE 4

L.W.C., a 56 years old Chinese tailor, was admitted two days after he developed chest pain and breathlessness. On admission he was hypotensive (Blood pressure 80/50 mm. mercury) and in gross cardiac failure. Electrocardiogram on admission revealed a fresh antero-septal infarction, right bundle branch block and left anterior hemiblock (Fig. 3). An emergency temporary transvenous endocardial pacemaker was inserted and therapy for congestive cardiac failure instituted with digoxin and diuretics. The cardiac failure resolved over the next three days and the blood pressure stabilised at 140/80 mm. of mercury. Mobilization was then commenced with no untoward consequences. Continuous rhythm monitoring did not show a progression to more advanced AV block. The pacemaker was removed seven days later and the patient discharged on his eighteenth hospital day. On last review eight months later, he remained well and electrocardiogram showed an old antero-septal infarction with left anterior hemiblock.

### Comments

With this patient a prophylactic pacemaker was inserted in anticipation of a progression to complete heart block. Digoxin could also be used with greater confidence with a pacemaker in situ.

### CASE 5

G.R., a 45 years old Indian barber, was admitted with an extensive anterior infarction complicated by cardiac failure. Several hours after

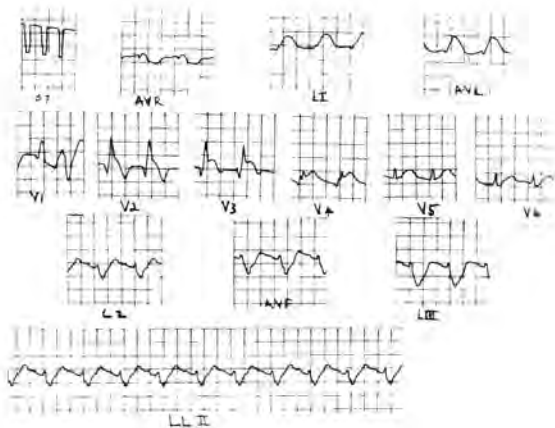


Fig. 3. ECG of Case 4: Acute antero-septal infarction, right bundle branch block and left anterior hemiblock.

admission he developed complete heart block with a ventricular rate of 60 per minute. A transvenous endocardial pacemaker was inserted and paced on demand at 80 per minute. He remained pacemaker dependent for one week during which time mobilization commenced with no complications. On removal of the pacemaker ten days after admission the cardiac failure had subsided and he remained in sinus rhythm on discharge.

#### Comments

Complete heart block and cardiac failure arising from an extensive anterior infarction were the indications for pacing. Despite the poor prognosis in such patients artificial pacing contributed in his eventual recovery.

#### CASE 6

C.Y., a 78 years old Chinese man had been on treatment for hypertension and cardiac failure for several years. He was admitted one day after he developed severe dyspnoea. Several hours prior to admission he was seen and treated by a doctor with intravenous drugs. On admission he was in pulmonary oedema and the electrocardiogram showed complete atrio-ventricular dissociation, complete right bundle branch block, ST and T wave changes but no evidence of an acute infarction (Fig. 4). An emergency transvenous endocardial pacemaker was inserted and paced at 70 per minute and cardiac failure was treated with diuretics alone. From the history digoxin toxicity was suspected and this was later confirmed by plasma digoxin assay of blood sample obtained 6

hours after the intravenous injections were given. It was 3.7 ng/ml. (Normal 1 — 2 ng/ml). He was pacemaker dependent for four days during which time the cardiac failure improved. On reversion to sinus rhythm a repeat digoxin level was 1.4 ng/ml.

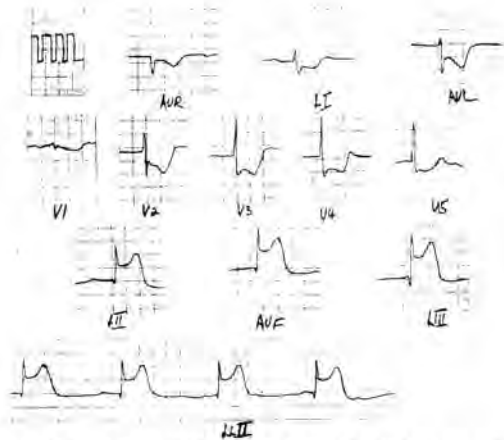


Fig. 4. ECG of Case 6: Complete heart block, but no evidence of acute infarction.

#### Comments

This patient had complete heart block with no obvious cause on admission. It was later proven to be due to digoxin toxicity. Artificial pacing provided improvement in his condition and also maintained a regular rhythm and rate till this toxic effect of digoxin was corrected.

#### DISCUSSION

Patients who develop ventricular conduction defects in acute myocardial infarction face a higher mortality risk. The mortality is higher with anterior than inferior infarctions (Norris, 1969; Schlinger *et al.*, 1970). With anterior infarctions a greater amount of myocardial damage occurs. The block arising is usually sudden in onset, the ventricular complexes are wide and the block occurs below the His bundle. Most of these patients develop severe cardiac failure and circulatory collapse. In contrast, in inferior infarctions, the myocardial damage is smaller in extent with narrow ventricular complexes, and the block lying proximal to the bundle of His. The onset of the block tends to be gradual and lasts a few days.

Irrespective of the site of infarction, temporary cardiac pacing serves to overcome the genesis of bradycardia which results from advanced block. It

has been established that certain conduction defects progress to complete heart block or develop into sudden cardiac asystole. They include Mobitz type II AV block, bifascicular blocks, and alternating right and left bundle branch blocks. The importance of correcting bradycardia in myocardial infarction is to prevent a fall in cardiac output and blood pressure. This was shown by Mather *et al.* (1971), who described a mortality of 49% in patients with a systolic blood pressure of less than 100 mm of Mercury. A higher incidence of ventricular tachycardia, ventricular fibrillation and premature ventricular contractions occur with myocardial infarction complicated by bradycardia (Lown *et al.*, 1967; Adqey *et al.*, 1968). This suggests that bradycardia maybe a precursor to the arrhythmias and an important factor in the early high mortality. Furthermore, the ectopics are abolished once the heart rate is increased.

Treatment of tachyarrhythmias in myocardial infarction by pacing is more infrequent and less well understood. If arising secondarily to bradycardia, they are usually eliminated by correction of the bradycardia. Tachycardia maybe suppressed by pacing with overriding or in combination with anti-arrhythmic drugs.

Although pacemakers are widely used, it is still difficult to assess its effect on mortality rates. Christiansen *et al.* (1973) and Freidberg *et al.* (1968), in their reports stated that the usefulness and benefits of temporary pacing are negligible with no significant reduction in the mortality rates when compared with drug therapy. In contrast, Scott *et al.* (1967), in a comparative study of pacemakers and drug therapy found a mortality rate of 61% among patients treated by medications and 37% among those who had temporary pacemakers. Frequency of anterior and inferior infarctions were however not stated. Some authors would even take the position that to withhold pacing is morally wrong (McNally and Benchimol, 1968). When cases are individually considered, it is clear that many patients benefit and are saved by temporary pacing even though some figures may not show it. Mortality should therefore take into account recognised risk factors in addition to advanced AV Block. They include site of infarction, extent of myocardial necrosis, cardiogenic shock, cardiac failure, syncope and QRS prolongation (Friedberg *et al.*, 1969; Norris, 1969).

Permanent pacing may also be of considerable benefit after myocardial infarction. Alone or in combination with anti-arrhythmic drugs, permanent pacing is useful in the management of resistant arrhythmias. It is also advocated in patients who have a high risk of sudden death after infarction. Such patients are identified based on the electrocardiogram at the time of infarction. They include patients who develop Mobitz type II AV Block, complete heart block and multiple fascicular blocks. Waugh *et al.* (1973) and Lichstein *et al.* (1973) recommend permanent pacing in such patients, and Atkins *et al.* (1973) demonstrated a significant decrease in the incidence of sudden death of such patients offered permanent pacing.

Temporary pacing has its most frequent application in the management of conduction defects arising from myocardial infarction (Cases 1 — 5). Case 6 illustrates a less frequent situation where digoxin toxicity produced complete heart block and temporary pacing sustained haemodynamic stability until the toxic effect of digoxin was corrected. In addition to these applications, Sowton *et al.* (1967) demonstrated temporary atrial pacing as a stress test for the diagnosis of angina pectoris. Similarly, rapid atrial stimulation is used as a provocative test in the assessment of sinoatrial node automaticity and conduction in patients with the Sick Sinus Syndrome (Narula *et al.*, 1972). Atrial pacing with His bundle electrography has a diagnostic application in the functional assessment of the cardiac conduction system (Damato *et al.*, 1969).

## SUMMARY

Temporary cardiac pacing has a definite role in the management of cardiac arrhythmias. 6 patients are described illustrating the types of cases seen in the coronary care who benefitted from pacing. Indications and role of temporary cardiac pacing are discussed.

## ACKNOWLEDGEMENT

We wish to thank Sister Kamariah and the Nursing staff of the Coronary Care Unit, General Hospital, Kuala Lumpur for their assistance during pacemaker insertion and care of these patients.

## REFERENCES

- Adgey, A.A.J., Geddes, J.S., Mulholland, H.C., *et al.* (1968), Incidence, significance and management of early bradyarrhythmias complicating acute myocardial infarction, *Lancet*, **11**, 1097 — 1101.
- Atkins, J.M., Leshin, S.J., Blomgust, G., *et al.* (1973), Ventricular conduction blocks and sudden death in acute myocardial infarction, *N. Engl. J. Med.*, **288**, 281 — 284.
- Christiansen, J.B., Haghfelt, T., and Amtorp, O. (1973), Complete heart block in acute myocardial infarction: Drug therapy, *Am. Heart J.*, **85**, 162 — 166.
- Damato, A.N., Lam, S.H., Patton, R.D., *et al.* (1969), A study of atrioventricular conduction in man using premature atrial stimulation and His bundle recordings, *Circulation*, **40**, 61 — 69.
- Friedberg, C.K., Cohen, H., and Donoso, B. (1968), Advanced heart block as a complication of acute myocardial infarction: Role of pacemaker therapy, *Prog. Cardiovasc. Dis.*, **10**, 466 — 481.
- Hurwitz, M., Eliot, R.S. (1964), Arrhythmias in acute myocardial infarction, *Dis. Chest*, **45**, 616 — 621.
- Julian, D.T., Valentine, P.A., Miller, G.G. (1964), Disturbances of rate, rhythm and conduction in acute myocardial infarction, *Am. J. Med.*, **37**, 915 — 927.
- Lichstein, E., Gupta, P.K., Chadda, K.D., *et al.* (1973), Findings of prognostic value in patients with incomplete bilateral branch block complicating acute myocardial infarction, *Am. J. Cardiol.*, **32**, 913 — 918.
- Lown, B., Fakhro, A.M., Hood, W.B., and Thorn, G.W. (1967), The Coronary Care Unit: New perspectives and directions, *J.A.M.A.*, **199**, 188 — 198.
- Mather, H.G., Pearson, N.G., Read, K.L.Q. *et al.* (1971), Acute myocardial infarction: Home and hospital treatment, *Br. Med. J.*, **3**, 334 — 338.
- McNally, E.M., Ben chimol, A. (1968), Medical and physiological considerations in the use of artificial pacing, *Am. Heart J.*, **75**, 679 — 695.
- Meltzer, L.E., Kitchell, J.B. (1966), The incidence of arrhythmias associated with acute myocardial infarction, *Prog. Cardiovasc. Dis.*, **9**, 50 — 63.
- Narula, O.S., Samet, P., and Javier, R.P. (1972), Significance of the sinus node recovery time, *Circulation*, **45**, 140 — 158.
- Norris, R.M. (1969), Heart block in posterior and anterior myocardial infarction, *Brit. Heart J.*, **31**, 352 — 356.
- Schlinger, J., Iraj, I., Edson, J.N. (1970), Cardiac pacing in acute myocardial infarction complicated by complete heart block, *Am. Heart J.*, **80**, 116 — 124.
- Scott, M.E., Geddes, I.S., Patterson, G.C., *et al.* (1967), Management of complete heart block complicating acute myocardial infarction, *Lancet*, **11**, 1382 — 1385.
- Sowton, E., Balcon, R., Gross, D., and Frick, M.H. (1967), Measurement of the angina threshold using atrial pacing: A new technique for the study of angina pectoris, *Cardiovasc. Res.*, **1**, 301 — 307.
- Waugh, R.A., Wagner, G.S., Harvey, T.L., *et al.* (1973), Immediate and remote prognostic significance of fascicular block during acute myocardial infarction, *Circulation*, **47**, 765 — 775.