

THE KARMAN CURETTE FOR GYNAECOLOGICAL DIAGNOSTIC CURETTAGE (A Preliminary Report)

PANIR CHELVAM

PURAVIAPPAN

T.A. SINNATHURAY

UTERINE aspiration is a valuable therapeutic and diagnostic technique. This suction technique has been employed successfully in termination of early pregnancy (menstrual regulation) and has gained world wide popularity (Population Report, No. 4, May 1974). The menstrual regulation equipment has been used to treat aseptic incomplete abortions (Faton 1969; Filshie et al., 1973; Eaton Marshall, 1971). Some have even used the equipment to evacuate uterus with hydatidiform mole in early gestation of not more than 8 weeks (Eaton, 1969, Petetz et al., 1967).

The introduction of uterine aspiration for diagnostic purposes in the non-pregnant uterus was inevitable following the favourable results of its use in the pregnant uterus. This was the result of the search for a simpler, cheaper and time-saving method to perform diagnostic curettage as this procedure is indispensable in gynaecology.

Jensen (1970); Holt (1970), and Bjerre et al., (1971) employed aspiration techniques for diagnostic curettage and obtained favourable results. These workers used the Vabra aspirator consisting of a disposable 3mm stainless steel cannula and collecting system which attaches to the

suction source. Poyas (1971) performed suction diagnostic curettage using stainless steel cannula currettes of his own design. Muenzer (1974) used medical grade silicone rubber tube (silastic) for suction curettage.

We report a small series of patients in whom diagnostic suction curettage was performed using the Karman curette equipment. The Karman cannula developed by Harvey Karman in the late 1960's (Karman et al., 1973) has been used successfully and most widely for menstrual regulation. Filshie et al., (1973) used the 8mm Karman cannula for the evacuation of uterus in incomplete abortions. His suction source however was a modified Malmstrom vacuum pump. We have extended the use of the Karman cannula into the diagnostic field using as our suction source, the modified Karman syringe.

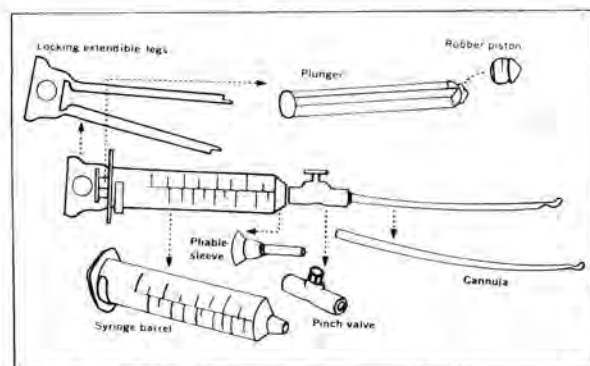


Fig. 1 The Karman aspiration set-up used for gynaecological diagnostic curettage.

METHODS AND MATERIAL

Patients

Fifty one patients admitted into the University Hospital in the months of August, September and October, 1974, requiring diagnostic curettage formed the basis of this study. The age of these patients ranged from 21 years (youngest) to 58 years (oldest). Of the 51 patients, 22 were Chinese, 17 Indians and 12 Malays.

Department of Obstetrics and Gynaecology,
University of Malaya, Kuala Lumpur.

*PANIR CHELVAM M.R.C.P.
Formerly Resident House Officer,

†PURAVIAPPAN F.R.C.S., M.R.C.O.G.
Formerly Lecturer,

Department of Obstetrics and Gynaecology, Faculty of Medicine,
University of Malaya, Kuala Lumpur.

*T.A. SINNATHURAY A.M., M.B., B.S. (Malaya),
M.D. (Singapore), F.R.C.S. (Edin.),
F.R.C.S. (Glasg.), F.R.C.O.G.,
F.I.C.S., F.A.C.S.,
Professor,

*Present address: Department of Medicine,
Universiti Kebangsaan Malaysia,
Kuala Lumpur.

†Present address: Klinik Puravi, 42 Jalan Nanas, Kelang.

The pre-curettage clinical diagnosis of the patients were as follows:-

Infertility	25 cases
Dysfunctional uterine bleeding	12 cases
Perimenopausal bleeding	4 cases

For the 16 cases diagnosed as dysfunctional uterine bleeding and perimenopausal bleeding, only diagnostic curettage was performed. For the infertility cases, a tubal insufflation was performed prior to the diagnostic curettage.

BASIC EQUIPMENT

The following instruments were used in the procedure:

- 1) 50 c.c. aspiration syringe.
- 2) Karman cannulas: 4mm, 5mm, 6mm, 8mm.
- 3) Cervical stabilizer (Vorsellum).
- 4) Small ovum forceps.
- 5) Bivalve speculum.

Other basic equipment also included the pre-medication drugs (Pethidine and Sparine), anti-septics and sterile gauze pads.

PROCEDURE

The patient was admitted into the hospital either the evening prior to the procedure or early morning on the same day. A history and physical examination was performed to exclude any obvious contra-indication to this minor surgical procedure. An intra-muscular injection of 100 mg. pethidine and 50 mg. sparine was given to the patient about 30 to 45 minutes prior to the procedure.

With the patient in the dorsal lithotomy position, a bimanual vaginal examination was performed. A bi-valve speculum was inserted and cervix exposed. The syringe was evacuated (i.e. vacuum created) before attaching it to the cannula. With the pinch valve open, the plunger was pushed forwards completely. Then the pinch valve was closed. The syringe body was then grasped firmly in one hand and the plunger pulled out with the other, until the legs of the handle snap out and lock the plunger firmly in its fully extended position.

The Karman Cannula was then firmly pushed into the end of the rubber liner so that it held securely.

The anterior lip of the cervix was grasped with a toothed vorsellum to stabilise the cervix. The external os was then cleaned with antiseptic. The cannula, held with a sterile forceps, was introduced through the external cervical os. Occasionally, resistance was met at the internal os. In these cases, the cannula was grasped near the tip with the sterile forceps and light pressure applied. The cannula was passed into the uterine cavity until the tip was felt to gently touch the fundus. The depth of the uterine cavity was then estimated.

With the syringe securely attached to the cannula, the pinch valve was released to begin aspiration. The cannula was grasped about 8 cm from the cervix and rotated gently through 180 degrees. At the same time the cannula was gently shifted in and out, in a curette-like motion. Endometrial tissue was seen to flow into the syringe via the cannula. When all four quadrants of the uterine wall were thus curetted, or when sufficient endometrial tissue was obtained, the curettage was stopped. Before the cannula was removed from the uterine cavity, the pinch valve was closed. The cannula still secured to the aspirator, was gently removed. The tip of the Karman cannula was then inserted into a specimen bottle containing the preservative (formalin) and then the pinch valve was released, so that there was a suction of the solution into the syringe via the cannula, taking with it the pieces of endometrial tissue from within the cannula. The cannula was then detached from the aspiration syringe and the contents of the syringe was transferred into the specimen bottle. The specimen so collected was examined and sent for histopathology.

Occasionally, if we felt that the initial curettage was inadequate, re-aspiration was accomplished with a cannula one size larger than the one used in the original procedure.

After the procedure, the cervix and uterus was examined for any bleeding and the patient sent back to the ward for hourly observations for 4 to 6 hours. The patient was discharged the same evening. She was advised that if there was any evidence of fever or haemorrhage, to return immediately to the hospital.

RESULTS

1) Time

Besides the premedication used, no additional anaesthesia was required. The average time taken per person was about 12.0 minutes. However for

the 16 patients who only had a curettage performed, the average time was 11 minutes. The other 35 patients who had a tubal insufflation performed besides the curettage, the average time taken was 14 minutes per person. Hospital stay for each patient was not more than one complete day.

2) Pain

During the procedure most of the patients experienced some form of pain. This pain was noticed to occur at two specific times of the procedure:

- a) at the time of the introduction of the cannula through the internal os. The pain was especially evident when resistance was met at the internal os and light pressure had to be exerted to push the cannula in;
- b) at the time when the tip of the cannula hit the fundus of the uterus. This however occurred less frequently.

The intensity of the pain was mild to moderate and the pain was described by most as similar to mild "period pain". Post-operatively, pain still persisted in some patients but we did not have to use more powerful analgesics than paracetamol to relieve the discomfort.

3) Adequacy of specimen

The endometrial curettings obtained in all the 51 cases appeared to be adequate for histological analysis. The pathologists had no difficulty in using the specimen. The endometrial fragments, however, were noticed to be a little smaller than the ones obtained from conventional dilatation and curettage.

4) Complications

The anticipated complications include faintness, syncopal attacks, bleeding, cervical trauma and infection. In the 51 patients in our series, we did not encounter any such complication. Except for some uterine cramps and pain during the procedure, we did not have any patient who went into neurogenic shock or who had excessive bleeding. Post-operatively, all patients remained afebrile. The follow-up of these patients also revealed no further complications.

DISCUSSION

Uterine aspiration with Karmen curette, as a diagnostic tool, has been found to be safe, quick,

effective and potentially advantageous as an out-patient procedure (Bjerre et al., 1971; Holt, 1970; Jensen, 1970; Poyas, 1971).

From our initial small series of patients, we confirm that it is a relatively safe procedure. Firstly, the risks of general anaesthesia are absent. Also the use of the Karman cannula, a flexible plastic instrument, avoids the introduction of metal instruments into the uterus. Hence the Karman flexible plastic cannula minimises the risk of uterine perforation.

The possible dangers of diagnostic curettage using the Karman cannula, however, are few. The tip of the Karman cannula may break-off and become detached within the uterus. Incidences quoted are 1:5,000 (when the Karman cannula is used for menstrual regulation). In all the reported cases, the tip is expelled from the uterine cavity within 72 hours. This rare complication is avoided if the tip is examined carefully (prior to insertion into uterine cavity) to make sure that it is in good condition and shows no sign of breaking off.

Uterine infection may follow the procedure. If the no-touch technique is employed for the cannula insertion, and the instruments are sterile, then the risks of infection are minimal. The operator need not wear a special operating gown, mask or cap; but the use of sterile gloves are recommended. It is wise to swab the cervix with a mild aqueous antiseptic prior to cannula insertion. Uterine infection was not a complication in our series.

Immediate complications of shock, haemorrhage, and severe cramps are not commonly seen, and were absent in our series of patients.

The average time taken per procedure was 12 minutes. This included the time from when the patient is brought into the theatre to the time she leaves. The actual procedure of curettage itself took only about 1 to 2 minutes per patient. Time is saved not only in avoiding the use of anaesthesia but also in sterilising the equipment used. Also hospital stay is minimised to 1 day. The wider application of this procedure, using the Karman cannula, can help to popularise it as an "office" procedure, thus saving time and money for the patients. Poyas (1971) using stainless steel

cannula curette (of his own design) performed 334 curettage and recommends the use of this suction curettage as an "office" procedure.

It may be a little premature, at this stage, to conclude that the Karman cannula is completely effective in obtaining adequate amounts of endometrial tissue for diagnostic histopathology. Although in all our cases, we obtained adequate samples, we had not designed this study so that we could compare the histological findings with those found with the conventional dilatation and curettage or at hysterectomy. However, others who have used metal curettes found that the diagnosis based on uterine aspiration and conventional curettage were identical for 97.8 per cent of the specimen. Uterine aspiration was performed in a total of 713 patients, altogether by Bjerre, et al., (1971); Holt, (1970) and Jenson (1970). Of these 713 patients, inadequate endometrial tissue for diagnosis was obtained only in 14 uterine aspirations (2.0%). A discrepancy in the findings by uterine aspiration and by subsequent sharp curettage was noted in 10 patients (1.4%). Muenzer, R W, et al., (1974) performed uterine aspiration (using silastic cannula) in 500 women who subsequently had either a sharp curettage or hysterectomy. They found in 84.4 percent of the cases, the diagnosis were in agreement. Isaacs et al., (1974), having detected 7 patients with endometrial carcinoma out of the 346 patients who had uterine aspiration, felt that this technique of uterine aspiration may serve as an additional screening technique for the detection of endometrial carcinoma, especially in the high risk patient.

In conclusion, we feel that the Karman Cannula suction-curettage can be effectively used for gynaecological diagnostic curettage. It is relatively safe — no anaesthesia is necessary except for premedication. The procedure is technically simple and quick. It saves time, money and hospital space, provided there is a careful selection of the cases.

SUMMARY

The Karman cannula with its modified Karman syringe was used for gynaecological diagnostic curettage in fifty-one patients. The endometrial curettings obtained in all the

patients appeared adequate for histological assessment. No complications were encountered and the average time taken per procedure was 12 minutes. Our preliminary conclusions are that the use of the Karman Curette equipment for gynaecological diagnostic curettage is a relatively safe, simple and short procedure. It is felt that this gynaecological diagnostic procedure could be safely undertaken as an outpatient or "office" procedure.

ACKNOWLEDGEMENT:

The authors would like to acknowledge the late Associate Professor I.S. Puvan for the help he rendered in this project.

REFERENCES

- Bjerre, B.A., Gardmark, S.A. Sjoberg, N.O.J.A. (1971), Aspiration curettage: a new diagnostic method. *J. Reprod. Med.*, 7, 221 — 223
- Eaton, C.J. (1969), Uterine aspiration for evacuation of the pregnant uterus. *JAMA*, 207, 1887 — 1889.
- Filshie, G.M., Ahluwalia, J., Beard, R.W. (1973), Portable Karman curette equipment in management of incomplete abortions. *Lancet*, 2, 1114 — 1116.
- Holt, E.M. (1970), Outpatient diagnostic curettage. *J. Obstet. Gynecol. Br. Commonw.*, 77, 1043 — 1046.
- Isaacs, J.H., Wilhoie, R.W. (1974), Aspiration cytology of the endometrium: office and hospital sampling procedure. *Am. J. Obstet. Gynecol.*, 118, 679 — 687.
- Jensen, J.G. (1970), Vacuum curettage: outpatient curettage without anaesthesia. A report of 350 cases. *Dan. Med. Bull.*, 17, 199 — 202.
- Karman, H., Potts, M. (1972), Very early abortion using syringe as vacuum source. *Lancet*, 1, 1051 — 1052
- Marshall, B.R. (1971), Emergency room vacuum curettage for incomplete abortions. *J. Reprod. Med.*, 6, 117 — 178.
- Muenzer, R.W., Girgis, Z.A., Rigal, R.D., et al. (1974), An acceptable yearly screening device for endometrial carcinoma. *Am. J. Obstet. Gynecol.*, 119, 31 — 38.
- Peretz, A., Grunstein, S., Brandes, J.M., et al. (1967), Evacuation of the gravid uterus by negative pressure (suction evacuation). *Am. J. Obstet. Gynecol.*, 98, 18 — 22.
- Population Report. (May, 1974), *Pregnancy termination Series, F, No. 4.*
- Poyas, J.L. (1971), Cannula curette for office diagnostic D & C. *Obstet. Gynecol.*, 35, 783 — 785.