

Torsion of the testes: a review of 24 cases

by *Wong Twee Juat*
Medical Officer

Ong Tat Hin
Associate Professor

Kylasa Somasundaram
Professor and Head of Department

Department of Surgery
University Hospital, Kuala Lumpur

Introduction

TORSION OF the testis, first described by Delasiauve in 1840, remains an important clinical entity. The condition is frequently misdiagnosed and total haemorrhagic infarction of the affected testis is often the result. Prompt recognition and early operative intervention can consistently save the affected testis.

Herein, we review 24 cases of torsion in an attempt to bring this relatively common and serious surgical emergency into the general awareness of our doctors.

Methods and material

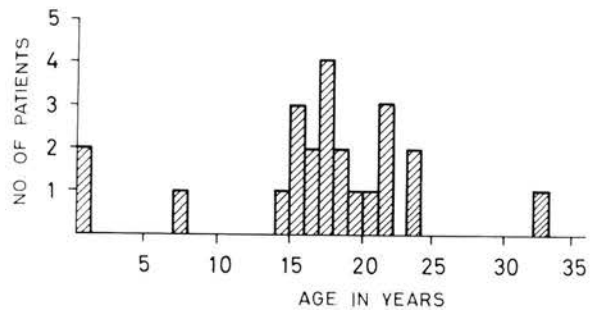
We have examined the records of 24 cases of surgically confirmed torsion of the testis in the University Hospital, Kuala Lumpur, between November 1967 and June 1976. There were 12 Indians, 11 Chinese and 1 Malay.

The ages of the 24 patients ranged from 3 weeks to 32 years, with a mean of 16.8 years (See Fig. 1). We had 2 patients under the age of 1 and 16.7% of our patients occur in the pubertal age group (11-16) years.

There were 12 cases of right sided torsion and 12 cases of left sided torsion.

Diagnosis

Scrotal pain was the cardinal symptom (see Table I) and it occurred in all patients except in the two infants. The pain was typically sudden in onset and severe in degree. Occasionally, it was



AGE DISTRIBUTION OF TORSION OF THE TESTIS IN 24 PATIENTS.

Figure 1
Age Distribution of Torsion of the Testis in 24 patients.

Table I
Clinical features in 24 cases of torsion of the testis

Symptom	No.	(%) of cases
Pain		
severe scrotal	18	(75%)
mild scrotal	2	(8.1%)
confined to groin	2	(8.1%)
Vomiting	2	(8.1%)
Nausea	3	(12.5%)
Fever (<99°F/37.2°C)	5	(28.0%)
Urinary symptoms	0	(0%)
Onset during sleep	7	(29.8%)
Previous attacks	10	(41.6%)

referred to the lower abdominal quadrant as was seen in two patients. One patient fainted from the severe pain. Nausea and vomiting occurred in two patients.

In seven patients, the torsion occurred during sleep and in one patient while resting after lunch. Only in one patient was there any suggestion of physical strain or trauma, he was blowing his nose!

Ten patients had previous similar, perhaps milder, attacks of pain in the last three years and one patient had intermittent attacks for the last six years. Another patient, operated in another hospital for torsion of the testis where an orchidectomy was done, came to us with similar acute pain in the other testis one year later.

Urinary symptoms were absent in all our patients. Five patients had low grade fever at the time of admission. Urinalysis was normal in 21 patients. Of the three patients with abnormal urinalysis, two had persistent pain for over one week. Total white blood cell count was done in 19 patients and only eight patients had white cell count over 11,000 cells per cubic millimetre.

The most consistent physical finding was an enlarged tender mass either in the scrotum or in the superficial inguinal pouch. In eight patients, the scrotum of the affected side was empty but only one of them gave a history of an inguinal swelling with an empty scrotum prior the onset of pain. In two patients, the testis on the affected side were found to have a horizontal lie.

The most common error in diagnosis was acute epididymo-orchitis. This mistake occurred in seven patients and led to a delay in treatment. In this group, the correct diagnosis was reached only after the patients returned a second time and in one patient, after a third time. This invariably led to loss of the testes.

All 24 patients underwent exploration. The preoperative diagnosis were correct in 91.6% of the patients. The salvage rate was 36.4% or 9 testes. Of these, 6 patients were operated within 8 hours after the onset of symptoms and in three, after 72 hours.

In two patients, the testes were found to have reduced spontaneously at operation with evidence of congestion and odema of the testes and spermatic cord still present. One patient had chronic intermittent pain on both sides for 6 years and acute scrotal pain on the left side for 1 week. Both testes were salvaged at operation.

No consistent predisposing abnormality was found. The well known "bell clapper" type of testes was seen only in 4 patients. The degree of torsion varied from 90° to 720° but the extent and the direction of torsion were poorly documented in the majority of the patients. Secondary hydrocoele was noted in 5 patients. The fluid was blood stained in 2 patients and both had infarcted testes.

14 patients had orchidectomy for infarcted testes. In one patient, only a wedge biopsy of the infarcted testis was done. Of the 9 patients whose testes were salvaged, bilateral orchidopexy were done only in 5 patients. The other 4 had only the affected side treated.

The average hospital stay was 5.7 days. No serious postoperative complications were noted. Mild wound infection which responded to daily dressing occurred in 5 patients. At follow up, all the patients were noted to be well.

Discussion

Torsion of the testis, more accurately called torsion of the spermatic cord (Campbell and Harrison, 1970) is an axial rotation of the cord upon itself with occlusion of the blood supply to the testis and the epididymis. This initially occludes the veins causing odema and if the occlusion is allowed to persist, it will lead to total haemorrhagic infarction of the testis. The torsion may occur intravaginally or extravaginally.

The incidence of torsion of the testis is not rare as supported by series reported by Allan and Brown (1966) and Skoglund *et al* (1970). It has been suggested that the incidence in any busy general hospital is about three or four patients a year as in our experience and perhaps even higher if one includes those that escape recognition.

The age distribution is said to be biphasic, peaks occurring in the first year of life and puberty (Skoglund *et al*). However, in our experience, there were only two patients (8.3%) below the age of one and only four patients (16.7%) fell in the prepubertal age group (11-16). Our observation of a wide age distribution in which 79% of the patients occurred in the age group (11-26) emphasises the importance of making an accurate diagnosis based on history and physical findings rather than based on age alone.

The greater length of the left spermatic cord is supposed to be more predisposed to torsion (Parker and Robison, 1971 and Jones, 1970) which again is not so in our series. All our patients had intravaginal torsion of the testis.

The main predisposing factor is said to be abnormal mobility of the spermatic cord, resulting usually from incomplete attachment of the epididymis to the testis (the broad mesorchium type of testis) or the inclusion of the epididymis and a portion of the cord within the tunica vaginalis (the bell clapper defect – see Fig. 2). The latter defect was noted only in four patients. Other factors implied in the aetiology namely a strong cremasteric muscle, faulty attachment of the gubernaculum, a voluminous scrotum and excessive length of the spermatic cord remain speculative and were not seen.

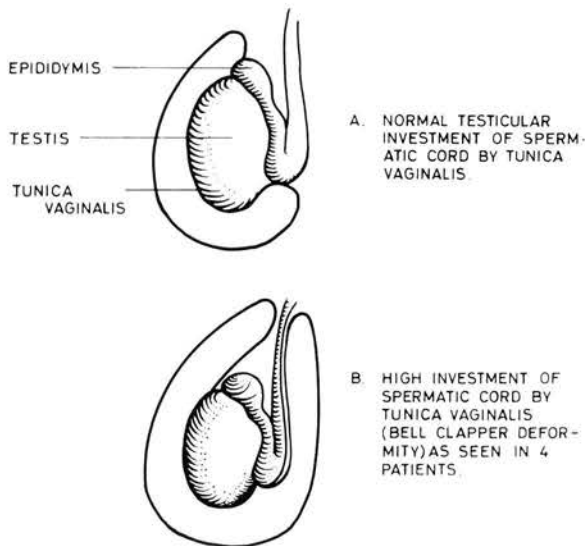


Figure 2

- A. Normal testicular investment of spermatic cord by tunica vaginalis.
- B. High investment of spermatic cord by tunica vaginalis.

The clinical features were characteristic. Torsion was usually heralded by sudden pain in the scrotum. Nausea and vomiting, frequent in other series, were uncommon. A previous history of intermittent scrotal pain was significantly present in ten patients (41.6%) as observed also in reports by Allan and Brown (1966) and Barker and Raper (1964). Some degree of force, whether traumatic or specific body movements or cremasteric contraction, thought to be necessary to produce torsion was only observed in one of our patients whereas 29% of our patients were sleeping or at rest when the torsion occurred.

Acute epididymo-orchitis is the frequent misdiagnosis and the principal cause of delay in appropriate treatment and low salvage rate (Parker and

Robison, 1971). 29% of our patients were so diagnosed initially. The age distribution, the absence of significant urinary symptoms, a previous history of similar pain and a normal urinalysis should alert the doctor against a diagnosis of acute epididymo-orchitis. Moreover, fever is rarely present and if present, usually low grade. A white blood count over 14,000 cells/cu. mm. is unusual.

An interesting physical finding in our series was that in six patients with previously normal scrotal testes, an empty scrotum was noted on the affected side. Torsion of an undescended testis is rare and the above was probably the phenomenon of "testis redux" (Jones, 1970). When a fully descended testis undergoes torsion, the cremasteric reflex pulls it into the superficial inguinal pouch where it becomes fixed by odema and may be mistaken for a strangulated hernia or torsion of an undescended testis. The latter is easily distinguished at operation when a normal length of spermatic cord is found, and the testis, if salvageable, is easily brought into the scrotum on detorsion. In our series, one patient had torsion of an undescended testis. An undescended testis may undergo torsion particularly when an accompanying hernial sac completely invests the cord. However, this was not noted in the patient.

The salvage rate of 39% compares favourably to salvage rates of 20% by Allan and Brown (1966), 10% by Barker and Raper (1964) and 42% by Gartmann (1957) and this depends on the time interval between the onset of symptoms and operative intervention. Barker reported that the testes were saved in 9 of his 14 patients operated within 24 hours. In Gartmann's series, no testes were saved after 12 hours. Skoglund *et al* reported salvage rates as follows – "within 5 hours of onset of symptoms 83%, within 10 hours, 70% and only 20% more than 10 hours". In our series, 80% of the testes operated within 8 hours were saved while 2 testes were salvaged after symptoms have been persisted for more than 72 hours. Hence, as pointed out by Skoglund *et al*, no definite critical time limit can be set since the degree of vascular occlusion may be incomplete.

At operation, two patients were found to have their torsion spontaneously reduced following general anaesthesia. This phenomenon has been well documented. Parker and Robison (1971) reported a 73% of preoperative detorsion after general anaesthesia in acute cases. It has been suggested in these patients that cremasteric muscle spasm or other responses to pain play a role in initiating and maintaining the torsion. These mechanisms were abolished under general anaesthesia.

Sparks (1971) has advocated manipulative reduction (external detorsion) when the patient is first seen in the clinic. It is not a substitute for surgery but an interim measure to avert irreparable damage to the testis while preparations are made for the patients to undergo urgent exploration. Manipulative reduction was attempted unsuccessfully in one patient.

Definite treatment is always immediate surgical exploration. If surgical detorsion is feasible and the testis salvageable, orchidopexy should be performed. The testis is fixed by suturing the tunica albuginea to the parietal tunica. In most cases, orchidectomy may be necessary. Because the predisposing abnormality is frequently bilateral (Campbell and Harrison, 1970), prophylactic orchidopexy of the unaffected side should be carried out. This need is best illustrated by one of our patients who had an orchidectomy only performed in another hospital and one year later, presented to us with similar scrotal pain on the other side. Fortunately, the diagnosis was clear cut then and prompt surgery salvaged his only testis. Finally, should there be any doubt as to the diagnosis one should err on the side of safety and explore the testis than chance the loss of a testis.

Summary

A review of 24 cases of torsion of the testis is presented. The clinical picture, main differential

diagnosis and management are discussed. No new observations were made. Rather, previous observations were re-emphasised. Torsion of the testis is an operative emergency. Only with early diagnosis and prompt surgery can the affected side be saved.

References

- Allan, W.R. and Brown, R.B. (1966) Torsion of Testis and its Appendages. *J. Urology*, **104**, 604-607.
- Barker, K. and Raper, F.P. (1964) Torsion of the Testis. *Brit. J. Urology*, **36**, 35-51.
- Campbell and Harrison (1970) *Urology, Vol. 2*, Third Edition, 1855-1858. W.B. Saunders Company.
- Chapman, R.H. and Walton, A.J. (1972) Torsion of Testis and its Appendages. *Brit. Med. J.*, **1**, 164-166.
- Gartmann, E. (1957) Torsion of Spermatic Cord in Adult Scrotal Testis. *Amer. J. Surg.*, **94**, 787-789.
- Jones, P. (1970) *Clinical Paediatric Surgery, First Edition*, 232-234. Bristol: John Wright & Sons Ltd.
- Moharib, N.H. and Krahn, H.P. (1970) Acute Scrotum in Children with Emphasis on Torsion of Spermatic Cord. *J. Urology*, **104**, 601-603.
- Parker, R.M. and Robison, J.F. (1971) Anatomy and Diagnosis of Torsion of the Testis. *J. Urology*, **106**, 243-247.
- Skoglund, R.W., Mc Roberts, J.W. and Haakon, R. (1970) Torsion of the Spermatic Cord. *J. Urology*, **104**, 604-607.
- Sparks, J.P. (1971) Torsion of Testis. *Ann. Roy. Coll. Surg. Engl.* **49**.