

# Central retinal Artery occlusion following haemorrhage

by *M. Vijendran*

**M.B., D.O., F.R.C.S.E.,**  
Department of Ophthalmology,  
Faculty of Medicine,  
University of Malaya.

and *K. Suppiah*

**M.B., D.O.,**  
Assunta Hospital,  
Petaling Jaya.

## Introduction

OCCLUSION OF the central retinal artery, is usually associated with arteriosclerosis, hypertension, diabetes and giant cell arteritis. Occasionally it may be due to an embolus, lodged at the level of the lamina cribrosa, arising most commonly from the heart or diseased carotid arteries. Rarely central retinal artery occlusion (C.R.A.O.) may be seen in carotid stenosis, migraine, connective tissue disease, polyarteritis, blood dyscrasia or following massive haemorrhage. The clinical picture seen in the fundus is one of retinal infarction with whitening of the retina mainly due to cloudy swelling in the ganglion cells, narrowing of the retinal arteries and a cherry red-spot at the macula. To date, the various therapeutic measures undertaken in the treatment of this condition have brought about little success and vision is invariably lost with this episode.

This paper reports a case of C.R.A.O. due to prolonged repeated hypotensive episodes in a patient following massive blood loss.

## Case Report

T.L.N., 33 year old Chinese male, on 1.7.75 while working in a steel mill caught his right upper limb in a roller machine. He was admitted into hospital in hypovolaemic shock with a BP 70/40, and a pulse rate of 120/min. There was complete loss of skin over the hand and forearm up to the elbow, together with laceration and contusion of the muscles.

Radiological examination revealed no fracture of the forearm bones. The hand showed comminuted fracture of all the phalanges with avulsion of the bones.

Immediate toilet and suture was undertaken and the multiple lacerations were sutured even though the tissue appeared non-viable. He was transfused with 3 pints of blood followed by an intravenous regime of Dextrose and normal saline for 24 hours. In spite of the I/v regime the blood pressure remained low (systolic 60-100; diastolic 40-70) for about 12 hours following the accident.

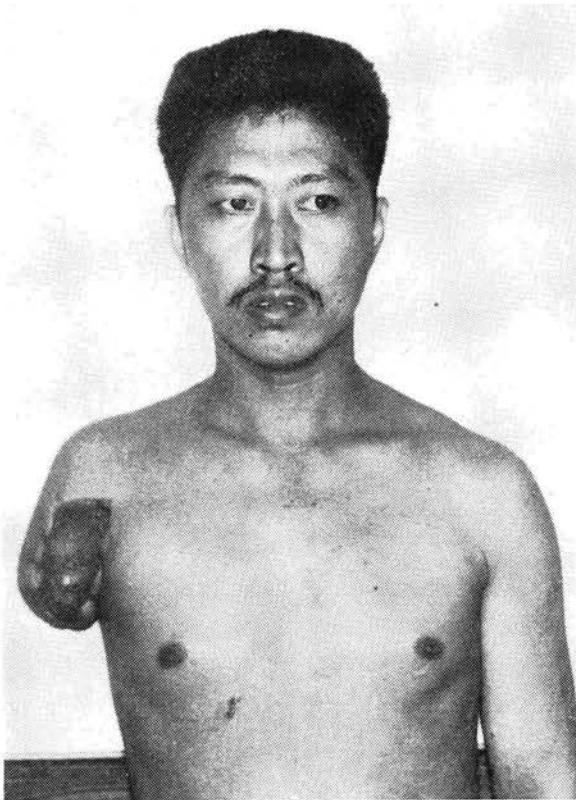On the 2nd post-operative day, slough from the wound was excised and again 3 pints of blood were transfused because of hypotension due to generalised oozing following surgery.

The right upper limb was amputated (Fig. 1) on the 4th post-operative day and 2 pints of blood were infused during surgery.

2 days later, after dressings were changed, he had another episode of hypotension and again had 2 pints each of packed cells and whole blood transfused. Following this he gradually improved.

Eleven days after the accident he complained of blurring of vision in both eyes; more so in the right eye, following amputation of his limb. Examination showed that the visual acuity in the right eye was hand movement only and in the left 6/9. The right pupil was dilated with an afferent pupillary defect (Marcus-Gunn pupil). The fundus showed mild optic disc pallor with very narrow retinal arteries together with some whitening of the vessels in the peripapillary region. (Fig. 2). The retinal veins were normal. The retina was greyish-white in colour and the macula oedematous. No cherry red-spot was seen. The left eye was normal.

(Fig. 3). A diagnosis of C.R.A.O. was made and as the fundus appearance was that of a retinal vascular accident some days previously no active treatment was undertaken. His visual acuity has remained unchanged during a follow-up period of over 6 months.

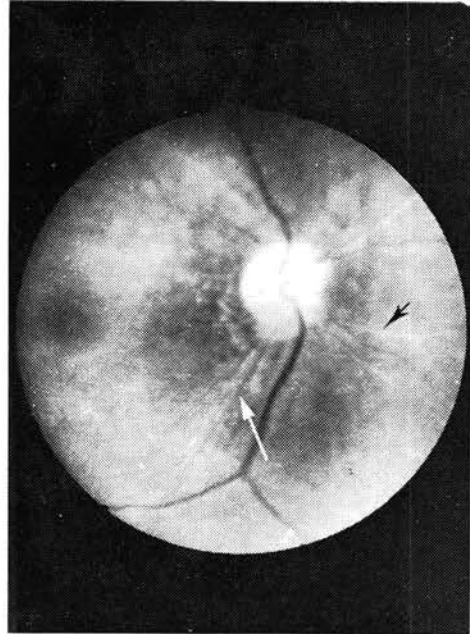


**Fig. 1**  
The patient, after mid-arm amputation.

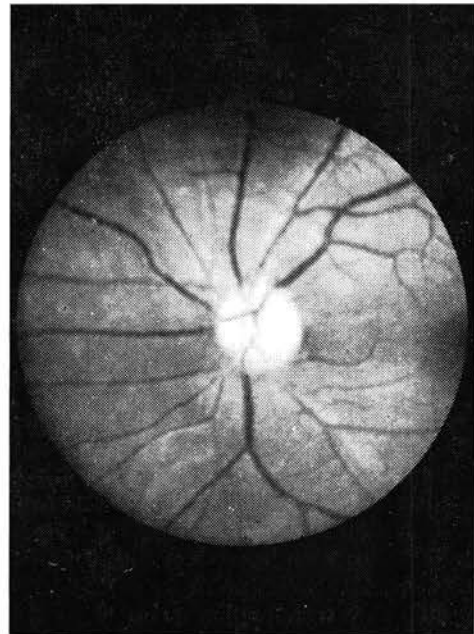
**Discussion**

Sudden loss of vision following haemorrhage may be due to a retinal vascular accident, ischaemic optic neuropathy (ischaemic papillopathy) or to visual cortex ischaemia.

Retinal arterial accidents are a well known entity. The classical picture of C.R.A.O. as described by von Graefe (1859) is one of mild disc pallor, retinal arterial narrowing with occasional segmentation of the blood column, (boxcar appearance) greyness of the retina together with a cherry-red spot at the macula. Occasionally a different picture of retinal ischaemia with widespread cotton-wool spots in the posterior pole and slight narrowing of the retinal arteries may be seen together with easily elicited pulsation of the central retinal artery at the disc on minimal digital pressure on the globe.



**Fig. 2**  
Right Fundus  
Optic disc pallor and marked narrowing of the retinal arteries is evident (white arrow) with some sheathing of the peri-papillary retinal arteries (black arrow). Retinal veins are of normal calibre. Pigmentary mottling is seen around the macula.



**Fig. 3**  
Normal Left Fundus

With blood loss, ischaemic papillopathy is more common than C.R.A.O. This was well documented by Gowers (1879). A pale swollen disc usually associated with superficial haemorrhages at the disc margin together with loss of vision and an altitudinal field defect is pathognomonic. The retinal arteries are of normal calibre but the veins may be fuller due to impedance of blood flow caused by an oedematous disc or rarely segmental superficial haemorrhages resembling a branch vein occlusion may be seen. This is an acute infarction of the optic nerve head (Hayreh 1974) due to occlusion of the small branches of the posterior ciliary arteries which supply the terminal portion of the optic nerve.

C.R.A.O. following haemorrhage is rare considering the frequency of hypotension due to blood loss. Recurrent haemorrhages associated with profound hypotension are more prone to affect vision and this is usually lost between the 3rd and 5th day. (Duke-Elder 1967). In Terson's series nearly 40% of cases had visual loss between the 3rd and 16th day (1922). In our patient this occurred sometime after the 5th day.

### Treatment

If vision is to be saved, treatment must be instituted immediately or at least within a few hours, if not irreversible damage to the retina occurs. Numerous agents have been used or suggested in the active treatment of this condition. Vasodilators, ocular massage, paracentesis, stellate ganglion blocks, retrobulbar tolazoline (Priscol), I/v dextran, inhalation of carbon dioxide and hyperbaric oxygen have all been tried and some improvement has been claimed (Simmonds, 1962) but up to the present no simple effective therapy has merited much success. All these measures have been undertaken to increase the perfusion pressure of the retinal circulation by lowering the intraocular pressure, increasing oxygenation of the blood and by dilatation of the arteries.

Retinal arteries do not possess a sympathetic nerve supply (Latie, 1967) so that stellate ganglion blocks, which prevent sympathetic neuro transmission, have no action in increasing the calibre of these arteries but may alleviate the condition by dilating the ophthalmic artery and so increase blood flow into the eye. Oxygen breathing causes narrowing of the retinal vessels; this vaso constriction being probably regulated by the accumulation of local metabolic products within the retina. Hyperbaric oxygen at 2.5 atmosphere has also been tried but retinal arteries undergo vaso constriction. Choroidal

blood flow and oxygenation, on the other hand, is increased and this can provide nearly the total oxygen requirement of the retina. (Anderson *et al*, 1965).

Inhalation of 7% carbon dioxide, which is the recommended concentration, again has maximal effect on cerebral blood vessels. Frayser and Hickam (1964) showed an increase in retinal blood flow but failed to show any significant increase in the calibre of retinal arteries, following inhalation of 10% carbon dioxide. Glyceryl trinitrate (GTN) which is a powerful coronary vaso dilator acts mainly on retinal veins and dilates them by about 5%. Intravenous hydralazine, a potent hypotensive and vasodilator, in a recumbent patient, produces a fall in blood pressure and an increase in calibre of retinal arteries but this mainly affects the smaller retinal vessels (Pickering, 1969). Paracentesis of the anterior chamber done as an immediate procedure in an acute C.R.A.O. of a few minutes duration, increases retinal blood flow and may "unblock" the artery. fytche *et al*. (1974) has shown that this procedure only increases retinal blood flow by 20% and that firm digital massage of the globe can through reactive hyperaemia, increase retinal blood flow by more than 80%; this being achieved by sudden lowering of the intraocular pressure following short periods of elevation.

With all the drugs and procedures available to us the most simple and effective immediate measures which should be instituted within 24 hours of the acute episode and can be carried out by any doctor, is to lie the patient flat, massage his eyeball and administer intravenous acetazolamide 500 mgm. (Diamox). Massaging of the globe should be done firmly with the index fingers and should be continued by the patient himself while the injection is being prepared. This technique may produce a drop in intraocular pressure of between 6 and 15 mm Hg. Further active measures can be carried out in hospital and every effort should be made to lower the intraocular pressure using intravenous osmotic diuretics e.g. 20% mannitol. If no improvement in the retinal circulation is seen after 24 hours of active treatment this should then be discontinued and treatment directed towards any associated systemic disease.

### Summary

A case of central retinal artery occlusion following haemorrhage is described. Visual loss was total in the affected eye. The various emergency measures in the treatment of this condition are discussed.

### Acknowledgement

The authors are grateful to the Medical Illustration Department, Faculty of Medicine, University of Malaya, for the photographs and Mrs. T.C. Lai for secretarial assistance.

(A part of this paper was read at the Scientific Meeting, Ophthalmological Society, M.M.A. in February, 1977).

### References

1. Anderson, B., Saltzman, H.A., Heyman, A. (1965) The effects of hyperbaric oxygenation on retinal arterial occlusion. *Arch. Ophthalmol.* **73**: 315.
2. Duke-Elder, (1970) System of Ophthalmology. vol. X Henry Kimpton, London, p. 60.
3. Ffytche, T.J., Bulpitt, C.J., Kohner, E.M., Archer, D., Dollery, C.T. (1974) Effect of changes in intra-ocular pressure on the retinal micro-circulation. *Brit. J. Ophthalmol.* **58**: 512.
4. Frayser, R., Hickam, J.B. (1964) Retinal vascular response to breathing increased carbon dioxide and oxygen concentration. *Invest. Ophthalmol.* **3**: 427.
5. Gowers, W.R. (1879) A manual and Atlas of Medical Ophthalmoscopy, Churchill, London, p. 184.
6. Graefe, A. von., (1859) Ueber Embolie der Arteria centralis retinae als Ursache plotzlicher Erblindung. *V. Graefes Arch. Ophthalmol.*, **5**: 136.
7. Hayreh, S.S. (1974) Anterior ischaemic optic neuropathy. *Brit. J. Ophthalmol.* **58**: 955.
8. Laties, A.M. (1967) Central Retinal Artery Innervation. *Arch. Ophthalmol.* **77**: 405.
9. Pickering, G.W. (1969) The eye as an index of generalised vascular disease. *Trans. Ophthalm. Soc. U.K.* vol. LXXXIX, p. 83.
10. Simmonds, N.T. (1962) Embolus of central retinal artery. *Am. J. Ophthalmol.* **54**: 1129.
11. Terson (1922) Duke-Elder, System of Ophthalmology. vol. X Henry Kimpton, London, pp. 60.

