

Subacute (Dequervain's) thyroiditis - Study of seven cases

by *V. Mahadev*

FRCPE., MRCP., MRCPG., MSc., AM.
Consultant Physician

S. K. Dharmalingam

DMRT., FICS., AM.

Senior Consultant and Head of the Institute of Radiotherapy, Oncology & Nuclear Medicine, Hospital Besar, Kuala Lumpur.

Dora Tan

MBBS.,

Virologist,
Institute of Medical Research, Kuala Lumpur.

and *Narasimha*

FFR., MRCP., MSc.,
Clinical Specialist

C. W. Loh

BSc (Hons)

Biochemist, Institute of Radiotherapy, Oncology & Nuclear Medicine, Hospital Besar, Kuala Lumpur.

T. T. Tschang

FRCS.,

Klinik Sentosa, Kuala Lumpur.

SUBACUTE THYROIDITIS SAT is an acute, subacute or chronic, generalized, self limiting, non-bacterial inflammation of the thyroid. The onset is often dramatic and acute with severe pain radiating to the jaw or the ear, an enlarged painful tender thyroid and systemic manifestations including fever. Usually the diagnosis of subacute thyroiditis is not difficult but the thyroid may not be tender (Volpe 1958) and recent reports by Hamburger 1974 and Papapetrou 1975 have emphasized that this lack of tenderness in atypical cases accompanied by symptoms of thyrotoxicosis may lead to diagnostic confusion and inappropriate treatment of such occult or silent thyroiditis as thyrotoxicosis. Low radioiodine uptake with thyrotoxicosis clinically and hyperthyroxinemia or hyperthyriodothyronemia can occur in Hashimoto's thyroiditis, ingestion of iodide, thyroid hormone, certain other drugs and the ectopic production of thyroid hormone, but thyroiditis of viral or autoimmune origin will be suggested by a raised sedimentation rate, tenderness over the thyroid gland, and characteristic features on thyroid biopsy. Thyroiditis and so called hyperthyroiditis may masquerade as several different conditions including thyrotoxicosis. Also painful conditions of the neck including dental abscess, tonsillitis, myositis and neuritis may be mis-diagnosed as thyroiditis. A characteristic low ¹³¹I uptake is one of the important signs (Werner 1948) although raised ESR, elevated thyroid hormone levels, thyroid antibody tests, viral studies and lastly but most important thyroid biopsy is most useful in establishing the diagnosis. When dealing with a painful thyroid condition haemorrhage into a cyst may mimic closely the explosive onset so frequently seen in subacute thyroiditis. In this area such patients are

often medicated with iodides, thyroxine and analgesics including phenylbutazone and antithyroid drugs all of which may produce a depressed ¹³¹I uptake so characteristic of SAT. To compound the confusion a history of pre-existing goitre may be seen in up to 16% of cases of SAT. (Woollner LB et al 1957). In the thyroid investigation centre at the department of Nuclear Medicine here only 7 cases of subacute thyroiditis which fitted with the clinical and laboratory criteria described above have been seen, although during the same period over 1500 cases of miscellaneous thyroid conditions were investigated. The incidence of SAT in other centres have been variously described as 1-6.2% of all patient with thyroid disease (Woollner et al 1967). While a highly selected group is being referred to this centre it was felt a detailed clinical and laboratory investigation including aspiration cytology, thyroid function, viral studies and careful follow-up was worthwhile. The nature and extent of the anomalies occurring in the parameters of thyroid function during the course of the disease and the role played by the pituitary-thyroid feedback mechanism is disputed. According to some investigators the levels of TSH are found to be normal in the initial phase though others maintain the levels are low or even high. A follow up study of the various parameters of thyroid activity during the weeks following SAT was done in four cases who presented this year.

MATERIALS AND METHODS:

The patients were investigated as part of a routine thyroid investigation protocol which included a history of febrile illness in patients and contacts, symptoms referred to the neck and goitre, systemic

complaints such as fever and malaise, and symptoms of toxicity. Thyroid status was assessed clinically and on the basis of thyroid function tests. Routine thyroid tests included ¹³¹I uptake (normal 24 hour value 15–45%) and scan, TSH stimulation test, Serum thyroxine (T-4) using the competitive protein binding (Murphy et al 1964), (normal range 4–12 micrograms %) Effective thyroxine ratio (ETR) using the modified Mincey techniques (Mahadev et al 1970) normal range 0.82–1.16, T-3 resin uptake normal range 75–112%, serum human thyroid stimulating hormone (HTSH) using the Abbott HTSH kit, 0–5nIU/ml, serum triiodothyronine (T-3) using the Abbott T-3kit normal range 1–2.5 ng/ml, and TRC for thyroid antibodies using the thyroglobulin haemagglutination kit. Besides the above relevant thyroid tests erythrocyte sedimentation rate (ESR) and white blood cell counts (WBC) were performed at each visit, blood was taken and examined for antibodies to influenza serotypes, and adenovirus (at least 2 specimens at the initial visit and 2 months later were obtained for each cases). Fine needle aspiration biopsy over the involved area of the thyroid was done at the initial visit and light microscopical examination of the smears stained by May-Grunwald

Giemsa (MGG) was performed. The aspiration biopsy was repeated on complete recovery. All patients after complete recovery were given 0.2 mgm of thyrotrophin releasing hormone (TRH) and the TSH response monitored over 1 hour. The normal pattern (see figure 1) at 20 minutes is a mean value of 9.5 uIU/ml range 3.5–15.6 uIU/ml, at 60 minutes a mean of 6.8 uIU/ml range 2.0–11.5 uIU/ml. All the patients were initially treated symptomatically with aspirin, and a course of antibiotics had often been earlier given by the referring doctors. All cases had x-rays of the neck on the initial visit for signs of tracheal compression.

RESULTS:

Case 1 LFY female aged 29 was referred to an E.N.T. Specialist with a history of a painful tender swelling of the thyroid gland worse on the left side and associated with fever and chills for 1 month, She complained of dysphagia but did not give a history of palpitations, sweating, tremors or other symptoms suggestive of toxicity. On examination there was a tender lump over the right side of the thyroid gland which moved on deglutition. There was no bruit and no tremors or sweating.

	26/2	7/4	28/4	6/5	19/7
131-I Uptake 4 Hrs.	2%	3.2%	–	–	28%
SCAN	1.4%	3%	–	–	48%
T-4	6.4 ug%	4.6 ug%	7.0 ug%	10 ug%	3.6 ug%
RU	87%	111%	124%	99%	110%
ETR	0.93	1.16	0.88	0.95	0.88
T-3	2.0 ng/ml	–	–	–	2.3 ng/ml
HTSH	5.0 uIU/ml	–	–	–	3.0 uIU/ml

Aspiration cytology of thyroid initial showed a classical appearance of giant histiocytes, lymphocytes and mononucleated inflammatory cells. (See fig. 2). The TRC for thyroid antibodies was negative.

Viral Studies – A/Port Chalmers 1:20 (1st. specimen)
1:20 (2nd. specimen)
Other influenzae – ive
Adenovirus CT Test – ive

An exaggerated HTSH response to TRH was seen after complete recovery (See fig. 1).

Case 2 SLS aged 31 years female was first seen on 3.1.76 with a history of a painful tender swelling of the neck for more than two weeks. Examination showed no significant abnormality except pooling of saliva in the hypopharynx and an exquisitely tender goiter most marked over the right lobe of the

thyroid gland. The pulse was rapid over 90/minute, but there were no other signs of toxicity. She was swinging a high fever of 102°F since admission and direct laryngoscopy under GA by an ENT specialist showed no lesion of the trachea or the bronchial tree proximally. Plain x-ray of the neck showed a soft tissue swelling anteriorly but no tracheal compression.

Thyroid aspiration cytology showed inflammatory cells with neutrophils leukocytes and macrophages.

Viral Studies A/Port Chalmers 1:10 (1st. Specimen)
1:10 (2nd. Specimen)
A/Victoria 1:10 (1st. Specimen)
1:80 (2nd. Specimen)
All other strains negative
Adenovirus CF Test negative.

	3/1	23/2	26/4	19/7
131-I Uptake 4 hrs.	2.6%	24%	-	9%
24 hrs.	0.9%	57%	30%	24%
SCAN	Normal except for greater pick up on the right			enlargement of the right lobe of the thyroid
T-4	14.3 ug%	5.6 ug%	8.1 ug%	3.6 ug%
RU	73%	111%	112%	108%
ETR	1.92	0.82	1.08	0.92
T - 3	1.8 ug/ml	-	-	1.8 ug/ml
HTSH	-	-	-	1.2 uIU/ml

TRC for thyroid antibodies was negative. The patient was treated symptomatically with aspirin and rest and recovered within one month. However on review in May she had symptoms of sore throat suggestive of a relapse. However she was clinically free of thyroid swelling or tenderness. On 19/7 seven months after the initial onset of the illness the patient appeared euthyroid and there was no residual thyroid lump. An exaggerated response of HTSH to TRH was however noted (see fig. 1) and the basal T-4 level was in the lower limit of normal range and had gone down considerably since the initial examination.

Case 3 CKW 38 years, male gave a history of fever for 2 months and had lost nearly 20 pounds in weight. About one month ago he developed a painful lump right neck, and heat intolerance and palpitations. He gave a past history of peptic ulcer for which a polyga gastrectomy was done. Initial examination showed an oval swelling hard and tender arising from the right lobe of thyroid gland. He had tremor tachycardia and warm moist palms. The ESR was 120/1st. hour, WBC and Urine examination were normal and the Widal Weil Feli-ive.

Thyroid aspiration cytology showed initially on 3.6.76 degenerate follicular cells with inflammatory cells and red blood cells.

TRC for thyroid antibodies showed a low titre 1/250. The patient received symptomatic treatment and 2 weeks later had completely recovered and the lump was no longer palpable. ESR previously 120 mm/1st. hour on admission on 31/5 had now fallen to 12 mm on 13/6. On 12/7 the patient had completely normal findings and TRH test showed an exaggerated HTSH response (see figure 1).

Viral Studies Influenza - B Hongkong
 1:40 (1st. specimen)
 1:40 (2nd specimen).
 Other strains - ive
 Adenovirus CF Test - ive

Case 4 TYC, 38 years male, had fever, pain in the neck, palpitations, weight loss and sweating for 6 weeks. He had seen several doctors for his painful neck and received several analgesics including 'Tanderil' and antibiotics. His wife and children had also developed a 'flu' at the same time but had recovered completely. There was a hard tender lump over the right neck but no other significant finding. There were no overt signs of thyrotoxicosis.

Before TSH	31/5	After TSH	13/6	12/7
131-I Uptake 4 hrs.	3.4%	3.7%		
24 hrs.	0.6%	4.7%		
	31/5		13/6	12/5
T-4	15.5 ug%		5.2 ug%	5.6 ug%
RU	67%		110%	112%
ETR	1.19		1.03	1.1
T-3	2.6 ng/ml		-	1.6 ng/ml
HTSH	0.1 uIU/ml		-	10 uIU/ml

Before TSH	21/5	After TSH	26/5	21/7
131-I Uptake 4 hrs.	3.0%	3.2%	-	18%
24 hrs.	1.2%	1.0%	-	29%
131-I Scan				Normal Thyroid
T-4	11.0 ug%			4.2 ug%
RU	108%			116%
ETR	1.00			0.80
HTSH	0.1 uIU/ml			
T-3	3.5 ng.ml			

Thyroid aspiration cytology showed inflammatory cells and degenerate follicular cells. TRC for thyroid antibodies was negative. The patient was diagnosed as acute thyroiditis and initially treated conservatively but the pain worsened and the fever continued. The patient was put on steroid therapy on 8/6 and almost within 24 hours the patient's symptoms remitted. However each time the steroids were withdrawn the patient relapsed till after the third course the patient finally had a sustained remission. On 21.7.76 a repeat thyroid aspiration showed normal follicular cells. A TRH test showed an exaggerated response pattern.

Viral Studies A/Port Chalmers 1:80 (1st. Specimen)
1:40 (2nd. Specimen)
A/Victoria 1:80 (1st. Specimen)
1:40 (2nd. Specimen)
Residual antibody against all other strains - ive
Adeno virus - ive

DISCUSSION:

Clinical findings - Thyroid pain, swelling and an associated febrile onset was present in all the cases and the onset was acute in all of them. Four of the cases were referred by ENT Specialists. In contrast in the Mayo Clinic series 37% had jaw pain and were referred by dental surgeons (Tolman et al 1962). A hyperthyroid syndrome was seen in three cases and in case 3 there was a severe weight loss of nearly 20 pounds, were thyroid pain and fever less striking these cases may plausibly be misdiagnosed as hyperthyroidism. Such 'occult' or 'silent' SAT have been previously reported by Hamburger et al 1974 and Papatrou et al 1975 and may in fact be fairly common in this area as the overall incidence of classical SAT appears to be lower in relation to thyroid disease in general. Many of the systemic symptoms such as fever and malaise were indistinguishable from common febrile illnesses such as influenza. The thyroid swelling was asymmetrical

Table 1
Main features of 7 cases subacute thyroiditis studied

Thyroid pain swelling and tenderness	100%	(7/7)
Febrile illness	100%	(7/7)
Dur		
Duration of symptoms at onset	2 weeks	1/7
	4 weeks	2/7
	6 weeks	3/7
	8 weeks	1/7
Hyperthyroid syndrome	45%	(3/7)
Elevated ESR	100%	(4/4)
Depressed 131I uptake	100%	(7/7)
Elevated T4	45%	(3/7)
Elevated T3		(3/4)
Thyroid aspiration cytology		
Inflammatory cells	100%	(4/4)
Necrotic follicular cells	50%	(2/4)
Giant cells	25%	(1/4)
Viral influenza antibody		4/4
Titres present significant rise		1/4
TRC thyroid antibodies		
Negative		6/7
Weakly positive		1/7
Patchy asymmetrical pick up on 131I scan after recovery		3/7
Exaggerated TSH response to TRH after recovery	100%	4/4
Complete response to symptomatic therapy	90%	6/7

in all the cases. This was evident clinically and in 3 cases the gland was very hard, one of them being misdiagnosed as thyroid carcinoma by the referring doctor. None of the cases had any past history of thyroid swelling.

I - 131 uptake: All the patients had markedly depressed 131-I uptake in the initial study. Thyroidal activity was too low for scans to be done and in case 4 - 99 Tc m uptake was also markedly depressed. Since Werner's description of this in 1949 as an important feature of SAT it has been described as the most reliable finding. However iodide ingestion, antithyroid drugs, thyroxine, ectopic production of thyroid hormone and conditions like Hashimoto's

disease may produce a similar uptake pattern. Most of the patients had taken analgesics and antibiotics outside before their initial visit here and drug interference has to be carefully ruled out – for example case 4 had taken ‘Tanderil’ a drug which depresses thyroidal ^{131}I uptake and is goitrogenic. The response to TSH administration in SAT is interesting. One of the earliest cases diagnosed in this series in 1972 had a classical history of painful thyroid lump associated with fever raised ESR and a high serum T-4 of 9.1 $\mu\text{g}\%$ but although the patient had a thyroid lump on the left side on TSH stimulation this was a functioning nodule and the apparently normal right lobe was cold. All the other cases had markedly depressed ^{131}I and $^{99}\text{Tc m}$ uptakes which did not rise on TSH stimulation thus proving that primary thyroid cell impairment leading to a temporary impairment in iodide concentration mechanism is the cause for the low uptake. It is possible the case described above may in fact be a case of thyroid adenoma with localized thyroiditis involving one lobe. The patient has completely recovered and no thyroid biopsy has been done and it is not possible to confirm this. It is however clear that interruption of the thyroid iodide concentration mechanism rather than the lack of endogenous TSH stimulation due to an overwhelming outpouring of thyroid hormones from the damaged thyroid appears to be the cause for the low radioiodine uptake seen initially in SAT (Daniel Glinoe et al 1974). The depressed ^{131}I uptake coexisting with the high T-4 values correspond to the hyperthyroid or stage 1 phase of SAT as described by Volpe et al in 1958. In case 2 thyroidal ^{131}I uptake reverted to a high normal range within 6 weeks and subsequent values of 24 hour radioiodine uptake declined corresponding to a decline in T-4 levels. Basal HTSH values at the onset were normal and it is likely the suppression of ^{131}I uptake during this phase was due to thyroidal damage.

Thyroidal hormone levels – In nearly half the cases serum thyroxine was initially elevated. Two cases 1 and 4 had high serum T-3 values in the presence of normal T-4 values. This is difficult to understand if one postulates that the high values of thyroid hormones in the circulation is due to abnormal release of intrathyroidal hormones rather than increased production of hormones by the thyroid. Triiodothyronine has a larger volume of distribution in the body and a higher turnover and from this one would imagine elevated T-3 levels will be less striking and sustained than elevated T-4 levels. Increased extrathyroidal conversion of T-3 to T-4 and faulty autoregulation by the thyroid and high T-3/T-4 ratio could be postulated in these cases. The T-3 resin uptake and the ETR values correlate closely with T-4 values initially and on

follow-up. On follow-up thyroxine levels which were initially elevated in 3 of 7 cases progressively fell in all to normal levels within 1 month. Cases 1, 2 and 4 had T-4 values in the subnormal range after apparent complete recovery. In case 1 a low T-4 was associated with elevated T-3 values. All 4 cases had exaggerated HTSH responses to TRH (See Figure 1) although the basal HTSH values were normal. This suggests some degree of hypothyroidism. One patient was followed up for more than 3 years and had completely recovered from SAT but showed an exaggerated HTSH response to TRH. In the 4 cases described it is possible further follow up may reveal a reversion of TRH response to normal with time. SAT in contrast to Hashimoto's thyroiditis has been described as leading very rarely to permanent hypothyroidism (Volpe 1958) and occasionally to hyperthyroidism (Perloff et al 1956.)

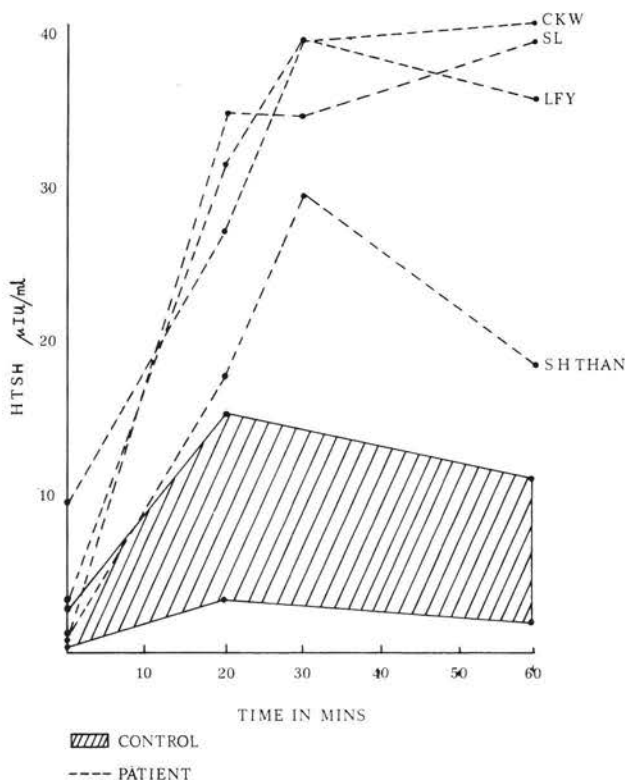


Figure 1

HTSH response to 0.2 mg of TRH in four patients following complete recovery from acute thyroiditis.

Thyroid Cytology – Multinucleated giant cells are classical of SAT but was only identified clearly in 1 of the 4 cases. These cells contained about 30 nuclei situated one on top of the other (see figure 2). In 3 or 4 cases degenerative changes in the follicular cell were striking cloudy cytoplasmic vacuolization and pyknotic nuclei. In case 4 a repeat thyroid aspiration cytology after steroid therapy showed completely normal follicular cells although initially they showed degenerative changes. Proliferative changes in the follicular cells have been reported in the recovery phase of SAT (PS Persson 1967). Inflammatory cells in the form of macrophages, polymorphs, mature lymphocytoid cells and red blood cells were a constant finding in all 4 cases studied cytologically. In case 1 a repeat aspiration after apparant recovery showed persistent macrophages, lymphocytoid cell and polymorphs. Aspiration cytology cannot by itself exclude malignancy – this was excluded malignancy – this was excluded on clinical grounds and on the basis of thyroid function tests. However aspiration with characteristic findings of giant cells, degenerative changes in the follicular cells, and inflammatory cells strongly supports a diagnosis of SAT. One could exclude with certainty haemorrhage into a cyst as a cause for a painful thyroid lump. Diffuse lymphoid

thyroiditis characteristically shows Askanazy cell change with typical granulations of the cytoplasm, and acute suppurative thyroiditis would show a predominantly polymorph pattern of infiltration and causative bacteria may be identified. However the cytological pattern in SAT varies from patient to patient and from one part of the thyroid to another (Persson 1967). Numerous reports suggest that even malignant thyroid processes and reticulum cell sarcoma could be diagnosed cytologically (Frazell et al 1958) but it is clear this technique is better avoided where malignancy is strongly suspected.

Viral studies – Subacute thyroiditis in all cases reported here as elsewhere was preceded by an upper respiratory infection, fever and systemic manifestations, and occurred in 2 of the cases in association with 'flu' like illness in contacts. Subacute thyroiditis has been associated with mumps epidemics in at least 5 reports, measles, influenza, common cold, adenovirus infections mononucleosis, coxackie virus, cat scratch fever, and at least 2 non-viral agents malaria and Q fever. In case 2 there was a significant rise in titre of influenza antibodies to A/Victoria 1:10 to 1:80 and it is almost certain the illness occurred in association with influenza although the actual role of influenza in producing

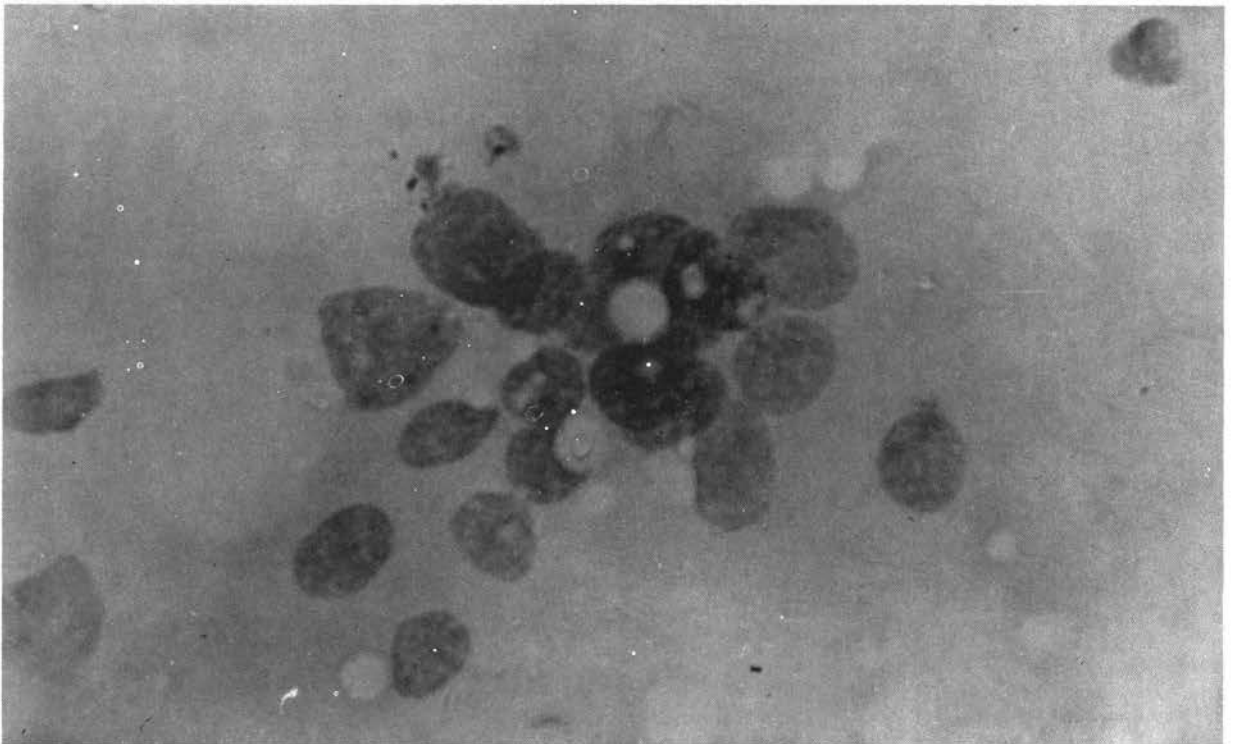


Fig. 2

the thyroid lesion is not certain. Case 4 showed a fall in titres of A/Port Chalmers and A/Victoria from a very significant level of 1:80 to 1:40. Volpe 1967. In a series of 58 patients first described a high titre of viral antibodies to influenza A, mumps, coxackie B type and adeno virus which fell to normal during the course of the illness in nearly half of them. The presence of significant titres of more than 1 viral antibody may merely represent an anamnestic response to the inflammatory thyroid lesion rather than a specific viral infection. It is also possible at least in the 2 cases where either a significant fall corresponding to the course of the illness or a significant rise may indicate a viral etiology for SAT. It is quite possible that SAT may in fact be a stereotyped thyroidal inflammatory response to a variety of viruses (Volpe 1967).

Therapy – Two of the seven cases in the series were treated with steroids. All the other cases appeared to have responded to symptomatic measures. In case 4 withdrawal of steroids was followed by a relapse. It is generally recommended that steroids in SAT should be carried on at least for 1 month and gradually reduced over the next month. (Eylan et al 1957). Salicylates however are highly effective in the majority of cases and steroids can be reserved for the severe one. Case 4 had normal thyroid cytology following steroids can be reserved for the severe one. Case 4 had normal thyroid cytology following steroid therapy whereas case 1 and 2 continue to show inflammatory cells and macrophages on repeat aspiration more than 3 months after the onset. While the value of steroids may entirely be symptomatic it may have a direct effect in arresting thyroid inflammatory process triggered of by virus and in this respect may have a wider role. Other methods including surgery, antithyroid drugs, radioiodine and external radiotherapy have been used and have a failure rate of about 25% and are inferior to steroids.

Summary and Conclusion:

1. The clinical pattern in 4 cases of subacute thyroiditis has been described in detail. 3 other cases followed up for more than 2 years were reassessed.

2. Influenza antibodies were present in all 4 cases but a significant rise in titre to A/Victoria strain occurred in 1 case and a significant fall in titres during the illness to 2 strains A/Victoria and A/Port Chalmers occurred in 1 case. The significance of this finding is discussed and points to a viral role in the etiology of SAT.
3. Thyroid aspiration cytology is a useful technique in diagnosis and follow-up of cases of SAT.
4. Thyroid failure in the long term as a permanent feature of SAT has hitherto been described as a rare manifestation but an exaggerated HTSH response to TRH in 6 cases studied after apparant recovery suggests that some degree of marginal thyroid insufficiency may persist.

REFERENCES:

1. Daniel Glinoe, Nicole Puttemans, Andre J Vane Herle Et Al: *Acta Endocrinologica* 77: 26-24, 1974.
2. Eylan E, Zmucky R and Sheba C: *Lancet* 1, 1062-1063 (1957).
3. Frazell El and Foote Jr FW: *Cancer* 11: 895, 1958 Papillary Cancer of the Thyroid.
4. Hamburger JI: Subacute Thyroiditis: Diagnostic Difficulties and Simple Treatment. *J Nuclari Medicine* 15: 81-89, 1974.
5. Mahadev V, Oh E, Narasimha K et al: The Effective Thyrodine Ratio in Determining Thyroid Status Proceedings of the Seventh Malaysia-Singapore Congress of Medicine 7: 47 - 56, 1972.
6. Murphy Bep and Patee CJ: Determination of Thyroxine Utilizing the Property of Protein Binding. *Journal of Clinical Endocrinology & Metabolism* 24: 187 - 196, 1964.
7. Papapetrou PD, Jackson IMD: Thyrotoxicosis due to Silent Thyroiditis. *Lancet* 1: 361 - 363, 1975.
8. Perloff WH: Thyrotoxicosis Following Acute Thyroiditis. *J Clin. Endocr.* 16: 542, 1956.
9. Persson PS. *Acta Medica Scandinavia Supp.* 483: 1967.
10. Tolman De, Cibilisco Ja, McConahey WM: Subacute Thyroiditis. A Diagnostic Possibility for the Dentist. *Oral Surgery* 15: 293, 1962.
11. Volpe R, Johnston MW, Huber N: Thyroid Function In Subacute Thyroiditis. *J Clin. Endocr.* 18: 65, 1958.
12. Volpe R, Row VV and Ezrin C: Circulating Viral and Thyroid Antibodies in Subacute Thyroiditis *J Clinical Endocrin* 27: 1275, 1967.
13. Woolner LB, McCona Hey WM, Beahrs OH: Granulomatous Thyroiditis (deQuervains Thyroiditis) *J. Clin Endocr* 17: 1202, 1957.