

Accidental Vaccinia Infection - A Case Report

K.L. Lam,[†] V.J.L. How,^{*} & S.K. Lam^{*}

[†]Department of Paediatrics

^{*}Department of Medical Microbiology
University of Malaya

It is often forgotten that smallpox vaccine is a live virus and that due care has to be taken in its handling and administration by medical personnel. The recipient or, in the case of a child, those responsible for its care, should be warned of the nature of the vaccine and its infectivity to himself and to others. The risk of accidental vaccinia is greatest when there is free lymph at the vaccination site soon after inoculation or after rupture of the pustule but the risk is always present until the scab separates.

Accidental vaccinia infection can occur when a susceptible person comes in close contact with a recently vaccinated member of the same household. It can also be the result of autoinfection of other areas of the body through scratching or, as occasionally happens, the doctor or nurse giving the vaccine may be infected through finger abrasions. It is also possible that the virus can penetrate apparently intact skin³ and mucous membranes.¹

Practically any part of the body may be affected,^{1,2,3,4,5} the sites reported include satellite lesions around the original vesicle, the eyes and eyelids, more rarely the neck, face, lips, tongue, nostrils, skin wounds, and even the anus and genitalia.⁴ These often appear as isolated lesions with little constitutional disturbance but could be serious if they occurred, for example, in a person with eczema.

We report a case of accidental vaccinia infection on the tongue and gum margin.

NSM is a 9-month old Chinese female, who was first seen in Polyclinic, University Hospital, on 5.10.72 with the complaint of an ulcer on the tongue. This was first noticed 4 days ago when the child was irritable and not feeding well. Two days later, another ulcer was seen on the upper

gum margin adjacent to the first ulcer. There was no fever but the child had a little loose stool.

Three weeks earlier, an elder sibling aged 1½ years had had a successful primary smallpox vaccination.

On physical examination the child was afebrile, the only abnormality being a superficial ulcer 1 cm in diameter with a whitish base on the right side of the tongue (Fig. 1). There was no bleeding or tenderness. A smaller almost healed ulcer 2 mm in diameter was seen in the adjacent upper gum margin. There was slight enlargement of the sub-mandibular glands.

A swab taken from the ulceration on the tongue grew normal bacterial flora but cultures on chorio-allantoic membranes of 11-day old eggs showed lesions resembling vaccinia pocks (Fig. 2). Electron micrograph of the virus particle supported this finding (Fig. 3). The identity of the virus was confirmed as vaccinia virus by haemagglutination-inhibition using immune serum.

The child was treated topically with gentian violet 1% and the ulcers healed completely in 12 days without any visible scarring.

Comment

It is not difficult to see how this child caught the infection from her elder sibling.

There is very little information in the literature of the incidence of accidental vaccinia. It has been estimated at about 13.6 per million by Neff et al. in the U.S.A.⁵ The incidence is unknown in this country.

Recognition of suspected vaccinia infection is by virus isolation from the vascular fluid or by rise in specific antibody titre.² In this child,

we were able to culture the virus and identify it. Serology was not attempted as we were not able to obtain the second blood specimen.

In administering smallpox vaccine, the responsibility of the doctor or nurse does not end at determining the usual contraindications on the patient to be vaccinated.⁶ He or she should also enquire into whether the household contacts have any form of dermatitis, are on steroid or immunosuppressive therapy or are suffering from any debilitating disease. Should there be any such person or persons whose immunisation status is also in doubt, the procedure should be postponed. Should this not be possible (e.g. vaccination for travelling abroad), such contacts at risk should be protected with specific gammaglobulin or the person vaccinated should be separated from them until the scab has dropped off.

In summary, we report a child with accidental vaccinia infection on the tongue and gum margin. Her contact was a recently vaccinated elder sibling.

References

1. Baernstein, H.D. et al. (1967): Accidental secondary vaccinia on the tongue. *Clin. Ped.*, 6: 435.
2. Epidemiology: Vaccinia infection. (1971) *B.M.J.*, 1: 121.
3. Horwitz, M.S. et al. (1966): A family outbreak of vaccinia. *J. Ped.*, 68: 308.
4. Hutfield, D.C. (1968): Accidental vaccinia. *B.M.J.*, 2:828.
5. Neff, J.M. et al. (1967): Complications of smallpox vaccination, *New Eng. J. Med.* 276:125.
6. Coriel, L.L. (1966): Smallpox vaccination - when and whom to vaccinate. *Pediatrics*, 37: 493.

Acknowledgements

We would like to thank the Department of Medical Illustration for the photographs and Mrs. M.T. Ng of the Department of Paediatrics for the secretarial work.

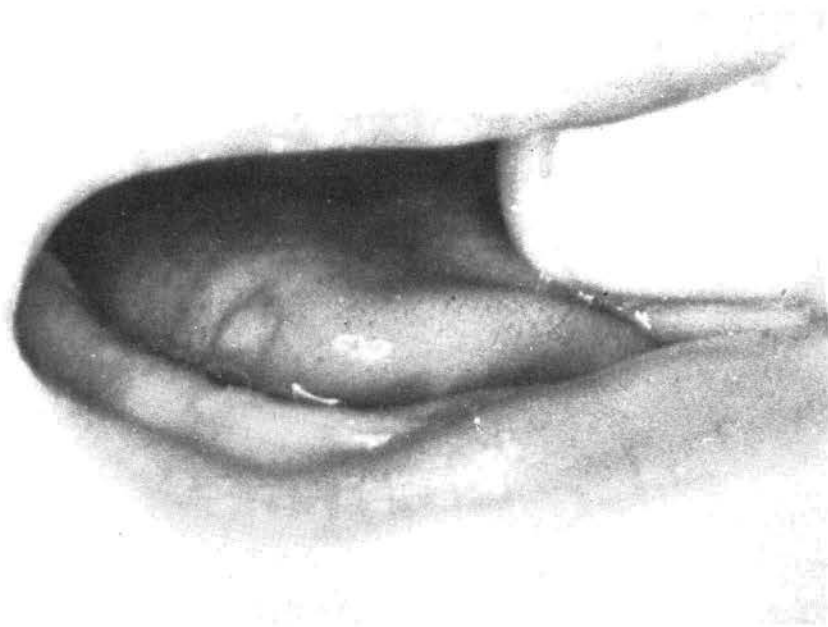

Fig. 1. Note the healing ulcer on the right side of the tongue. The photograph was taken on the 8th day by which time the ulcer on the upper gum margin had healed.

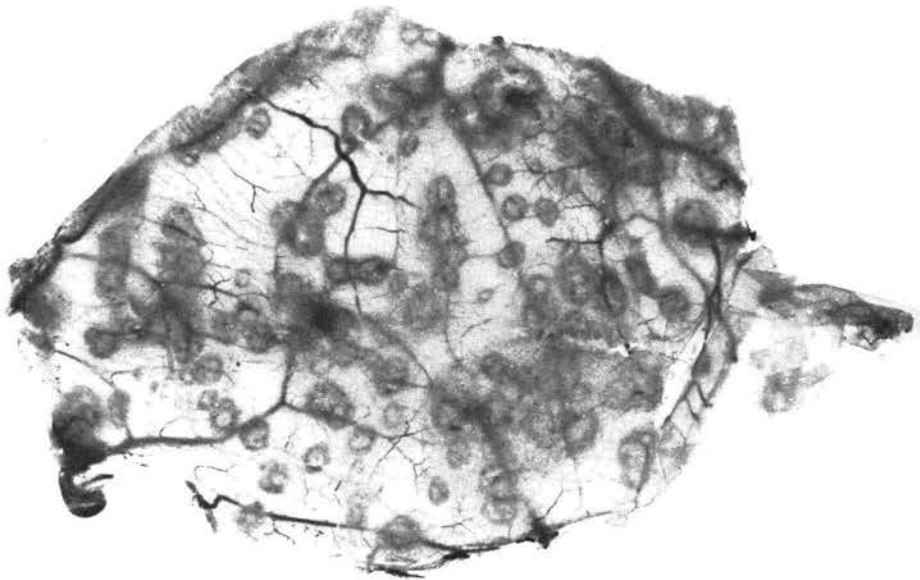


Fig. 2. Chorion Allantoic Membrane of 11-day old chick harvested after 72 hours showing numerous pocks with necrotic bases typical of those produced by vaccinia virus.

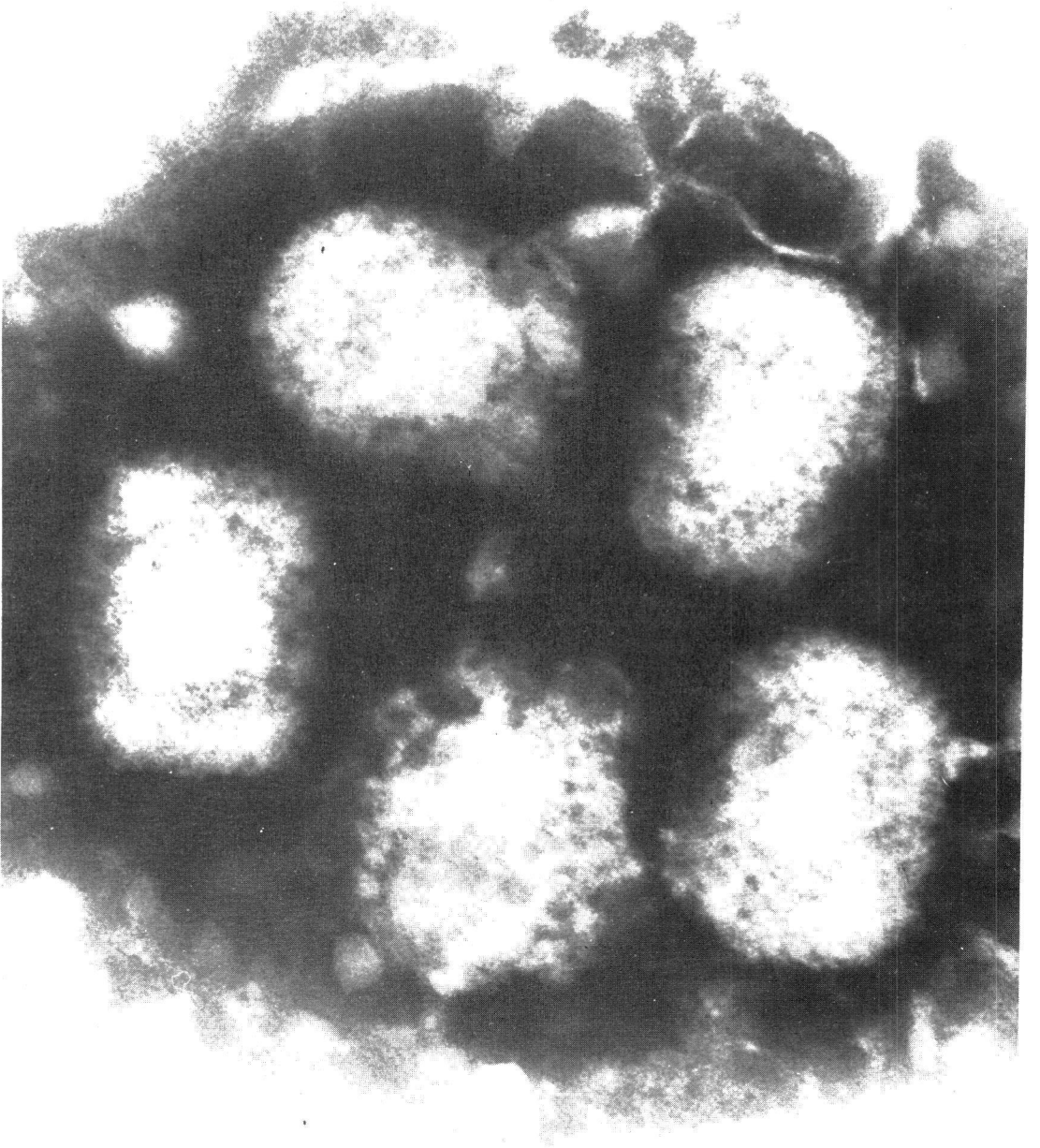


Fig. 3. Electron photomicrograph showing 5 typical brick shaped vaccinia virions. (Magnification 3.6 x 54,000)