

Rectus Sheath Haematoma

By HUSSEIN BIN MOHAMED SALLEH
M.B.B.S. (Adelaide); F.R.C.S. (Edinburgh); A.M. (Malaysia)
Consultant Surgeon and Head of Unit 3,
Department of Surgery, General Hospital,
Kuala Lumpur, Malaysia.

Two cases of rectus sheath haematoma seen and treated by the author are presented. It is a condition which should not be regarded with complacency as there is definite morbidity and fatalities have been reported. It is important in the differential diagnosis of the "acute abdomen".

Rectus sheath haematoma has been recognised since ancient times. The Greeks described it in the fifth century B.C. and Hippocrates, Galen and Leonardo da Vinci mentioned it in their works (PAYNE 1938). The condition is important as it has to be considered in the differential diagnosis of the "acute abdomen" and it causes morbidity with some reported fatalities.

CASE REPORTS

Case 1 - This 69-year old lady was admitted to hospital after falling two feet off a chair. On examination, there was a tender oval swelling, 10 centimetres by 8 centimetres, in the region of the left rectus muscle, 5 centimetres from the left pubic bone (FIGURES 1 and 2). The mass was confined to the margins of the rectus sheath and did not disappear on tensing the rectus abdominis muscle. There was ecchymosis over the lower part of the swelling. A diagnosis of rectus sheath haematoma was made and the patient was treated conservatively for 15 days. Over the thirteenth to fifteenth days, the mass grew bigger and painful and on the sixteenth day operation was performed. This revealed 500 milliliters of soft blood clot in the lower part of the left rectus sheath. There was some rupture of the rectus muscle here but no fresh bleeding. The patient made an uneventful recovery post-operatively.

Case 2 - This 90-year old lady was hospitalised with a complaint of fever and severe pain in the right hypochondrium for four days. There was no history of trauma. On examination, there was a fairly firm, tender mass in the right hypochondrium in the gall bladder region, 4 by 3 centimetres in dimensions. The overlying skin was red, hot and oedematous. The mass appeared to become less

obvious on tensing the rectus abdominis muscle. The temperature was 100 degrees Fahrenheit. The diagnosis made was empyema of the gall bladder which was on the verge of rupturing. Immediate laparotomy showed that there was 200 milliliters of soft blood clot in the upper part of the right rectus sheath (Figure 3). There was some rupture of the rectus muscle. The intraperitoneal organs, including liver, gall bladder and bile ducts, were normal. The patient made a good recovery post-operatively.

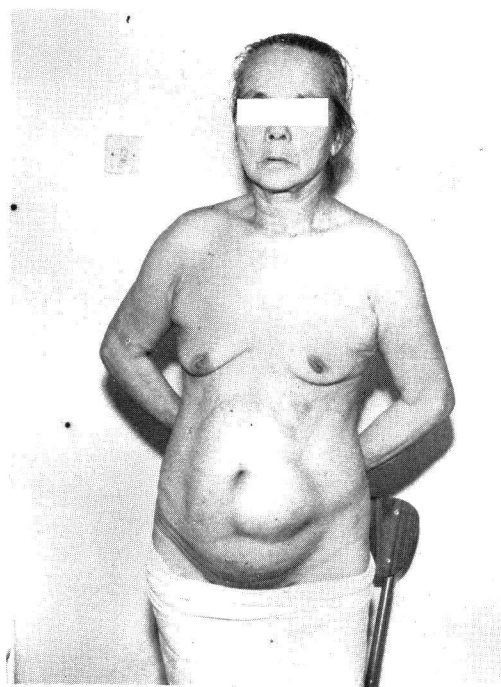


Fig. 1. CASE 1 - Swelling, below and to left of umbilicus, confined to rectus sheath. Ecchymosis over lower margin of swelling.

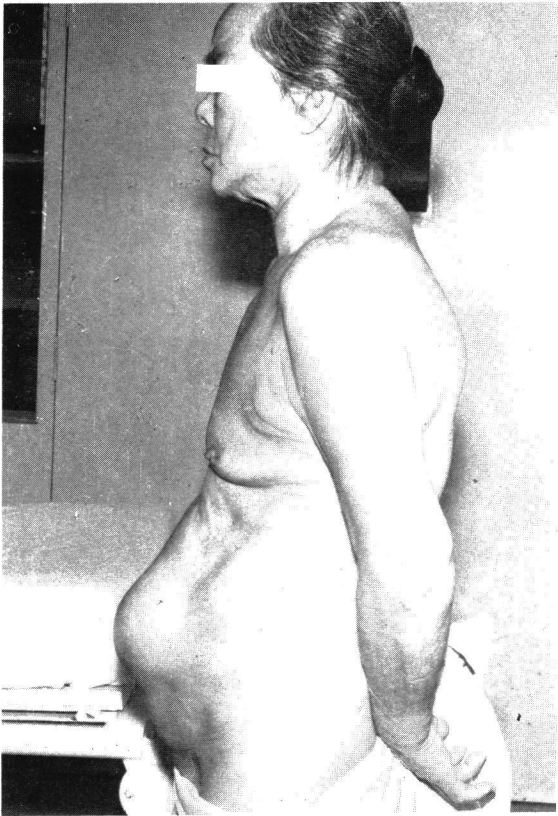


Figure 2 CASE 1 - Swelling is more obvious on lateral view.

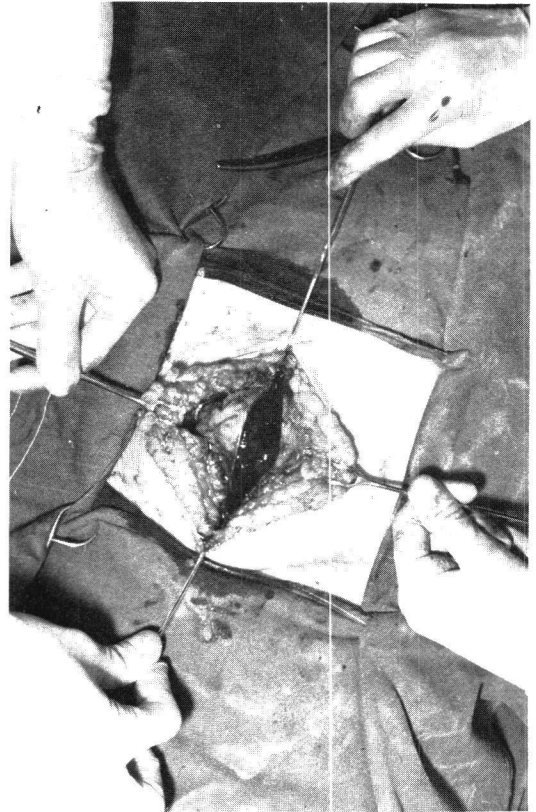


Figure 3 CASE 2 - Incision into rectus sheath reveals a haematoma.

DISCUSSION

The rectus abdominis muscle is particularly susceptible to haemorrhage due to its relationship with its nutrient blood vessels, the superior and inferior epigastric. These vessels must glide over the posterior aspect of the muscle to avoid being torn as it contracts. A haematoma is usually due to rupture of these vessels or their branches rather than a primary tearing of the muscle fibres. The inferior epigastric blood vessels are more tortuous and travel a longer distance before entering the muscle when compared with the superior epigastric blood vessels. Furthermore, below the semi-circular line of Douglas, the posterior rectus sheath is deficient, the muscle being supported only by the transversalis fascia and peritoneum. Therefore, the inferior epigastric vessels are more liable to rupture than the superior ones and most rectus sheath haematoma occur in the lower part of the sheath (MARTIN and THOMPSON, 1957). JONES and

MERENDINO (1962) stated that 50 per cent of cases occurred in the right lower quadrant of the abdomen, 33 per cent in the left lower quadrant and 17 per cent in the other quadrants. Females are more often affected than males by a two to one ratio (FLETCHER and JOSEPH 1973).

In some cases, no cause for the haematoma can be determined (SCHAFER 1953) but often an aetiological factor is present, namely:-

1. Pregnancy — The haematoma may occur at any time during the pregnancy, labour or puerperium (CULLEN and BRODEL, 1937). Coughing and poor rectus abdominis muscle tone due to overstretching are contributory factors.

2. Trauma — This may either be direct or indirect and may tear the epigastric blood vessels or the rectus muscle itself. It may occur in tetanus (NICHOLSON, 1956), during unaccustomed violent exercise and after injury to the epigastric blood vessels during abdominal surgery, peritoneal dir

or abdominal paracentesis. A severe spasm of coughing or chronic coughing may precede the haematoma (SHEEHAN 1951; BOWLES 1939).

3. Muscle degeneration -- Certain infective diseases may result in degeneration of muscles so that they are prone to rupture even under mild strain. These include typhoid fever (CULLEN and BRODEL, 1937) and influenza (COLE, 1918).

4. Previous abdominal surgery -- Many patients who develop rectus sheath haematoma underwent previous abdominal operations. The development of fibrous tissue post-operatively prevents the epigastric blood vessels from freely gliding over the posterior surface of the rectus abdominis muscle so that there is strain on these vessels when the muscle contracts. STILES, RASKOWSKI and HENRY (1965) reported that 13 out of 16 cases of rectus sheath haematoma were associated with previous abdominal surgery.

5. Haemorrhagic diathesis -- Blood dyscrasias, vascular degenerative diseases and anticoagulant therapy predispose the patient to rectus sheath haematoma. (SCHAFER 1953, JONES and MERENDINO 1962).

It is uncommon to make a correct diagnosis before operation and STILES, RASKOWSKI and HENRY (1965) reported that only 17 per cent of their cases were diagnosed pre-operatively. The differential diagnoses are many and varied. They include abdominal wall tumor, ovarian cyst, ectopic pregnancy, pelvic tumor or abscess including appendix abscess and obstructed or strangulated spigelian hernia. CASE 2 simulated an empyema of the gall bladder which was about to rupture. If the patient is a pregnant female, any obstetrical emergency must be considered, for example, rupture of a pregnant uterus (LUCAS and BAKER, 1958) and concealed accidental haemorrhage. The posterior rectus sheath is absent in the lower one third of the rectus abdominis muscle and therefore, a rectus sheath haematoma which spreads downwards and laterally can irritate the underlying peritoneum in this area, thereby producing symptoms and signs of any acute or subacute abdominal pathology. Rectus sheath haematoma presents as an abdominal mass which is still palpable on tensing the rectus abdominis muscle, the mass being usually confined to the limits of the rectus sheath. There may be ecchymosis over the mass as in CASE 1 or around the umbilicus and less commonly over the flank, penis or scrotum.

The symptoms and signs are of sudden onset and there is marked localisation of pain and tenderness. Needle aspiration of the swelling may yield blood whilst a plain lateral abdominal radiograph may show that the mass is in the rectus sheath.

In the pregnant female with haematoma, SHEEHAN (1951) reported a foetal mortality rate of 25 to 50 per cent whilst TORPIN (1943) found that the maternal mortality rate was 12 to 15 per cent. JONES and MERENDINO (1962) described a mortality rate of 4 to 5 per cent in all patients with rectus sheath haematoma. STILES, RASKOWSKI and HENRY (1965) reported a case where the patient lost so much blood into the haematoma that a pre-operative diagnosis of ruptured aortic aneurysm was made. In addition, there may be extensive destruction of the rectus abdominis muscle in cases where treatment is delayed. Consequently, rectus sheath haematoma is not to be regarded with complacency as it carries a definite morbidity and may result in loss of life.

TREATMENT

If the diagnosis is certain, the patient is initially managed conservatively. Smaller haematomata tend to be absorbed and resolve spontaneously. If the swelling gets larger, becomes tender, there are signs of shock, or if there is evidence of peritonitis, then operation is at once performed to drain the extravasated blood and secure haemostasis. If the diagnosis is uncertain, operation is done as soon as possible after adequate resuscitative measures.

ACKNOWLEDGEMENT

I thank the DIRECTOR GENERAL of HEALTH SERVICES, Malaysia, TAN SRI DATUK (DR.) ABDUL MAJID ISMAIL, F.R.C.S. (E); M. Ch. (ORTH.); F.R.A.C.S. for his kind permission to publish this article.

REFERENCES

- BOWLES, H.E. (1939), *J. Amer. med. Ass.* 113,588
- COLE, C.E.C. (1918), *Br. med. J.* 2,566
- CULLEN, T.S., and BRODEL, M. (1937), *Bull. Johns Hopkins Hosp.*, 61,295
- FLETCHER, H.S., and JOSEPH, L.W., (1973), *International Surgery* 58,97

- JONES, T.W., and MERENDINO, K.A., (1962),
Am. J. Surg., 103,159
- LUCAS, W.E., and BAKER, W.S., (1958), Am.
J. Obstet. Gynec., 76,1302
- MARTIN, J.D., and THOMPSON, E.B., (1957),
Amer. Surg. 23,309
- NICHOLSON, N.J., (1956), Br. med. J., 1,1150
- PAYNE, R.L., (1938), Am. Surg., 108,757
- SCHAFFER, C.S., (1953), Am. J. Surg., 86,157
- SHEEHAN, V., (1951), Br. med. J., 2,1131
- STILES, Q.R., RASKOWSKI, H.J., and HENRY,
W., (1965), Surgery Gynec. Obstet., 121,331
- TORPIN, R., (1943), Am. J. Obstet. Gynec.,
46,553